

# Multidisciplinary Treatment for Thoracic and Abdominopelvic Endometriosis

Camran Nezhat, MD, Jillian Main, MD, Chandhana Paka, MD, Azadeh Nezhat, MD, Ramin E. Beygui, MD

## ABSTRACT

**Background and Objectives:** Thoracic endometriosis is a rare form of extragenital endometriosis with important clinical ramifications. Up to 80% of women with thoracic endometriosis have concomitant abdominopelvic endometriosis, yet the surgical treatment is usually performed with separate procedures. This is the largest published series of the combination of video-assisted thoracoscopic surgery and traditional laparoscopy for the treatment of abdominopelvic and thoracic endometriosis. The objectives of this series are to further evaluate the manifestations of thoracic endometriosis, assess the multidisciplinary surgical approach, and discuss our institution's protocols.

**Methods:** This is a retrospective, institutional review board-approved case series of 25 consecutive women who underwent combined video-assisted thoracoscopic surgery and traditional laparoscopy for the treatment of abdominopelvic, diaphragmatic, and thoracic endometriosis from January 1, 2008, to September 30, 2013. All surgeries were performed at a tertiary referral center by the same primary surgeons. Data were collected by chart review.

**Results:** Twenty-five patients were included, with a mean age of 37.7 years. Eighty percent of patients had catamenial chest pain, and in 40% this was their only chest complaint. Shoulder pain was noted in 40% of patients, catamenial pneumothorax in 24%, and hemoptysis in 12%. One hundred percent of patients were found to have endometriosis in the pelvis, 100% in the diaphragm, 64% in the chest wall, and 40% in the parenchyma. There were

2 major postoperative complications: 1 diaphragmatic hernia and 1 vaginal cuff hematoma.

**Conclusion:** Clinical suspicion and preoperative assessment are crucial in the diagnosis of thoracic endometriosis and allow for a multidisciplinary approach. The combination of video-assisted thoracoscopic surgery and traditional laparoscopy for the treatment of endometriosis optimally addresses the pelvis, diaphragm, and thoracic cavity in a single operation.

**Key Words:** Endometriosis, Thoracoscopy, Laparoscopy, TES(Thoracic endometriosis syndrome).

## INTRODUCTION

Endometriosis is a common disorder affecting an estimated 11% of the population.<sup>1,2</sup> The true prevalence is difficult to ascertain because women have varying degrees of symptoms and surgical biopsy is required for definitive diagnosis. Ectopic endometriosis is most commonly found in the pelvic region, resulting in dysmenorrhea, dyspareunia, dysuria, and dyschezia. It is estimated, however, that up to 12% of women will have extragenital ectopic endometriosis.<sup>3</sup> These sites include the urinary tract, bowel, perineum, umbilicus, and thoracic cavity.<sup>4</sup> In 1938 Schwarz<sup>5</sup> was the first author to characterize endometriosis of the lung parenchyma, and in 1958 Maurer et al<sup>6</sup> described spontaneous pneumothorax associated with menstrual cycles. Though rare, thoracic endometriosis has been published in various case reports and series and has important clinical ramifications. The surgical treatment for pelvic and thoracic endometriosis is often performed via separate procedures, requiring two episodes of preoperative preparation, general anesthesia, hospital time, and postoperative care. This could translate to increased risk for the patient, increased cost to the health care system, and decreased patient satisfaction. In 2009 we published the first reported small case series undergoing a combination of video-assisted thoracoscopic surgery (VATS) and traditional laparoscopy; this series showed that it is a safe and reasonable surgical option.<sup>7</sup> The current series is a larger follow-up study and allows further definition of

Center for Special Minimally Invasive and Robotic Surgery, Stanford University Medical Center, Palo Alto, CA, USA (Drs. C. Nezhat, Main, Paka, A. Nezhat).

Department of Cardiothoracic Surgery, Stanford University Medical Center and Clinics, Palo Alto, CA, USA (Dr. Beygui).

Address correspondence to: Camran Nezhat, MD, Center for Minimally Invasive and Robotic Surgery, Stanford University Medical Center, 900 Welch Rd, Ste 403, Palo Alto, CA 94304, USA. Telephone: (650) 327-8778, Fax: (650) 327-2794, E-mail: cnezhat@stanford.edu

DOI: 10.4293/JSLS.2014.00312

© 2014 by JSLS, Journal of the Society of Laparoendoscopic Surgeons. Published by the Society of Laparoendoscopic Surgeons, Inc.

the clinical manifestations of thoracic endometriosis and evaluation of the multidisciplinary treatment of combined VATS and traditional laparoscopy to address abdominopelvic and thoracic endometriosis in a single operation.

## METHODS

This is a retrospective cohort analysis of 25 consecutive cases of combined VATS and traditional laparoscopy performed at one institution from January 1, 2008, to September 30, 2013. Institutional review board approval was obtained. All patients in whom there was a high clinical suspicion of both abdominopelvic and thoracic endometriosis were included. No patients were excluded.

Our institution protocol is as follows. Patients initially present to our specialized center for endometriosis with symptoms of abdominopelvic or thoracic endometriosis. During the evaluation, a detailed history is obtained to determine whether catamenial chest pain, pneumothorax, hemoptysis, or radiating shoulder pain is present. If these symptoms are present, patients are referred to our institution's thoracic endometriosis specialist for further evaluation. Chest imaging via chest radiography, computed tomography, or magnetic resonance imaging is not routinely used. After evaluation by the thoracic surgeon, the gynecologic and thoracic teams create a treatment plan. If the patient is considered at high risk for both thoracic and abdominopelvic endometriosis and is not a candidate for hormonal therapy because of previous failure, intolerance, or desire for childbearing, her consent is obtained to undergo a multidisciplinary procedure combining VATS and traditional laparoscopy.

For all surgical cases, a double-lumen endotracheal tube is used for single-lung ventilation during the VATS procedure. A bronchial blocker is used to isolate the lung when the double-lumen endotracheal tube cannot be inserted. If the VATS procedure is performed first, the patient is placed in either the left or right decubitus position, depending on the laterality of suspected thoracic endometriosis. Gel padding and a deflatable beanbag are used to ensure safe and proper positioning. A trocar is inserted through a midaxillary incision. The camera is then placed into the thoracic cavity, and the cavity is explored. Additional ports are placed posteriorly and anteriorly as needed for visualization and creation of the desired operative angle. If there is evidence of endometriosis, it is treated via ablation, excision, or resection. Smaller lesions are ablated or excised with a carbon dioxide (CO<sub>2</sub>) laser or plasma jet energy. Deep parenchymal nodules are treated with pulmonary wedge resection using a stapling

device. Deep diaphragm lesions are treated with a diaphragm resection, either via an endoscopic stapling device or by excision and manual suturing. The phrenic nerve, pericardium, and superior vena cava are clearly identified and avoided. A Silastic flexible drain is then placed in the pleural space to release the pneumothorax and is attached to a water seal. The incisions are closed in layers, and the chest tube is secured to the skin using silk suture. If the opposite chest cavity is to be examined as well, the patient is repositioned, with repeat skin preparation and draping, and the procedure is repeated on the opposite side. The chest tube is left in place until postoperative day 1 or 2, once the patient has recovered from the iatrogenic pneumothorax and there is minimal drainage from the pleural space.

Once the VATS is completed, attention is turned to the abdomen for traditional laparoscopy. The patient is undraped and repositioned on a beanbag in the dorsal lithotomy position with the arms adducted. Care is taken to ensure that there are no pressure points, especially at the shoulders. The abdomen is entered using a closed-entry technique with a Veress needle and concurrent CO<sub>2</sub> gas insufflation.<sup>8</sup> In patients with prior abdominal surgery, a 20-gauge spinal needle attached to a syringe half filled with normal saline solution is inserted next to the Veress needle for "mapping."<sup>9</sup> The plunger is drawn back, and if CO<sub>2</sub> gas from the pneumoperitoneum easily appears in the syringe, intraperitoneal insufflation is likely, with minimal surrounding adhesions. This is repeated in a full range of directions anticipated for trocar entry. After establishment of pneumoperitoneum, a 10-mm camera port is placed at the umbilicus. Thereafter additional ports are placed in the right and left lower quadrants and suprapubically under laparoscopic visualization.

Initially, the pelvis and diaphragm are explored with the patient in the steep Trendelenburg position to assess the extent of intra-abdominal disease and identify abnormalities or distortions. The patient is then placed in the steep reverse Trendelenburg position to evaluate the upper abdominal walls, liver, and diaphragm for the presence of endometriosis. The liver is pushed caudally with an atraumatic grasper or liver retractor to view the adjacent diaphragm. A surgical plan is constructed to optimally restore normal anatomy and excise all areas of endometriosis. The abdominopelvic and visceral diaphragmatic endometriosis is treated via hydrodissection followed by excision or ablation with cold scissors, monopolar current, bipolar current, CO<sub>2</sub> laser, or plasma energy.<sup>10</sup> On completion, hemostasis is ascertained, the instruments are removed under visualization, and the incisions are closed.

**Table 1.**  
Patient Information

Patient Information	n (%)
Stage of pelvic endometriosis	
I	2 (8)
II	1 (4)
III	3 (12)
IV	19 (76)
Previous surgery for endometriosis	20 (80)
Laparoscopy	16
Laparotomy	4
Chest symptoms	25 (100)
Catamenial chest pain/pleurisy	20 (80)
Shoulder pain	10 (40)
Catamenial pneumothorax	6 (24)
Hemoptysis	3 (12)

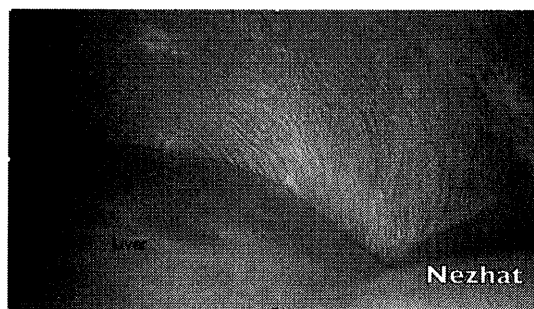**RESULTS**

The dataset includes 25 patients with symptoms of thoracic and pelvic endometriosis treated from January 1, 2008, to September 30, 2013. The mean age at the time of surgical intervention was 37.7 years (range, 25–60 years). Of the patients, 20 (80%) had undergone previous surgery for the treatment of endometriosis (**Table 1**). For those who underwent previous surgery for endometriosis, the mean time between the initial surgical diagnosis and combined surgical treatment was 10 years. Prior hormonal management had been used in 18 patients (72%). Twenty-three patients (92%) had complaints of dysmenorrhea and/or dyspareunia, whereas the remainder had either chronic pelvic pain or infertility (or both). With regard to thoracic endometriosis symptoms, 80% of patients had catamenial chest pain, and in 40% this was their only chest complaint. Shoulder pain was noted in 40% of patients, catamenial pneumothorax in 24%, and hemoptysis in 12% (**Table 1**). There were no patients who presented with only chest complaints in the absence of pelvic complaints.

In 89% of cases, VATS was performed before traditional laparoscopy. The right pleural cavity was examined in 17 cases, the left pleural cavity in 5 cases, and the bilateral pleural cavities in 3 cases, depending on the laterality of patient symptoms (**Table 2**). Diaphragm involvement was noted in all 25 patients. Involvement of both the pleural and visceral aspects of the diaphragm was present in 19 patients (76%), only the pleural diaphragm was involved in 2 cases, and only the visceral diaphragm was involved

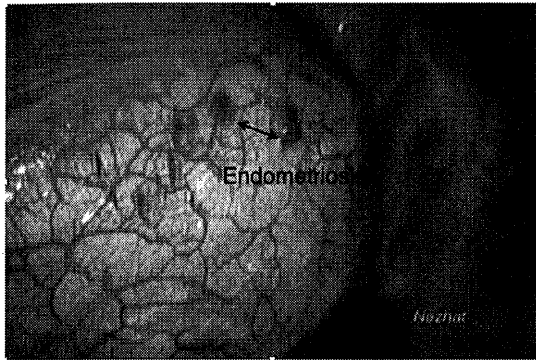
**Table 2.**  
Thoracic Endometriosis Findings

VATS Procedure Findings	n (%)
Laterality of symptoms/VATS	
Right sided only	17 (68)
Left sided only	5 (20)
Bilateral	3 (12)
Location of endometriosis	
Diaphragm	25 (100)
Visceral only	2 (8)
Thoracic only	4 (16)
Visceral and thoracic	19 (76)
Chest wall	16 (64)
Parenchyma	10 (40)
Type of VATS procedure	
Ablation	18 (72)
Diaphragm resection	2 (8)
Parenchymal wedge resection	5 (20)



**Figure 1.** Evidence of endometriosis on abdominal aspect of diaphragm.

in 4 cases (**Figures 1 and 2**). The chest wall was involved in 16 cases (64%) and the lung parenchyma in 10 cases (40%) (**Table 2**). There was 1 case of bilateral lung and diaphragm endometriosis. A diaphragm resection was performed in 2 cases, and wedge resection of the lung parenchyma was performed in 5 cases. During traditional laparoscopy, fertility-sparing treatment of endometriosis was performed in 21 cases, a hysterectomy in 4 cases, and a bowel resection in 1 case. The pathology reports for all of the abdominopelvic tissue samples were consistent with endometriosis. The stage of endometriosis for each patient is shown in **Table 1**. The 2 diaphragm pathology specimens showed endometriosis. In 1 patient the lung parenchyma wedge resections showed endometriosis in



**Figure 2.** Evidence of endometriosis on pleural aspect of diaphragm.

all specimens. In 2 patients the pathologic analysis showed hemorrhage and fibrosis. In 1 patient the pathologic analysis showed bronchiolitis but the diaphragm specimen showed endometriosis. In the final parenchymal resection patient, who was noted to have stage IV endometriosis, the parenchymal pathologic analysis showed a granulomatous fungal reaction.

There were 2 patients with major postoperative complications. The patient who had bilateral chest wall, diaphragm, and parenchymal involvement had a thoracic complication. Shortness of breath developed in this patient on postoperative day 2, and a computed tomography scan showed a defect in the left hemidiaphragm. She was taken back to the operating room for repair of the diaphragm defect via a thoracotomy. She had an uneventful recovery and was discharged home on postoperative day 6. There was 1 major pelvic complication occurring after a hysterectomy. On postoperative day 14, vaginal bleeding developed that required repeat traditional laparoscopy with a blood transfusion in this patient. There was no active source of acute bleeding; there was only generalized oozing from all operative sites. During her hospital observation, the hematocrit level continued to decrease, requiring a repeat blood transfusion and a repeat laparoscopy to remove a vaginal cuff hematoma and obtain hemostasis. The findings of a hematology consultation showed no blood dyscrasia, and the coagulopathy was attributed to overuse of over-the-counter nonsteroidal anti-inflammatory drugs and possible cuff cellulitis, for which the patient was treated.

The clinical follow-up period ranged between 3 and 18 months. Overall, all 25 patients noted significant improvement or resolution of their chest complaints. However, before 6 months, many noted occasional chest complaints or pain from the thoracostomy site. In two cases the chest

complaints returned, one at 9 months and the other at 12 months.

## DISCUSSION

As noted earlier, the incidence of pelvic endometriosis is approximately 11%, with an estimated 12% of these patients having extragenital endometriosis.<sup>1-3</sup> Thoracic endometriosis is a rare form of extragenital endometriosis and has been shown to occur simultaneously with pelvic endometriosis in approximately 50% to 80% of the cases.<sup>11,12</sup> When patients present with both pelvic and thoracic symptoms and are surgical candidates for both procedures, this series suggests that the procedures should be performed concomitantly.

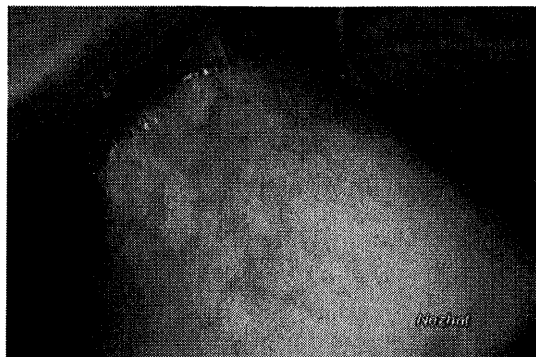
Numerous theories have examined and detailed the development of thoracic endometriosis, but the exact pathophysiology remains unclear. The theory of retrograde menstruation, first described centuries ago and further delineated by Sampson,<sup>13</sup> is the most supported theory for the dissemination of endometrial cells into the peritoneal cavity.<sup>14</sup> It is proposed that the endometrial cells that enter the peritoneal cavity can enter the pleural space through lymphatic channels, through diaphragmatic fenestrations, or hematogenously. The propensity for the right diaphragm to be affected more often than the left diaphragm supports this theory because of the directional flow of peritoneal fluid from the pelvis to the right paracolic gutter. A hormonal model suggests a theory for hemothorax in which a high prostaglandin F<sub>2</sub> level at ovulation results in vasospasm and ischemia in the lungs.<sup>15</sup> Finally, an anatomic model suggests a theory for pneumothorax in which air enters the thorax via the pelvis after loss of the cervical mucous plug during menses.<sup>16</sup> However, the precise mechanism has yet to be determined.

Thoracic endometriosis was thought to be a rare manifestation of extragenital endometriosis, but we are now seeing an increase in diagnosis, likely because of an increased awareness of the condition.<sup>17</sup> It is notable, however, that the mean age at diagnosis of thoracic endometriosis is well above the mean age at diagnosis of pelvic endometriosis. In our series the mean age at diagnosis of thoracic endometriosis is 37.7 years, with a mean time lapse of 10 years from the initial diagnosis of pelvic endometriosis to the diagnosis of thoracic endometriosis. This is similar to the findings of Joseph and Sahn,<sup>11</sup> who examined 110 patients with thoracic endometriosis and found that the mean age at diagnosis was 35 years. This finding could indicate that the thoracic component takes longer to develop or that thoracic endometriosis

is being underdiagnosed because of a lack of detailed history taking during the initial consultation.

Thoracic endometriosis can be detected in the diaphragm, chest wall, pleura, and parenchyma. The thoracic diaphragm and visceral diaphragm are the most commonly described sites of lesions (38.8% and 29.6%, respectively), with the parenchyma less commonly reported.<sup>4,17</sup> In our series we found that 76% of patients had both thoracic and visceral diaphragm involvement, with a small proportion of the patients having solely a thoracic or visceral component. This finding favors the notion that both sides of the diaphragm need to be evaluated if one side is noted to have endometrial implants. In our series there was a higher incidence of parenchymal involvement (40%) than previously reported.<sup>11</sup> The vast majority of these parenchymal lesions can be ablated, without the need for resection. In this series, 4 of the 5 cases of wedge resection had visual signs of endometriosis and pathology suggestive of or definitive for endometriosis. Endometriosis has been shown to preferentially affect the right thorax, which was confirmed in our study: 68% of patients underwent right-sided VATS because of symptoms on the right side.<sup>18</sup> Bilateral thoracic endometriosis has been shown to be exceedingly rare, but we had 1 case of bilateral lung and diaphragm endometriosis, which was recently reported as a case report.<sup>19</sup>

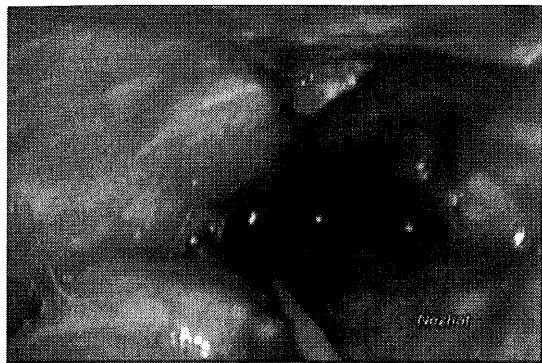The diagnosis of thoracic endometriosis depends heavily on clinical suspicion. Previous studies reported concurrent pelvic endometriosis in approximately 50% to 80% of cases,<sup>11,12</sup> but the rate was found to be 100% in this population. Therefore patients with symptoms consistent with pelvic endometriosis who have chest complaints should undergo an evaluation for both thoracic and pelvic endometriosis. There are 4 clinical signs of thoracic endometriosis: catamenial pneumothorax, catamenial hemothorax, catamenial hemoptysis, and lung nodules.<sup>18</sup> Catamenial pneumothorax is defined as 2 episodes of pneumothorax temporally related to the onset of menses, usually within 72 hours. The most common symptoms associated with catamenial pneumothorax are shortness of breath, cough, and pleurisy. Initial retrospective case series reported that catamenial pneumothorax was a rare event; however, more recent publications challenge this notion.<sup>20</sup> There are several recent reviews that have quoted that as many as 30% of women referred for surgical treatment of spontaneous pneumothorax have thoracic endometriosis.<sup>17,21</sup> In our series we distinguished between catamenial chest pain/pleurisy and documented pneumothorax. By separating these complaints, we noted that 80% of our patients had complaints of catamenial



**Figure 3.** Adhesion of lung parenchyma to chest wall due to endometriosis.

chest pain, with 40% having only that symptom. Pneumothorax was noted as the third most common symptom, at a rate of 24%, which is in contrast to prior studies showing pneumothorax as the most common symptom.<sup>18</sup> This series shows that using a lower threshold of symptoms to make the clinical diagnosis of thoracic endometriosis, such as catamenial chest pain or shoulder pain and not recurrent pneumothorax, does not decrease the specificity of diagnosis. The role of chest imaging in the diagnosis and surgical planning of thoracic endometriosis remains unclear. Chest radiographs or computed tomography scans may show small cystic defects or may yield negative findings and be of little utility.<sup>12,22</sup> The suspicion for thoracic endometriosis is primarily based on the patient's history, which is sufficiently sensitive to recommend surgical intervention.

Surgery via a minimally invasive technique is the gold standard for the diagnosis of thoracic endometriosis.<sup>4</sup> The use of VATS allows for the direct visualization of implants and nodules and the ability to resect or desiccate apical blebs, parenchymal implants, or diaphragmatic implants (**Figures 3 and 4**). Large lesions or deep parenchymal endometrial nodules are best treated with parenchyma-sparing procedures such as wedge resection or segmentectomy. Only occasionally, a lobectomy required.<sup>23,24</sup> Exploratory thoracotomy, previously used as the standard for diagnosis and treatment of chest endometriosis, is now reserved for failure of minimally invasive techniques. The treatment of abdominal diaphragmatic endometriosis via traditional laparoscopy was first described by Nezhat et al<sup>10</sup> in 1992. Superficial diaphragmatic endometriosis can be treated with cold scissors, monopolar energy, bipolar energy, a CO<sub>2</sub> laser, or a plasma energy source.<sup>25</sup> Larger implants or small perforations are best treated by resection and reanastomosis with an endoscopic stapler device or



**Figure 4.** Extensive evidence of destruction of anatomy involving chest wall and parenchyma of lung.

suturing at the defect. Larger diaphragmatic perforations can be sutured, but the recurrence rate has been significant. If larger visceral diaphragm implants or defects are present, they may be approached via VATS because the liver bulk and limited subdiaphragmatic space may not allow complete resection. Our cohort shows that 76% of patients had involvement of both the diaphragmatic and pleural surface of the diaphragm, so it is important to evaluate both cavities if endometriosis is found on either side of the diaphragm.

Despite growing awareness of thoracic endometriosis, it remains an enigmatic condition. It is a complicated entity with varying clinical presentations and an unclear pathogenesis. Because most patients have both pelvic and thoracic symptoms—as was found in 100% of the patients in this series—it is important to assess and treat all areas of disease. A multidisciplinary approach of combined VATS and traditional laparoscopy optimally addresses pelvic, diaphragmatic, and thoracic endometriosis in a single operation. This case series is the largest such case series, to our knowledge, and illustrates the complexity of the disease and the benefit of a multidisciplinary approach. It is a testament to the need for further investigation to understand endometriosis in general, as well as the use of combined treatment modalities in cases of concomitant extragenital endometriosis.

#### References:

1. Buck Louis G, Hediger ML, Peterson CM, et al. Incidence of endometriosis by study population and diagnostic method: the ENDO study. *Fertil Steril*. 2011;96(2):360–365.
2. Leibson CL, Good AE, Hass SL, et al. Incidence and characterization of diagnosed endometriosis in a geographically defined population. *Fertil Steril*. 2004;82(2):314–321.

3. Franklin RR, Grannert GM. Extragenital Endometriosis. In Nezhat CR ed. *Endometriosis advanced management and surgical techniques*. New York: Springer. 1995. p. 127–136.
4. Veeraswamy A, Lewis M, Mann A, Kotikela S, Hajhosseini B, Nezhat C. Extragenital endometriosis. *Clin Obstet Gynecol*. 2010; 53:449–466.
5. Schwarz O. Endometriosis of the lung. *Am J Obstet Gynecol*. 1938;36:887–889.
6. Maurer ER, Schaal JA, Mendez FL Jr. Chronic recurring spontaneous pneumothorax due to endometriosis of the diaphragm. *J Am Med Assoc*. 1958;168:2013–2014.
7. Nezhat C, Nicoll LM, Bhagan L, et al. Endometriosis of the diaphragm: four cases treated with a combination of laparoscopy and thoracoscopy. *J Minim Invasive Gynecol*. 2009;16:573–580.
8. Vilos GA, Vilos AG. Safe laparoscopic entry guided by Veress needle CO<sub>2</sub> insufflation pressure. *J Am Assoc Gynecol Laparosc*. 2003;10(3):415–420.
9. Nezhat C, Nezhat F, Nezhat C. *Nezhat's Operative Gynecologic Laparoscopy and Hysteroscopy*. 3rd ed. Cambridge, England: Cambridge University Press; 2008.
10. Nezhat F, Nezhat C, Levy JS. Laparoscopic treatment of symptomatic diaphragmatic endometriosis: a case report. *Fertil Steril*. 1992;58:614–616.
11. Joseph J, Sahn SA. Thoracic endometriosis syndrome: new observations from an analysis of 110 cases. *Am J Med*. 1996;100: 164–170.
12. Honoré G. Extrapelvic endometriosis. *Clin Obstet Gynecol*. 1999;42:699–711.
13. Sampson JA. Metastatic or embolic endometriosis, due to the menstrual dissemination of endometrial tissue into the venous circulation. *Am J Pathol*. 1927;3:93–110.43.
14. Nezhat C, Nezhat Y, Nezhat C. Endometriosis: ancient disease, ancient treatments. *Fertil Steril*. 2012;98(6 suppl):51–62.
15. Rossi NP, Goplerud CP. Recurrent catamenial pneumothorax. *Arch Surg*. 1974;109:173–176.
16. Cowl CT, Dunn WF, Deschamps C. Visualization of diaphragmatic fenestration associated with catamenial pneumothorax. *Ann Thorac Surg*. 1999;68:1413–1414.
17. Rousset-Jablonski C, Alifano M, Plu-Bureau G, et al. Catamenial pneumothorax and endometriosis-related pneumothorax: clinical features and risk factors. *Hum Reprod*. 2011;26: 2322–2329.
18. Channabasavaiah AD, Joseph JV. Thoracic endometriosis: revisiting the association between clinical presentation and thoracic pathology based on thoracoscopic findings in 110 patients. *Medicine (Baltimore)*. 2010;89(3):183–186.

19. Nezhat C, King LP, Paka C, Odegaard J, Beygui R. Bilateral thoracic endometriosis affecting the lung and diaphragm. *JSLs*. 2012;16:140–142.
20. Nakamura H, Konishiike J, Sugamura A, Takeno Y. Epidemiology of spontaneous pneumothorax in women. *Chest*. 1986; 89:378–382.
21. Alifano M, Roth T, Broet SC, Schussler O, Magdeleinat P, Regnard JF. Catamenial pneumothorax: a prospective study. *Chest*. 2003;124:1004–1008.
22. Redwine DB. Diaphragmatic endometriosis: diagnosis, surgical management, and long-term results of treatment. *Fertil Steril*. 2002;77:288–296.
23. Terada Y, Chen F, Shoji T, Itoh H, Wada H, Hitomi S. A case of endobronchial endometriosis treated by subsegmentectomy. *Chest*. 1999;115:1475–1478.
24. Kristianen K, Fjeld NB. Pulmonary endometriosis causing haemoptysis. Report of a case treated with lobectomy. *Scand J Thorac Cardiovasc Surg*. 1993;27:113–115.
25. Nezhat C, Seidman DS, Nezhat F. Laparoscopic surgical management of diaphragmatic endometriosis. *Fertil Steril*. 1998; 69:1048–1055.