

Uterine Closure with the Endo Stitch 10-mm Laparoscopic Suturing Device—A Review of 50 Laparoscopic Myomectomies

Nelson H. Stringer, M.D., FACOG*†

Marvin A. McMillen, M.D., FACS‡

Robin L. Jones, M.D.*

Azeadeh Nezhat, M.D.*

Esther Park, M.D.*

*The Department of Obstetrics and Gynecology
Columbia Michael Reese Medical Center
Chicago, Illinois

†The Department of Obstetrics and Gynecology
Rush Medical College
Rush Presbyterian St. Luke's Medical Center
Chicago, Illinois

‡The Department of Surgery
University of Illinois College of Medicine
Columbia Michael Reese Medical Center
Chicago, Illinois

ABSTRACT: **Objective**—To evaluate the mechanical performance of the Endo Stitch Laparoscopic Suturing Device and the clinical effectiveness of both a running, locked suture technique and a new modified suture technique for closure of uterine defects after laparoscopic removal of myomas. **Study Subjects**—Fifty consecutive patients with symptomatic uterine leiomyomata. **Observational Method**—Retrospective chart review. **Main Findings**—The endometrial cavity was entered and sutured laparoscopically, in two layers, in 22 patients. In 28 patients, only the myometrium was sutured. A two-layered closure of the endometrium and myometrium was completed in an average time of 10 minutes. Mechanical problems with the Endo Stitch occurred in 11 cases. In all patients with second-look laparoscopies, the fallopian tubes were patent bilaterally without adhesions. No uterine fistulas were present in any patients with second-look laparoscopies. Posterior myomas were removed and sutured without adhesion formation. Grade 3 adhesions, to the uterine surface, were associated with transverse incisions of the uterus and over-treatment with GnRH analogs. **Conclusions**—The Endo Stitch Laparoscopic Suturing Device in combination with a running, locked suture technique achieves a rapid, hemostatic, clinically secure closure of the endometrium and myometrium. The Endo Stitch and our modified suture technique were not associated with adhesions or blockage of the fallopian tubes or uterine fistulas following laparoscopic myomectomies. The initial mechanical problems with the Endo Stitch were resolved. In our experience, currently the Endo Stitch is the best instrument for laparoscopic suture closure of uterine defects. *Int J Fertil* 42(5):288-296, 1997

KEY WORDS: laparoscopic myomectomy, laparoscopic suturing, Endo Stitch laparoscopic suturing, laparoscopic uterine closure

INTRODUCTION

LAPAROSCOPIC UTERINE CLOSURE WITH the Endo Stitch 10-mm Laparoscopic Suturing Device (Auto Suture Company, Division of U.S. Surgical Corp., Norwalk, CT) and a description of the running, locked, suture technique, developed by one of us (NHS), were first reported in 1996 [1]. A laparoscopic myomectomy requires an experienced laparoscopic surgeon with total mastery of endoscopic suturing, since it is often necessary to suture the defect created by removing the myoma [2-8].

The suturing technique described in the initial report has been refined and revised for use in closure of the endometrium and large vertical defects. The Endo Stitch Laparoscopic Suturing Device now provides the mechanical efficiency that allows multiple-layer closures of deep uterine defects and the endometrium via laparoscopy. Adequacy of the closure and adhesion and fistula formation have been the main concerns associated with laparoscopic repair of the uterus [9]. This is a report of 50 consecutive uterine closures performed with the Endo Stitch Laparoscopic Suturing Device. A complete schematic description of the revised laparoscopic suturing technique is provided in this report. The revisions of the initial suture technique will allow the Endo Stitch to be used for laparoscopic suturing of all types and sizes of uterine defects. A review of the literature reveals this is the largest report of the use of the Endo Stitch for uterine closure via laparoscopy.

PATIENTS AND METHODS

A retrospective chart review was performed on 50 consecutive laparoscopic myomectomies performed between October 31, 1994 and December 20, 1996. The following information was collected and analyzed: age, gravidity, parity, weight, indications for surgery, history of previous myomectomies, clinical size of the uterus, ultrasound size of the uterus, months of GnRH treatment, predominant myoma type and size removed, size and location of uterine defects, entry into the endometrial cavity during procedure, blood loss, hematocrit, hemoglobin, transfusions, follow-up laparotomies, pregnancies after myomectomies, number of myomas removed during each procedure, surgical time, complica-

tions, mechanical problems occurring with the Endo Stitch, and tubal patency, adhesion and fistula formation in follow-up second-look laparoscopic evaluations. Informed consent was obtained from all patients. Patients were also specifically informed regarding the risks and benefits of laparoscopic suturing of uterine defects with the Endo Stitch, including the possibilities of adhesion and fistula formation, alteration of uterine tensile strength that could affect future pregnancies, and the possibility of mechanical problems with the Endo Stitch, which might require an open laparotomy.

Patients who desired future pregnancies were advised to have second-look laparoscopies for evaluation of tubal patency and adhesion and fistula formation. A modified protocol for GnRH treatment previously described in the literature was utilized with all patients [4]. Bowel preparation was performed on all patients the night before surgery with 1 gallon of Nulytely (Braintree Laboratories, Braintree, MA), as well as oral erythromycin and neomycin. Autologous blood donation was offered to all patients.

All procedures were performed by one or more of the authors, assisted by a resident physician with the patient under general endotracheal anesthesia. The laparoscopic dissection, morcellation of myomas, and closure of trocar sites were performed using techniques previously described in the literature [2,4,10]. In the first five cases in this study, the defects created by removal of myomas were sutured with the technique we initially described in the literature [1]. In the remaining 45 cases, the techniques described in Figures 1 and 2 were utilized for uterine closure. The initial technique was refined for: (1) suturing the endometrium when it was entered during removal of a myoma; (2) suturing deep uterine defects (>3 cm in depth), with vertical side walls, in two layers when the endometrium was not entered; and (3) easier creation of a running, locked suture. When a two-layered closure of the endometrium and myometrium was required, the technique described in Figure 1 was employed. Large defects in the myometrium, if the endometrium was not entered, were closed with the technique shown in Figure 2.

RESULTS

The indications for surgery were menometrorrhagia 38% (n = 19), chronic pelvic pain 34% (n = 17),

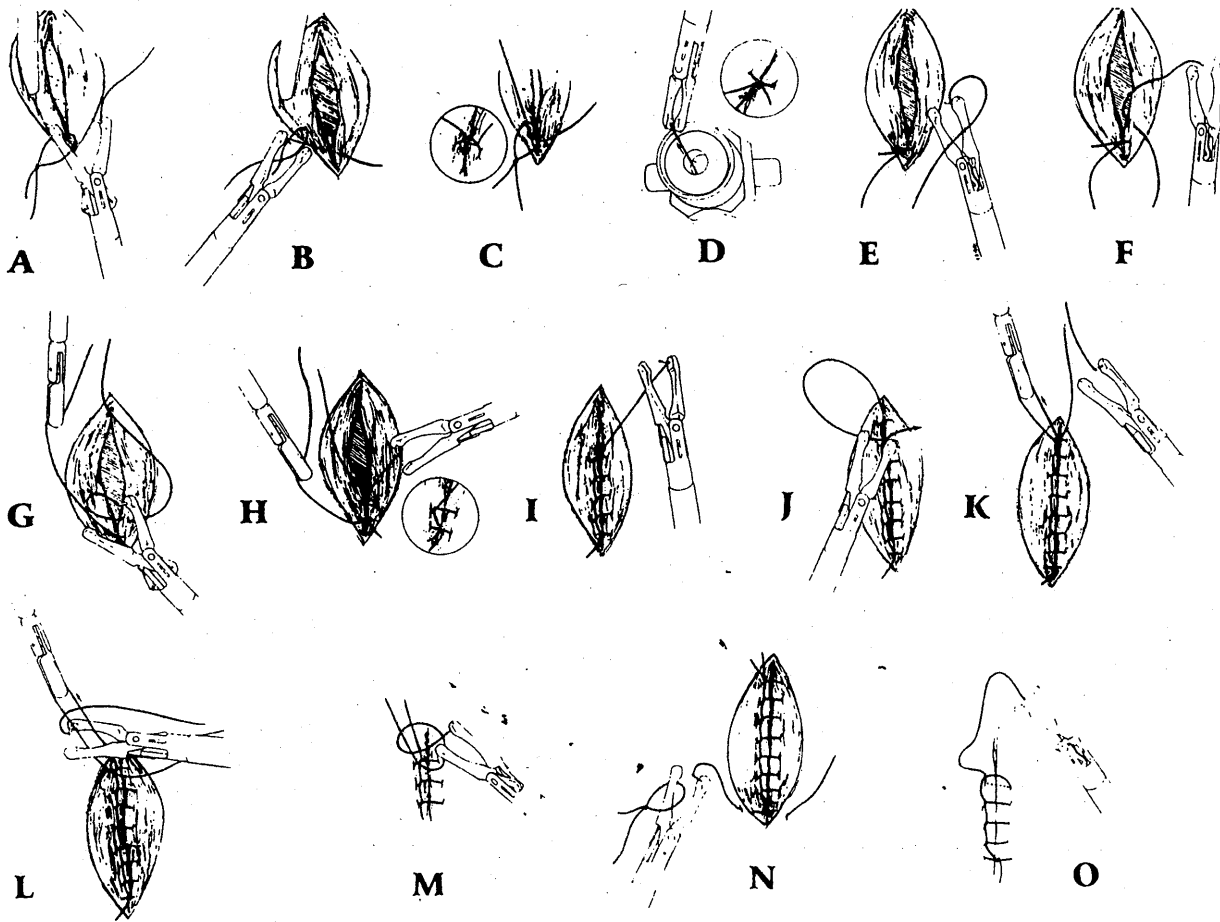


FIG. 1. Two-layered closure of the endometrium. Outside of the abdomen, a slip knot is placed over the left jaw of the Endo Stitch while the needle remains in the right jaw of the instrument. With the Endo Stitch closed in the neutral position, the needle and slip knot are passed through the right lateral Versaport 12-mm trocar and positioned at the apex of the endometrial incision (A). The needle is then passed through the right jaw of the Endo Stitch, through both edges of the endometrium. The switch of the toggle lever is used to pass the needle smoothly through the tissue. The suture is then pulled through the slip knot (B). This creates the anchor knot for the running suture (C). The Endo Stitch is then pulled out of the abdomen, through the Versaport trocar, to secure the knot (D). The trocar (Versaport 12-mm trocar, Auto Suture Company, Division of United States Surgical Corporation, Norwalk, CT) used with this suture procedure must have a universal valve that will not leak when the suture attached to the Endo Stitch is pulled out of the trocar to tighten knots during this step. Re-inserting the Endo Stitch into the abdomen, with the needle in the right jaw (E), a continuous, running, locked suture of the endometrium is created by toggling the needle through one side of the endometrium (F) and then through the other side of the endometrium (G). To create a running locked suture, the surgical assistant should grasp and pull the suture loop away from the surgeon after it is passed through the tissue (H). The surgeon should then pull the needle and suture through the loop created by the assistant. This specific step should be repeated, thus creating a continuous, locked suture line (I). To create an intracorporeal knot at the end of the suture line (the first step), with the needle in the left jaw position, pass the needle under the suture line at the end of the incision and toggle the needle to the right jaw (J). This creates a loop of suture which should be grasped by the surgical assistant (K). The surgical assistant should grasp and pull this loop of suture vertically. With the needle in the right jaw, the loop of suture held by the assistant is placed between the jaws of the Endo Stitch (L). The needle is then toggled to the left jaw. Toggling the needle to the left jaw and pulling the needle and suture in opposite directions secures the first tie of the knot (M). The knot is tightened by the surgical assistant pulling in one direction and the surgeon pulling in the opposite direction. Steps L and M should be repeated to create the second tie of the knot. When the first layer is completed, the Endo Stitch with the pre-tied slip knot is again used to place an anchor knot to start the closure of the second layer (N). The same procedure described above is used to close the second layer with a continuous, running, locked suture (O). The knot at the end of the suture line is again tied as described in steps J-M.

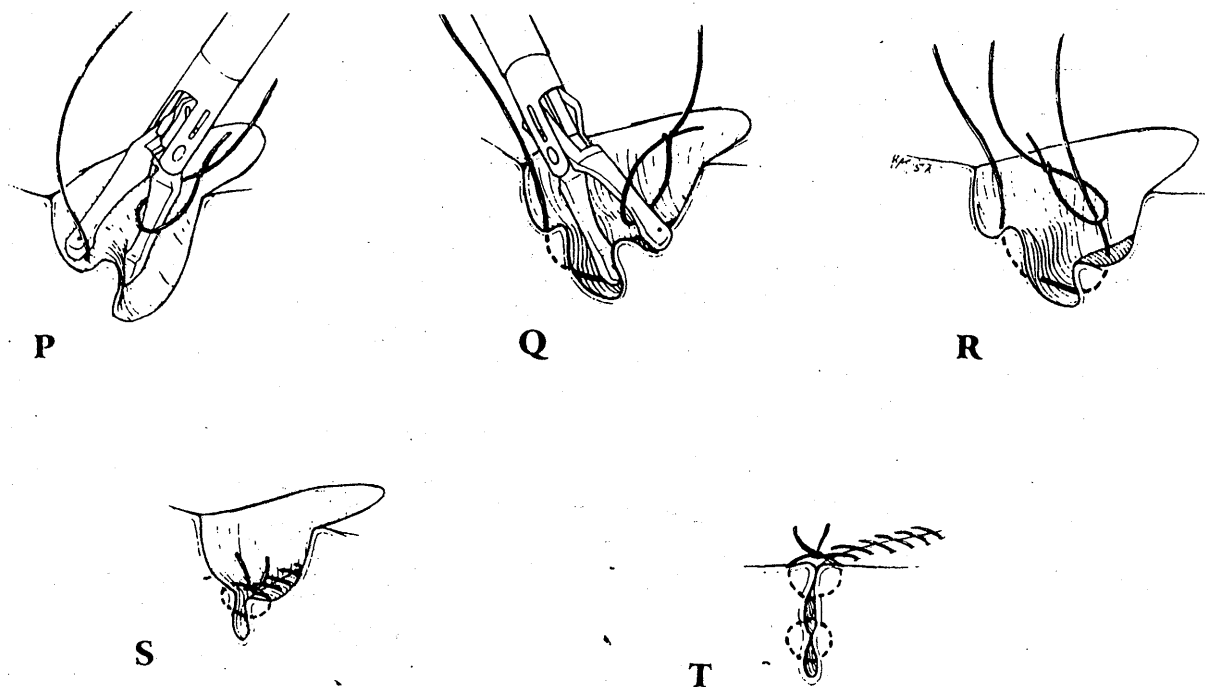


FIG. 2. Two-layered closure of large myometrial defects. Outside of the abdomen, a slip knot is placed over the left jaw of the Endo Stitch while the needle remains in the right jaw of the instrument. With the Endo Stitch closed in the neutral position, the needle and slip knot are passed through the right lateral Versaport 12-mm trocar and positioned at the apex of the myometrial incision (**P**). Approximately 1 cm of tissue should be grasped by pressing the Endo Stitch firmly into the myometrium (**P**). The same procedure is repeated on the opposite side of the defect (**Q**). The suture is then pulled through the other side of the defect (**R**) and the anchor knot tied by pulling the Endo Stitch out through the trocar. The steps described in Figure 1, Steps G–I are then repeated along the length of the incision by firmly grasping the walls of the myometrium. The suture is also managed as described in Figure 1, Steps G–I. This technique creates a closure of the uterus that eliminates any dead space (**S**). The knot at the end of this first suture line is created as described in Figure 1, Steps J–M. The procedure described in Figure 1, Steps N and O for closure of the second layer should again be used to produce a two-layered closure (**T**). The intracorporeal knot for this layer is tied using the technique described in Figure 1, Steps J–M.

and increasing uterine size 28% ($n = 14$). One patient was transfused (one unit of packed cells) when she experienced postoperative vaginal bleeding which reduced her hemoglobin count to 8.8 the next day after surgery. The largest myoma in each uterus was designated as the predominate myoma type [2,11]. The size and type of the predominate myoma is directly related to the extent of laparoscopic suturing required [2]. The distribution of predominant myoma types was: 50% subserosal, 46% intramural, and 4% pedunculated. GnRH pretreatment was managed according to a protocol based upon the size of the largest myoma by ultrasound, and the clinical size of the uterus [4]. Three months of GnRH pretreatment was given to patients when the largest myoma by ultrasound was >7 cm or the clinical size >11 weeks. One or 2

months of pretreatment was given to patients with smaller myomas or smaller clinical sizes [4]. Leuprolide 3.75 mg (Lupron; TAP Pharmaceuticals, North Chicago, IL) or Goserelin 3.6 mg (Zoladex; Zeneca Pharmaceuticals, Wilmington, DE), was given by protocol to all the patients in this study. Thirty patients were pretreated with Zoladex for an average of 2.03 months, and 20 patients with Lupron for an average of 2.15 months.

A total number 193 myomas were removed from the 50 patients. The endometrial cavity was entered in 22 patients (Table I). The endometrial cavity was first entered and sutured in the sixth case in this study. Defects up to $4 \times 1 \times 3$ cm in the myometrium were closed in one layer in approximately six minutes. Suturing the endometrium and myometrium in two layers was comparable in sur-

TABLE I
Comparison of endometrial cavity entry vs. non-endometrial cavity entry when suturing with the Endo Stitch.

Uterine Incision Status	Number of Cases	Blood Loss (cc)	Surgical Time
Endometrial cavity not entered	28	79.81	218.62
Endometrial cavity entered	21*	139.75	249.85

*One case excluded, which was completed by open laparotomy.

The endometrial cavity was entered and sutured with the Endo Stitch in 21 laparoscopic myomectomies. On the average, when suturing the endometrium was required, the overall surgical time was 30 minutes longer and incurred 60 cc more blood loss.

gical time to suturing a large defect (>5 cm in depth) in the myometrium in two layers. A two-layered closure of the endometrium and myometrium was completed in an average time of 10 minutes. Defects in the myometrium measuring approximately 5 × 2 × 4 cm were sutured in two layers in 10 minutes. The maximum time required to close a 13-cm defect in the myometrium, in two layers, was 16 minutes.

One case in which the endometrium was sutured was excluded from the blood loss and surgical time averages. This patient, case number 20 (Table II), represents the only laparoscopic myomectomy ever performed by the authors which required conversion to an open laparotomy. After complete removal of all myomas and suturing of the endometrium and myometrium in two layers, one area of the suture line appeared to require one additional interrupted suture. While attempting to place this single interrupted suture through the relatively flat surface of the uterine serosa, the needle of the Endo Stitch broke in two pieces. One fragment attached to the right arm of the Endo Stitch and was easily removed. Unfortunately, the other fragment fell into the peritoneal cavity and was obscured by loops of small bowel before it could be grasped with an instrument. Because of the relatively small size of this fragment (approximately 4.5 mm), it could not be found laparoscopically, even with the assistance of fluoroscopy. An open laparotomy with fluoroscopy was required to locate and remove the needle fragment.

The Endo Stitch was used in 39 cases in this study without the occurrence of mechanical problems. The first mechanical problem with Endo Stitch occurred during the tenth case. In 11 patients, mechanical problems did occur with the Endo Stitch (Table II). Thirty-nine of the procedures in this study were performed on an out-patient basis. Excluding the one open laparotomy, which required a three-day hospital

TABLE II
Mechanical problems with Endo Stitch.

Case No.	Uterus Size (weeks)	Largest Defect (cm)	Endometrium Entered	Mechanical Complications
10	12	6 × 3 × 3	Yes	Toggle mechanism jammed
11	10	4 × 3 × 3	No	Toggle mechanism jammed
12	10	5 × 3 × 3	No	Toggle mechanism jammed
14	11	5 × 3 × 4	No	Toggle mechanism jammed
20	12	7 × 3 × 4	No	Needle broke, two fragments, open laparotomy required
21	12	13 × 5 × 4	Yes	Needle detached from arms and suture, removed laparoscopically
23	12	6 × 3 × 3	Yes	Needle bent, broke off intact from suture, removed laparoscopically
29	11	9 × 4 × 4	Yes	Needle broke in uterus, fragments removed laparoscopically
38	12	6 × 3 × 3	Yes	Needle detached from arms with suture attached, removed laparoscopically
39	12	5 × 4 × 4	Yes	Needle detached from arms with suture attached, removed laparoscopically
45	10	4 × 3 × 4	Yes	Needle detached from arms with suture attached, removed laparoscopically

TABLE III
Second-look laparoscopies for adhesion evaluation after suturing with the Endo Stitch.

Case No.	Adhesion Grade	Uterine Size (weeks)	Predominant Myoma Size	No. of Myomas	Endometrium Entered	Incision Type	Comments
43	0	10	Intra—4 cm	3	No	Vertical	3rd myomect.
13	0	11	Intra—8 cm	4	No	Vertical	
18	0	10	Subser—6 cm	4	No	Vertical	3rd myomect.
15	0	10	Subser—8 cm	3	No	Vertical	
16	0	13	Intra—10 cm	5	Yes	Vertical	3rd myomect.
45	1	10	Intra—4 cm	6	Yes	Vertical	
29	1	10	Intra—9 cm	4	Yes	Vertical	3rd myomect.
25	1	9	Subser—4 cm	3	No	Vertical	
28	2	12	Subser—10 cm	4	No	Vertical	3rd myomect.
17	3	14	Intra—11 cm	1	Yes	Transverse	
33	3	10	Intra—5 cm	3	Yes	Vertical	Lupron x6
21	3	12	Intra—10 cm	6	Yes	Transverse	

Intra = intramural myoma; Subser = subserosal myoma.

Grade 0, no adhesions; Grade 1, filmy, non-vascular; Grade 2, thick and vascular; Grade 3, thick, vascular and bowel.

stay, the average hospital stay of the remaining ten cases was 1.2 days. No intraoperative blood transfusions were required for any patients. No other short-term or long-term complications have occurred. To date, second-look laparoscopies have been performed on 11 patients in this study for evaluation of adhesions and uterine fistula formation (Table III). Fourteen patients in this study had previous tubal ligations. Sixteen patients were gravida 0, para 0. The average age of these patients was 37.5 years. To date, only one patient in this group has attempted pregnancy, at the age of 41 years. At the time of this writing, she was presently 26 weeks pregnant, without problems. Five patients in the study were gravida 2, para 2, elective abortion 2. The average age of the patients in this group was 38.8 years. Only one patient, age 32, desires additional pregnancies. She has not yet attempted pregnancy. Fifteen patients had an average gravidity of 2.26 pregnancies and an average parity of 1.5 pregnancies. Twelve of the patients in this group do not desire additional pregnancies. The remaining three patients have not yet attempted additional pregnancies.

Patients desiring future pregnancies were advised to have a second-look laparoscopy within 6 weeks of their laparoscopic myomectomy. None of the patients complied with this recommendation; all second-look laparoscopies were performed >6 weeks

after the laparoscopic myomectomy. Injection of methylene blue revealed bilaterally patent fallopian tubes, without adhesions, in all patients. No uterine fistulas were present in the six patients whose endometrium was entered and sutured. Cases 43 and 45 both had two previous myomectomies (one open, one laparoscopic). The largest amount of tissue, 380 g, was removed from case 15. One of the four myomas removed from Case 18 was located on the posterior surface of the uterus. In Case 28, 312 g of myoma tissue was removed from the uterine fundus. Case 13 had an 8-cm, posterior myoma removed through a vertical incision without adhesion formation. Case 33 was referred to the authors after 6 months of GnRH (Lupron) treatment by another medical center. Dissection at laparoscopy revealed a severely necrotic, caseated 5-cm fundal myoma which required laparoscopic suction for complete removal of all the "oatmeal"-like material. This patient had one Grade 3 adhesion, 1 cm in width, exactly on the fundal posterior surface of the uterus, where the uterus was sutured.

DISCUSSION

Laparoscopic myomectomy requires an experienced laparoscopic surgeon with total mastery of endo-

scopic suturing. Suturing and knot tying have traditionally been considered the most difficult skills required for operative laparoscopy [12]. One of the critical limiting factors for performing a laparoscopic myomectomy was the extreme difficulty, or even inability, of performing a continuous layered closure of the uterus after removing deep intramural myomas which enter the endometrial cavity. The mechanical efficiency of the Endo Stitch 10-mm Laparoscopic Suturing Device and the suturing technique described in this report now allow easy and secure multiple-layer closure of deep defects and the endometrial cavity via laparoscopy.

Uterine defects of all sizes and in all areas of the uterus were easily sutured in the cases presented in this report. Specifically, posterior and lateral defects were easily and securely sutured with the Endo Stitch. The Endo Stitch suturing technique as we initially described it did not utilize a surgical assistant to prevent tangling of the suture while creating the running, locked suture. If the proper loops of the suture are not placed on the correct side of the Endo Stitch, as shown in the Figure 1, G and H, only a continuous unlocked suture will be created. This revised technique of having the surgical assistant grasp the suture ensures that a continuous locked suture is easily created. The initial report of the technique also did not include closure of the endometrium, whereas our present report contains, we believe, the first published description of the deep closure technique that should be used when the endometrium is not entered. This revised deep closure technique uses a continuous, running, locked suture on all layers, rather than interrupted and running sutures as previously described [1]. In the cases where the endometrial cavity was entered and sutured with the Endo Stitch, the average blood loss of 139.75 cc was not significantly different from that reported in our previous laparoscopic myomectomies where suturing of the endometrium was not required [2]. Compared with extracorporeal and intracorporeal suturing and knot tying with traditional techniques [13], the Endo Stitch suturing and knot tying techniques are technically easier and less time consuming [1]. The knot produced with the Endo Stitch appears as secure as those we have produced with traditional laparoscopic techniques [2-4]. No fistulas occurred in any of the six patients whose endometrial cavities were sutured with the Endo Stitch and evaluated with second-look laparoscopies. Hysteroscopic evalua-

tions of these patients revealed no visible defects of the endometrium.

Uterine dehiscence during pregnancy is one of the major long-term concerns after performing laparoscopic myomectomy. The only absolute method of measuring the tensile strength of a repaired uterus is to expose it to the stresses of pregnancy and labor. Based upon our experience with pregnancies in a uterus with a traditional laparoscopic repair [3], the uterine suture line created with the Endo Stitch appears more secure to us. Before October 1994, we closed uterine defects with interrupted sutures using the Surgiwip suture ligature and extracorporeal tying techniques. None of the pregnancies in our previous reports occurred in patients in whom the endometrium was repaired laparoscopically [3]. A review of the literature reveals three reports of uterine dehiscence following laparoscopic myomectomy [14-16]. Difficulty in suturing the uterus was reported in two of those cases when the endometrium was entered. In our present series of patients, suturing the endometrium was easy, efficient and created a secure closure. Second-look laparoscopy revealed no visible, significant indentations at the sutured sites of even deep intramural myomas or large subserosal myomas.

Adhesion formation following laparoscopic myomectomy is the other major concern after laparoscopic myomectomy. Adhesion formation is not specific to laparoscopic surgery. Adhesions have been reported in 80% [17] and 100% [18] of cases in some reported series of open myomectomies. A high incidence of adhesions has also been reported after laparoscopic myomectomy with laparoscopic suturing [19]. In evaluation of adhesions (Table III), 66% of the patients had either no adhesions (Grade 0) or only one thin strand of a filmy adhesion to the uterus, of no clinical significance. No tubal or ovarian adhesions or fistulas were present in any of the patients, and all had patent fallopian tubes. In contrast to other reports [19], our three patients with Grade 3 adhesions probably had factors other than suturing the uterus which contributed to adhesion formation. Two of these patients had their myomas removed through transverse incisions on the posterior uterine fundus. In our experience, a transverse incision of the uterus is more difficult to suture laparoscopically with both traditional and Endo Stitch techniques. A transverse closure also creates a less smooth surface, and a longer, raw surface that

is continually exposed to the small bowel. We have discontinued the use of transverse incisions for removal of myomas. Extensive dissection and suturing of the uterus through vertical incisions (Case numbers 16, 13 and 29, Table III) produced either no adhesions or clinically insignificant, thin, filmy adhesions. The other incidence of Grade 3 adhesions occurred in a referred patient who was overtreated with GnRH (case 33, Table III). Prolonged treatment with GnRH caused hyaline degeneration and focal necrosis of the myoma, creating an "oatmeal"-like consistency of the myoma. Overtreatment with GnRH destroys the capsule of the myoma, thus preventing its easy dissection [20,21]. When the capsule of the myoma is not present, prolonged dissection is necessary, and more of the normal myometrium must be cut thus increasing areas of tissue injury [20,21]. Extensive and prolonged dissection with any type of laparoscopic energy source creates more necrotic areas in the remaining myometrium thus weakening the tissue. It has been hypothesized that the long-term consequence of this necrotic material in the suture line is an increased incidence of adhesions after a myomectomy [20,21]. In our experience [1,2,4], hyalinization and necrosis also makes accurate suture apposition of the edges of the uterine incision, with any laparoscopic suture technique, more difficult, increasing the possibility of adhesion formation.

We use a protocol for GnRH treatment before laparoscopic myomectomies specifically developed to prevent over-treatment, thus decreasing the incidence of hyaline degeneration and focal necrosis of myomas [4]. There are numerous identified and unidentified factors that can cause adhesion formation after a laparoscopic myomectomy and suturing of the uterus. However, in this study it appears that transverse incision of the uterus and over-treatment with a GnRH agonist were significant factors in the development of Grade 3 adhesions when the uterus was sutured with the Endo Stitch.

The mechanical problems we encountered with the Endo Stitch were immediately reported to the manufacturer (Auto Suture Company, Division of U.S. Surgical Corp.). Jamming of the toggle mechanism was resolved by the manufacturer. A different manufacturing process was also used to attach the suture to the needle in order to reduce the incidence of needle detachments from the suture. In addition, the needle was strengthened with more titanium. However, any surgical needle can break, even in

open surgery, if the tissue is unusually thick or surgical placement of the needle is incorrect.

We explain the possibility of needle breakage, which may require an open laparotomy, to all patients. There are no reports in the literature published in the United States of any practitioner knowingly leaving a broken, sharp-edge needle in the abdomen. However, a world-wide search of the literature does reveal a report of a problem which occurred after a sharp needle fragment was left in the abdomen. The fragment was reported to have migrated, over years, from the abdominal cavity into the bladder [22]. A broken Endo Stitch needle must be removed. In anticipation of removing small needle fragments, we have a Gemini Laparoscopic Grasper (Access Surgical International, Plymouth, MA) always available. In our experience, this is the best laparoscopic instrument for rapidly grasping and removing small needle fragments before they fall into the peritoneal cavity and are obscured by loops of small bowel and require open laparotomy for removal. The needle of the Endo Stitch is made of titanium; therefore, it will not respond to a magnet. To prevent breakage of the needle, the surgeon should not attempt to suture totally flat surfaces of the uterus. Dissection of a myoma should create flap-like edges of serosa and myometrium that are easily grasped with the Endo Stitch.

In conclusion, predicated upon the results of this study, the Endo Stitch 10-mm Laparoscopic Suturing Device in combination with our running, locked suture technique is a safe and effective method for laparoscopic suturing of the uterus. The endometrium can be opened laparoscopically and easily sutured in two layers. Utilization of the modification of our suture technique should allow a greater number of women to benefit from the minimally invasive procedure of laparoscopic myomectomy. We will evaluate and report the pregnancy performance of the patients in this study. In addition, we will continue to evaluate these uterine closures when appropriate opportunities for second-look laparoscopies occur in the future.

REFERENCES

1. Stringer NH: Laparoscopic myomectomy with the Endo Stitch 10mm Laparoscopic Suturing Device. *J Am Assoc Gyn Laparosc* (3):299-303, 1996.
2. Stringer NH: Laparoscopic myomectomy with the Harmonic Scalpel: A review of 25 cases. *J Gynecol Surg* 10:235-239, 1994.

3. Stringer NH, Strassner HT: Pregnancy in five patients after laparoscopic myomectomy with the Harmonic Scalpel. *J Gynecol Surg* 12:129-133, 1996.
4. Stringer NH: Laparoscopic myomectomy in African-American women. *J Am Assoc Gyn Laparosc* (3):87-93, 1996.
5. Nezhat C, Nezhat F, Silfen SL, et al: Laparoscopic myomectomy. *Int J Fertil* 36:275-280, 1991.
6. Dubussion JB, Leluru F, Foulot H, et al: Myomectomy by laparoscopy: A preliminary report of 43 cases. *Fertil Steril* 56:827-830, 1991.
7. Hasson HM, Rotman C, Rana N, et al: Laparoscopic myomectomy. *Obstet Gynecol* 80:884-888, 1992.
8. Daniell JF, Gurley LD: Laparoscopic treatment of clinically significant uterine fibroids. *J Gynecol Surg* 7:37-40, 1991.
9. Smith DC, Donohue LR, Waszak SJ: A hospital review of advanced gynecologic endoscopic procedures. *Am J Obstet Gynecol* 170:1635-1642, 1994.
10. Stringer NH, Levy ES, Kezmoh MP, et al: New closure technique for lateral trocar sites. *Surg Endosc* 9:838-840, 1995.
11. Buttram VC, Snabes MC: Indications for myomectomy. *Reprod Endocrinol* 10:328-384, 1992.
12. Graber JN, Schultz LS, Pietrafitta JL, et al: *Laparoscopic Abdominal Surgery*. New York, McGraw-Hill, 1993, p 22.
13. Nezhat C, Nezhat F, Pennington E, et al: Laparoscopic disk excision and primary repair of the anterior rectal wall for treatment of full thickness bowel endometriosis. *Surg Endosc* 8:682-685, 1994.
14. Friedman W, Maier RF, Luttkus A, et al: Uterine rupture after laparoscopic myomectomy. *Acta Obstet Gynecol Scand* 75:683-684, 1996.
15. Dubuisson JB, Chavet X, Chapron C, et al: Uterine rupture during pregnancy after laparoscopic myomectomy. *Hum Reprod* 10:1475-1477, 1995.
16. Harris WJ: Uterine dehiscence following laparoscopic myomectomy. *Obstet Gynecol* 80:545-546, 1992.
17. Tulandi T, Murray C, Guralnick M: Adhesion formation and reproductive outcome after myomectomy and second look laparoscopy. *Obstet Gynecol* 82:213-215, 1993.
18. Starks GC: CO₂ laser myomectomy in an infertile population. *J Reprod Med* 33:184-186, 1988.
19. Nezhat C, Nezhat F, Bess O, et al: Laparoscopic assisted myomectomy. A report of a new technique in 57 cases. *Int J Fertil* 39:39-44, 1994.
20. Friedman AJ, Rew MS, Harrison-Atlas D, et al: A randomized, placebo-controlled double-blind study evaluating leuprolide acetate depot treatment before myomectomy. *Fertil Steril* 52:728-733, 1989.
21. Fedele L, Bianchi S, Baglioni A, et al: Intranasal busferelin versus surgery in the treatment of uterine leiomyomas: Long-term follow-up. *Eur J Obstet Gynecol Reprod Biol* 38:53-57, 1990.
22. Irişawa C, Yamaguchi O, Shiraiwa Y, et al: A case of a foreign body in the urinary bladder—A surgical suture needle was found in the urinary bladder. *Hinyokika Kyo-Acta Urologica Japonica* 37(11): 1547-1549, 1991.

Address reprint requests to:

Nelson H. Stringer, M.D.

Department of Obstetrics and Gynecology

Columbia Michael Reese Hospital and Medical Center

One Baumgaren

Chicago, IL 60616