

Dec. 1996

Urinary tract endometriosis treated by laparoscopy*

Camran Nezhat, M.D.†‡§|| Fariba Nasserbakht, M.D.†
Farr Nezhat, M.D.‡§ Maurizio Rosati, M.D.¶
Ceana H. Nezhat, M.D.‡§ Daniel S. Seidman, M.D.‡

Stanford University School of Medicine, Stanford, and Nezhat Institute for Special Pelvic Surgery, Palo Alto, California;
Center for Special Pelvic Surgery, Atlanta, Georgia; and Clinique Sainte Elisabeth, Namur, Belgium

Objective: To evaluate the efficacy of the laparoscopic approach for the diagnosis and treatment of severe urinary tract endometriosis.

Design: Retrospective review of 28 cases of severe urinary tract endometriosis.

Setting: Center for Special Pelvic Surgery, a tertiary referral center.

Patient(s): Between October 1989 and September 1994, we treated 28 women who had deeply infiltrating urinary tract endometriosis (bladder, 7, ureter, 21).

Intervention(s): All procedures were performed laparoscopically.

Main Outcome Measure(s): Postoperative urinary function, pain relief, and complications.

Result(s): Those who had vesical endometriosis underwent partial cystectomy and primary repair. Partial ureteral obstruction was found in 17 women; 10 underwent ureterolysis and excision of endometriosis, and 7 had partial wall resection. Four patients with ureter involvement had complete obstruction. Three underwent partial resection and ureteroureterostomy, and one had ureteroneocystostomy. The rate of ureteral endometriosis in the present series is higher than that reported previously.

Conclusion(s): Severe infiltrative endometriosis of the bladder and the ureter can present without specific symptoms and can cause silent compromise of renal function. We demonstrated that the laparoscopic approach is safe and effective in the diagnosis and treatment of this entity. *Fertil Steril*® 1996;66:920-4

Key Words: Endometriosis, urinary tract, bladder, ureter, kidney, laparoscopic surgery

The surgical treatment of endometriosis has improved the results because of the introduction of new laparoscopic techniques (1, 2). Involvement of the urinary tract with endometriosis is relatively uncommon (3-12), but it can be clinically significant. Endometriosis can involve the bladder or completely

obstruct the ureter, resulting in the loss of kidney function (3, 4). This report summarizes the laparoscopic management of 28 women who had severe endometriosis of the urinary bladder or ureter.

MATERIALS AND METHODS

Between October 1, 1989 and September 30, 1994, 2,226 women were treated for endometriosis. Twenty-eight women (1.3%) had severe urinary tract endometriosis, defined as partial or complete ureteral obstruction (n = 21) or deep full-thickness infiltration of the bladder muscularis (n = 7). Patients with noninfiltrating or nonobstructing endometriotic lesions of the peritoneum or serosa of the bladder or ureter were excluded.

The 21 women with ureteral obstruction ranged in age from 24 to 46 years (mean 35 years) and the 7 patients with bladder infiltration ranged from 27

Received March 25, 1996; revised and accepted July 8, 1996.
* Presented in part at the 50th Annual Meeting of The American Fertility Society, San Antonio, Texas, November 5 to 10, 1994.
† Department of Surgery, Stanford University School of Medicine.
‡ Department of Gynecology and Obstetrics, Stanford University School of Medicine.
§ Center for Special Pelvic Surgery and Nezhat Institute for Special Pelvic Surgery.
|| Reprint requests: Camran Nezhat, M.D., Stanford Endoscopy Center for Training and Technology, 900 Welch Road, Suite 403, Palo Alto, California 94304 (FAX: 415-327-2794).
¶ Department of Obstetrics and Gynecology, Clinique Sainte Elisabeth.

to 39 years (mean 30 years). Postoperative hospital stay for all patients was 1 to 6 days (mean 1.8 days) and duration of follow-up was from 5 to 33 months (mean 22 months).

Twenty-seven women presented with chronic pelvic pain. One woman who had vesical endometriosis was referred for evaluation and treatment of menorrhagia. In the ureter group, 14 reported localized pelvic pain during menstruation and 11 complained of vague back pain. Three of the patients with bladder disease reported menorrhagia, one of whom had undergone transurethral resection of endometriosis. Although 25 of the patients had prior laparotomy or laparoscopy for endometriosis, the advanced nature of their disease was diagnosed correctly in 3 who had bladder disease and 3 who had ureteral disease.

Procedures

Under general anesthesia, an umbilical incision was made and a videolaparoscope (Circon-ACMI, Stamford, CT) was introduced. Three suprapubic ports were placed to insert grasping forceps, bipolar forceps, and suction-irrigator probe. Lactated Ringer's solution was delivered through a high-pressure pump for hydrodissection. A CO₂ laser (Coherent Inc., Palo Alto, CA) set at 40 to 80 W was used for cutting and bipolar forceps were used for hemostasis (2). The abdominal and pelvic cavity were explored, the lesions were identified, and associated procedures were performed, including total laparoscopic hysterectomy and bilateral salpingo-oophorectomy in five patients, laparoscopic assisted vaginal hysterectomy in two patients, salpingo-oophorectomy in three patients, and segmental bowel resection and anastomosis in four patients. All procedures were performed by the senior authors (C.N., F.N., and C.H.N.).

Bladder Endometriosis

Using hydrodissection, the peritoneum over the bladder was opened and a bladder flap was created. After dissecting the bladder from the surrounding tissue, we entered the bladder via cystotomy and resected the involved areas using the CO₂ laser (3). Simultaneous cystoscopy was performed to improve observation of the ureteral orifices and for retrograde catheterization. The defect was closed in one layer using extracorporeal or intracorporeal knot-tying techniques with 4-0 polydioxanone or 0 polyglactin suture (13).

We performed cystoscopy at the end of the procedure to ensure water-tight closure. Bladder drainage was continued for 10 to 14 days postoperatively. Before discontinuing bladder drainage, all women had

cystograms to confirm that the bladder had healed and there was no leakage.

Ureteral Endometriosis

All women required extensive ureterolysis, i.e., mobilization of the ureter adhered to the pelvic wall. The retroperitoneal space was entered at the level of the pelvic brim. The overlying peritoneum was opened with the CO₂ laser and elevated by injecting irrigation fluid. The opening was enlarged, an irrigation probe was inserted, and more fluid was introduced into the retroperitoneal space along the course of the ureter. The fluid surrounds the ureter, moves it posteriorly, and allows safe superficial laser dissection or vaporization. If the endometrial implant was embedded and deeply scarred, the ureter was freed from surrounding tissue using hydrodissection and CO₂ laser, avoiding damage to the major pelvic wall blood vessels. Any bleeding that was not controlled by the CO₂ laser was managed with bipolar electrodesiccation (4).

After ureterolysis was completed, endometriosis and fibrosis were vaporized or excised until the ureter was dissected completely and free of disease. At this point, if the ureter was obstructed partially or completely and required resection, a retrograde ureteral catheter was placed via cystoscopy with laparoscopic guidance. Partial wall resection was done over the catheter. Pinpoint entries to the lumen were not repaired.

When the lumen was invaded, the ureter was repaired with one to three interrupted 4-0 polydioxanone sutures. If the lumen was occluded completely and retrograde catheter placement was unsuccessful, we transected the ureter at that point using the laser and excised the obstructed section. Indigo carmine was injected antegrade to verify patency of the proximal lumen (4). Anastomosis was performed over the ureteral catheter with four interrupted through-and-through 4-0 polydioxanone sutures at 3, 6, 9, and 12 o'clock to approximate the proximal and distal ureteral segments or to rejoin the ureter and bladder using intracorporeal or extracorporeal knot tying. The ureteral stents were removed 2 to 8 weeks postoperatively after the integrity of the repair was confirmed by IV pyelogram.

RESULTS

Vesical Endometriosis

Among the seven women with bladder involvement, the lesions were in the bladder base and dome in six cases, and the bladder was densely adherent to the anterior surface of the uterus and cervix or

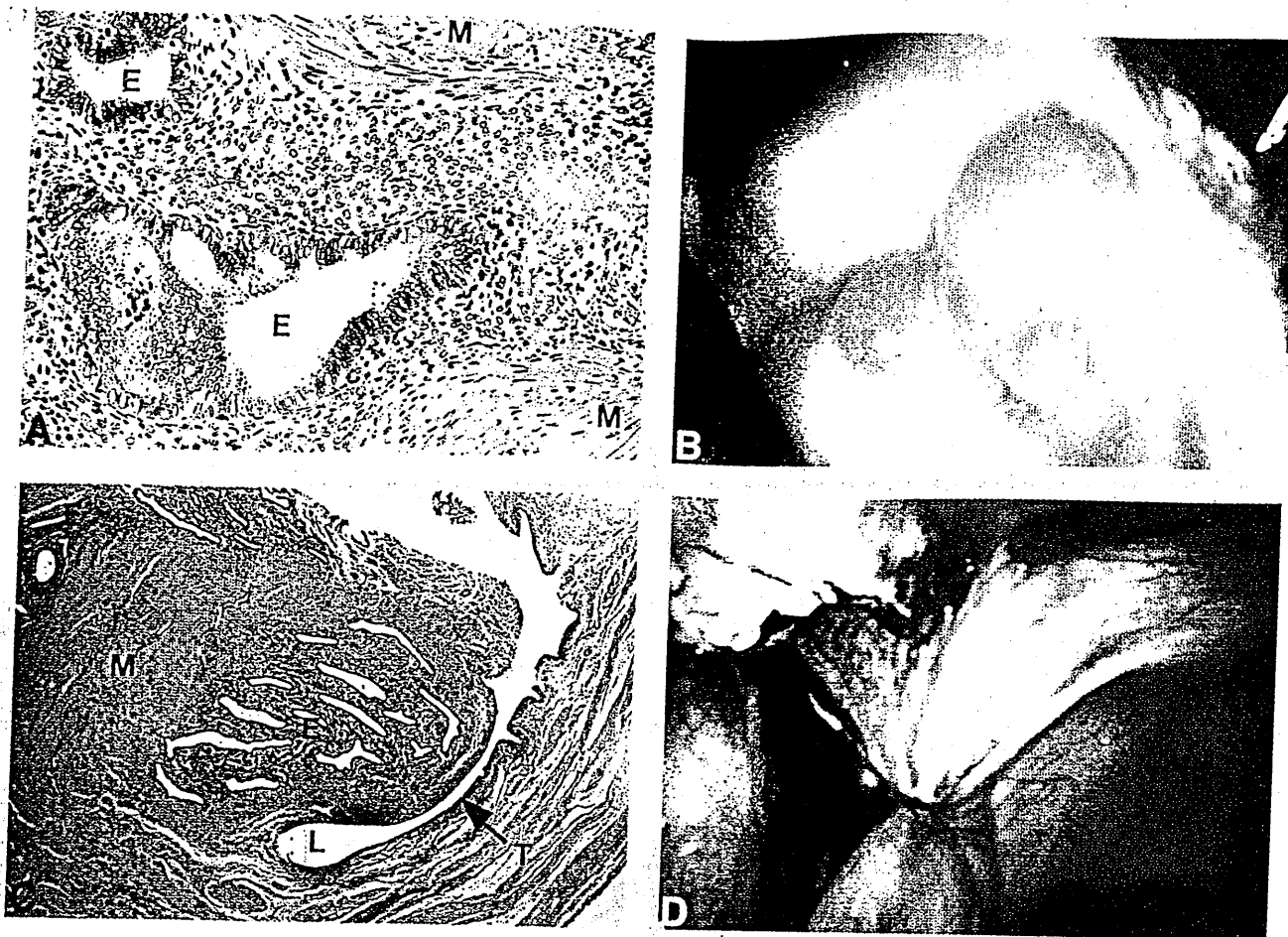


Figure 1 (A), Histology of bladder endometriosis. The muscularis of the bladder has been infiltrated deeply by endometriosis. M, muscularis; E, endometriosis. (B), Laparoscopic view of endometriosis on the bladder mucosa during partial cystectomy. (C), Histology of ureter endometriosis: the lesion involves the muscularis and has penetrated the ureteral lumen. E, lesion; M, muscularis; L, ureteral lumen; T, transitional epithelium of the ureter. (D), Laparoscopic view of endometriosis of left ureter with complete obstruction at the level of the uterosacral ligament.

the vagina. In one patient, the lesion was completely inside the bladder, and the bladder was densely adherent to the anterior abdominal wall. In all seven women, there was deep muscularis involvement (Fig. 1A) and, in some, it extended to the mucosa. In six, the depth of involvement required full-thickness segmental bladder resection (Fig. 1B). In one case, the mucosa was not resected.

No postoperative complications occurred. During the follow-up period, there was no recurrence of bladder symptoms. Two patients had recurrent pelvic pain and underwent second-look laparoscopy at 3 and 24 months after the first operation. One had severe adhesions between the bladder and uterus; the other had an ovarian endometrioma.

Ureteral Endometriosis

Seventeen women had extrinsic disease causing partial obstruction and four had full-thickness or in-

trinsic disease affecting the muscularis or lumen and causing complete obstruction (Fig. 1C and D). Nine had right and 11 had left ureter involvement, and 1 had bilateral involvement. The site of obstruction was at or below the level of uterosacral ligament in 13 cases, and above the ligament in 8. Ten patients who had partial ureteral obstruction underwent ureterolysis with vaporization and excision of endometriosis and seven underwent partial wall resection. Of those who underwent partial wall resection, two needed ureteral repair. Five others had pinpoint lacerations that occurred during dissection and resection of deep endometriosis and uterolysis. The lacerations were detected with IV indigo carmine. In these patients, 7F ureteral stents were left in place without sutures for repair. In 13 women, an internal stent was placed for 2 to 8 weeks postoperatively. In four, retroperitoneal drains also were placed for the first few postoperative days. All four women with

complete obstruction underwent segmental ureteral resection, three had ureteroureterostomy and one had ureteroneocystostomy.

Thirteen women (62%) had concomitant bowel endometriosis. Three with deep infiltrative endometriosis underwent segmental bowel resection and anastomosis (14, 15); in the remaining 10 patients, endometriotic lesions were vaporized or excised without complete bowel wall resection. A rare case of endometriotic tissue with focal severe atypical hyperplasia was found in a patient who had undergone total abdominal hysterectomy and bilateral salpingo-oophorectomy 10 years earlier and had been taking unopposed estrogen replacement therapy. This therapy was discontinued after the operation.

One postoperative complication occurred. After excision of pelvic and ureteral endometriosis and removal of pelvic mesothelium, a 36-year-old woman developed pleural effusion on the first postoperative day. The effusion was managed by thoracentesis and aspiration.

All patients had postoperative IV pyelogram; 20 had patent ureters and functional kidneys bilaterally. The exception was a 24-year-old who presented with complete ureteral obstruction, probably longstanding. Intraoperatively, we suspected that the kidney was not functioning as the IV indigo carmine injected was not secreted. Correction of the obstruction was too late as the kidney was damaged by silent necrosis. Although postoperative imaging showed ureteral patency, it revealed only a 10% to 20% functioning kidney.

During the follow-up period, 20 (95%) patients reported pain relief. Intravenous pyelogram or renal ultrasounds have been performed in all women, and none has shown signs of ureteral obstruction or hydroureter. Two had subsequent operations for pelvic pain. One had an adnexal mass arising from an ovarian remnant contralateral to the treated ureter, and the other had a pelvic mesothelioma with ureter involvement. Interestingly, she was the same patient who developed pleural effusion postoperatively. At the later operation there was no endometriosis, but the ureter was involved with mesothelioma, which required resection and anastomosis.

DISCUSSION

Ureteral and vesical endometriosis often seem to arise from pre-existing foci of pelvic endometriosis (16, 17). In this series, ureter involvement usually occurred at or below the level of the uterosacral ligament, suggesting the theory of retrograde flow and implantation.

Early diagnosis of urinary tract endometriosis is

important to avoid loss of renal function. Menouria, dysuria, and/or suprapubic pain indicate possible urinary tract involvement. However, symptoms and physical findings vary and are rarely pathognomonic. Although ureteral obstruction by endometriosis can be completely asymptomatic (18-21), 27 patients in this series presented with chronic pelvic pain. Urinalysis with cytologic examination, urography, IV pyelogram, and computerized tomography (CT) are all nonspecific for diagnosis of urinary tract endometriosis (22). Definitive diagnosis requires surgical exploration of the bladder or ureter and a biopsy. In our series, only five patients with ureteral obstruction had preoperative IV pyelograms ordered by the referring physicians. One patient was diagnosed preoperatively to have hydronephrosis on CT scan. In the remaining two thirds of cases, ureteral endometriosis was unsuspected.

Urinary tract involvement is estimated to occur in 1% to 16% of patients with endometriosis, and fewer than 1% are reported to have obstruction or infiltrative disease (4-10). We defined urinary tract involvement as full-thickness or deep infiltration of the muscularis layer in the bladder and partial or complete obstruction of the ureter. Of the 28 patients in our series, 7 (25%) had vesical endometriosis and 21 (75%) had ureteral disease. These findings contrast earlier studies in which the bladder is reported to be involved more frequently with endometriosis (up to 85% of urinary tract cases) than the ureter (4-9). The different findings in our study may be related to case definitions, patient populations (ours is primarily referral), and diagnostic approaches (recognition may differ between laparotomy and laparoscopy).

Similarities with previous studies of ureteral endometriosis include the approximate ratio of four cases of extrinsic to one case of intrinsic disease and the finding of dense fibrosis with either type (7, 23, 24). One patient had atypical hyperplasia in a periureteric endometrial lesion. Cases of malignant changes in extragenital endometriosis have been reported (25).

Early diagnosis and treatment of urinary tract endometriosis are necessary to avoid loss of kidney function. The incidence of silent loss of renal function resulting from ureteral endometriosis is reported to be as high as 25% to 43% (5). In our series, 1 (4.8%) of the 21 women with ureter obstruction had silent loss of kidney function. She was among the 15 (71%) in the ureter group who had partial laparoscopic treatment of pelvic endometriosis followed by hormonal suppressive therapy. Because dense fibrosis invariably accompanies ureteral endometriosis, we recommend early excision of the lesion

to prevent obstruction and loss of renal function. In this situation, surgery clearly is superior to medical management. Of the 15 women who had prior treatment of endometriosis, only 3 (14%) were diagnosed to have ureteral involvement. To reduce the chances of missing ureter endometriosis, the ureters should be evaluated in every patient who has surgery for pelvic endometriosis.

Hysterectomy and oophorectomy have been recommended for patients with urinary tract endometriosis who do not desire future pregnancy (6). These procedures alone do not correct ureteral fibrosis and their benefit to the patient is unclear. When urinary tract endometriosis is suspected, a workup including IV pyelogram should be done, and laparoscopy should be considered. In patients with dysuria, especially if it is associated with menouria, cystoscopy also should be performed. In our experience, laparoscopy provides better visualization of urinary tract lesions than laparotomy and allows for immediate surgical correction. The magnification and angle of observation available at videolaparoscopy allow good access to the deep pelvis. Experienced laparoscopists familiar with endometriosis can treat urogenital endometriosis safely and effectively. Our approach to treat bladder disease is segmental resection, similar to that at laparotomy. However, only 4 of the 21 women with ureteral endometriosis required resection and anastomosis. For the remainder, ureterolysis, resection of endometriosis, and partial ureter resection and repair were done. Optimal treatment of urinary tract endometriosis should be ensured by a team of experts who are familiar with endometriosis, its multifaceted manifestations, and its management.

Acknowledgments. We gratefully acknowledge the assistance of Gary S. Berger, M.D. (Department of Obstetrics and Gynecology, University of North Carolina School of Medicine, Chapel Hill, North Carolina), Howard Rottenberg, M.D. (urologist, Atlanta, Georgia), Fuad Frieha, M.D. (Department of Urology, Stanford University School of Medicine, Stanford, California), and Chidhura Gill, M.D. (Department of Urology, Stanford University School of Medicine, Stanford, California) in preparing this manuscript.

REFERENCES

1. Canis M, Bruhat MA, Pouly JL, Cooper MJM, Wattiez A, Manhes H. Techniques for ablation and excision of endometriosis. In: Nezhat CR, Berger GS, Nezhat FR, Buttram VC Jr, Nezhat CH, editors. *Endometriosis: advanced management and surgical techniques*. Springer-Verlag: New York, 1995:85-94.
2. Nezhat C, Nezhat F, Luciano AA, Siegler AM, Metzger DA,

- Nezhat CH, editors. *Laparoscopic treatment of endometriosis*. In: *Operative gynecologic laparoscopy: principles and techniques*. New York: McGraw Hill, 1995:121-47.
3. Nezhat C, Nezhat F. Laparoscopic segmental bladder resection for endometriosis. *Obstet Gynecol* 1993;81:882-4.
4. Nezhat C, Nezhat F, Green B. Laparoscopic treatment of obstructed ureter due to endometriosis by resection and ureteroureterostomy. A case report. *J Urol* 1992;148:865-8.
5. Stillwell TJ, Kramer SA, Lee RA. Endometriosis of the ureter. *Urology* 1986;28:81-5.
6. Abeshouse BS, Abeshouse G. Endometriosis of urinary tract. *J Int Coll Surg* 1960;334:43-68.
7. Stanley KE, Utz DC, Dockerty MD. Clinically significant endometriosis of the urinary tract. *Surg Gynecol Obstet* 1965;120:491-8.
8. Neto WA, Lopes, RN, Cury, Montellato NID, Arap S. Vesical endometriosis. *Urology* 1984;24:271-4.
9. Aldridge KW, Burns, JR, Singh B. Vesical endometriosis: a review of two case reports. *J Urol* 1985;134:539-41.
10. Williams TJ, Pratt JH. Endometriosis in 1000 consecutive celiotomies: incidence and management. *Am J Obstet Gynecol* 1977;129:245-52.
11. Reddy AN, Evans AT. Endometriosis of the ureters. *J Urol* 1974;111:474-80.
12. Bazaz-Malik G, Saraf V, Rana BS. Endometrioma of the kidney. Case report. *J Urol* 1980;123:422.
13. Nezhat CH, Seidman D, Nezhat F, Rottenberg H, Nezhat C. Laparoscopic management of intentional and unintentional cystotomy. *J Urol*. In press.
14. Nezhat F, Nezhat C, Pennington E, Ambrose W. Laparoscopic segmental resection for infiltrating endometriosis of the rectosigmoid colon: a preliminary report. *Surg Laparosc Endosc* 1992;2:212-6.
15. Nezhat C, Nezhat F, Pennington E, Ambrose W. Laparoscopic repair of small bowel, colon and rectal endometriosis. *Surg Endosc* 1993;7:88-9.
16. Sampson JA. Peritoneal endometriosis due to the menstrual dissemination of the endometrial tissue into the peritoneal cavity. *Am J Obstet Gynecol* 1927;14:422-69.
17. Manuel E, Meyersfield S, Seery W, Cole AT. Combined vesical and abdominal endometriosis following hysterectomy: a case report. *J Urol* 1977;118:332-3.
18. Esen T, Akinci M, Ander H, Tunc M, Tellaloglus S, Narter I. Bilateral ureteric obstruction secondary to endometriosis. *Br J Urol* 1990;66:948-9.
19. Moore JG, Hibbard LT, Growdon WA, Schiffrin BS. Urinary tract endometriosis: enigmas in diagnosis and management. *Am J Obstet Gynecol* 1979;134:162-72.
20. Kerr WS. Endometriosis involving the urinary tract. *Clin Obstet Gynecol* 1966;9:331-57.
21. Koszczuk JC, Foglietti M, Perez J, Dono FV, Tomas RJ. Urinary tract endometriosis. *J Am Osteopath Assoc* 1989;1:83-9.
22. Schneider V, Smith MJ, Frable WJ. Urinary cytology in endometriosis of the bladder. *Acta Cytol* 1980;24:30-3.
23. Patel A, Thorpe P, Ramsay JWA, Shepherd JH, Kirby RS, Hendry WF. Endometriosis of the ureter. *Br J Urol* 1992;69:495-8.
24. Langmeade CF. Pelvic endometriosis and ureteral obstruction. *Am J Obstet Gynecol* 1975;122:463-9.
25. Brooks JJ, Wheeler JE. Malignancy arising in extra-gonadal endometriosis. A case report and summary of the world literature. *Cancer* 1977;40:3065-73.