

## Trocar Injuries in Laparoscopic Surgery

Sunil Bhojru, MD, FRCS, Mark A Vierra, MD, FACS, Camran R Nezhat, MD, FACS,  
Thomas M Krummel, MD, FACS, Lawrence W Way, MD, FACS

- BACKGROUND:** Disposable trocars with safety shields are widely used for laparoscopic access. The aim of this study was to analyze risk factors associated with injuries resulting from their use as reported to the Food and Drug Administration.
- STUDY DESIGN:** Manufacturers are required to report medical device-related incidents to the Food and Drug Administration. We analyzed the 629 trocar injuries reported from 1993 through 1996.
- RESULTS:** There were three types of injury: 408 injuries of major blood vessels, 182 other visceral injuries (mainly bowel injuries), and 30 abdominal wall hematomas. Of the 32 deaths, 26 (81%) resulted from vascular injuries and 6 (19%) resulted from bowel injuries. Eighty-seven percent of deaths from vascular injuries involved the use of disposable trocars with safety shields and 9% involved disposable trocars with a direct-viewing feature. The aorta (23%) and inferior vena cava (15%) were the vessels most commonly traumatized in the fatal vascular injuries. Ninety-one percent of bowel injuries involved trocars with safety shields and 7% involved direct-view trocars. The diagnosis of an enterotomy was delayed in 10% of cases, and the mortality rate in this group was 21%. In 41 cases (10%) the surgeon initially thought the trocar had malfunctioned, but in only 1 instance was malfunction subsequently found when the device was examined. The likelihood of injury was not related to any specific procedure or manufacturer.
- CONCLUSIONS:** These data show that safety shields and direct-view trocars cannot prevent serious injuries. Retroperitoneal vascular injuries should be largely avoidable by following safe techniques. Bowel injuries often went unrecognized, in which case they were highly lethal. Device malfunction was rarely a cause of trocar injuries. (J Am Coll Surg 2001;192:677-683. © 2001 by the American College of Surgeons)

Trocar injury is one of the most serious, potentially preventable complications in laparoscopic surgery. Disposable trocars have features intended to minimize these injuries. Either a plastic sleeve snaps over the cutting tip after the abdominal wall has been penetrated (safety shield), or the trocar and laparoscope are inserted as a unit on the assumption that looking at the abdominal

wall tissues as the trocar passes through them would help to avoid visceral injuries (direct view). Despite these features there are numerous reports of serious, occasionally fatal, injuries resulting from disposable trocars. There is no national registry of such injuries, nor is there evidence concerning whether they reflect design flaws, device malfunction, user errors, or are more commonly associated with certain operations or manufacturers.

Manufacturers and users are required to report medical device-related incidents to the Food and Drug Administration (FDA), whose records through 1996 are available on the Internet. In this study we analyzed all reported complications from laparoscopic trocars in the period 1993 to 1996. The objective was to describe the major types of trocar injuries and to analyze them with respect to the type of trocar and type of operation and to determine if there were any other common circumstances.

### METHODS

The Medical Device Reports (MDR) were obtained from a search of the database provided by the Center for

#### No competing interests declared.

All of the authors have previously received financial support from the major device manufacturing companies, including Ethicon Endo Surgery, United States Surgical Inc (a division of TYCO international), and Innerdyne Inc (a division of TYCO international).

Abstract presented at the American College of Surgeons, 86th Annual Clinical Congress, Surgical Forum, Chicago, IL, October 2000.

Received February 27, 2001; Accepted February 27, 2001.

From the Department of Surgery (Bhojru, Vierra, Nezhat, Krummel), and Obstetrics and Gynecology (Nezhat), Stanford University School of Medicine, Palo Alto, CA, and the Department of Surgery, University of California San Francisco School of Medicine, San Francisco, CA (Way).

Dr. Bhojru's current affiliation is Scripps Clinic Medical Group, La Jolla, CA.

Correspondence address: Lawrence W Way, MD, Division of General Surgery, University of California San Francisco School of Medicine, Room 5050, 513 Parnassus Ave, San Francisco, CA 94143-0475.

**Table 1.** Trocar Injuries Reported to the Food and Drug Administration from 1993 to 1996

Type of trocar injury	n
Deaths	32
Nonfatal vascular injuries	382
Nonfatal visceral injuries	176
Abdominal wall hematomas	30
Unclassified	8
Total	629

Devices and Radiological Health (CDRH) at [www.fda.gov/cdrh/mdrfile](http://www.fda.gov/cdrh/mdrfile). The MDR for 1993 through August 1996 were downloaded from the Internet. Under the Freedom of Information and Privacy Acts, reports provided by the FDA do not contain the following: Any information that constitutes trade secrets, confidential, commercial, or financial information; and any personal, medical, and similar information that would constitute a clearly unwarranted invasion of personal privacy.

The MDR data were transferred into Microsoft Access, which allows files to be searched by keywords. All the MDR were scanned using the search words trocar, trochar, and troca. In some reports the device name did not contain the word trocar or similar terms. The search was repeated using all known trade names to ensure that all relevant trocar injury reports were selected.

Once all trocar reports (malfunctions, injuries, and deaths) were identified, those that did not include patient injury or death were excluded. A few duplicate reports were found and eliminated. The years 1993 to 1996 were selected for analysis because there were hardly any injuries reported before 1993 and the data were incomplete after 1996.

Injuries were classified as major vascular injuries, visceral injuries, or abdominal-wall injuries. Deaths, regardless of cause, were all analyzed. Each case was studied with regard to the nature of the injury (ie, vessel or organ injured), device manufacturer, type of procedure, and explanatory comments from the surgeon or manufacturer.

**Table 3.** Operations Resulting in Fatal Trocar Injuries

Type of laparoscopic procedure	n
Cholecystectomy	16
Diagnostic laparoscopy	3
Tubal ligation	2
Appendectomy	2
Lymphadenectomy	1
Unspecified	8

**Table 2.** Cause of Death in Fatal Trocar Injuries

Cause of death	n
Unrecognized bowel injuries	6
Vascular injuries	26
Aorta or IVC	10
Iliac vessels	3
Other vessels	13

## RESULTS

Table 1 shows the number of reports for each type of injury. Of the 32 deaths, 26 resulted from vascular injuries and 6 resulted from bowel injuries. There were 408 vascular injuries and 182 visceral injuries. Eight reports were too incomplete to be analyzed.

Table 2 shows the reported causes of death. Among the six fatal unrecognized bowel injuries, in one it was unclear whether the injury was caused by a trocar or the electrocautery. Twenty-eight deaths resulted from the use of disposable, safety-shielded trocars and three resulted from direct-view trocars. There was one death from a reusable trocar. Table 3 shows the procedure being performed during the fatal injuries. Table 4 summarizes the explanatory comments provided with four of the fatal injuries.

Of the 382 nonfatal vascular injuries, 355 resulted from the use of disposable, safety-shielded trocars and 27 resulted from the use of direct-view trocars. Table 5 shows the vessels injured and Fig. 1 shows the total number of vascular injuries with the six most common operations. In addition to those shown, there were nonfatal vascular injuries reported from laparoscopic procedures for ectopic pregnancy (n = 6), oophorectomy (n = 9), fundoplication (n = 4), orchiopexy (n = 1), vagotomy (n = 1), colectomy (n = 1), myomectomy (n = 1), and lymphadenectomy (n = 3). In 144 reports the operation performed was not specified. A concomitant bowel injury occurred during 35 (9%) of the 382 vascular injuries. Table 6 summarizes the most common explanatory comments from the surgeons.

Of 176 nonfatal visceral injuries, 128 (73%) involved

**Table 4.** Comments about Four Cases of Fatal Trocar Injuries

1. Bleeding disorder unknown before surgery
2. Abdominal aortic aneurysm unknown before surgery
3. Trocar reinserted into abdomen without reestablishing pneumoperitoneum
4. Surgeon's first laparoscopic cholecystectomy

intestine (Table 7). Table 8 summarizes the comments that accompanied the reports of bowel injury. Twenty-two nonfatal bowel injuries went unrecognized during the index procedure in addition to the six fatal unrecognized bowel injuries. The mortality rate from an unrecognized bowel injury was 21% (6 of 28).

There were 30 reports of abdominal-wall bleeding, all of which were caused by disposable safety shield trocars. Eight of these led to reoperations, nine resulted in blood transfusions, and six required a laparotomy to control the bleeding.

## DISCUSSION

The incidence of major vascular injuries from trocars and Veress needles averages around 0.1%.<sup>1-4</sup> Among 2,324 laparoscopic gynecologic operations reviewed by Bateman and colleagues<sup>5</sup> there were just 20 (0.22%) such complications, 75% of which were caused by trocars or Veress needles. In another prospective study of 743 laparoscopic gynecologic operations there were 11 (1.4%) trocar complications, 7 of which were vascular injuries (0.9%).<sup>6</sup> An early (1992) survey of complica-

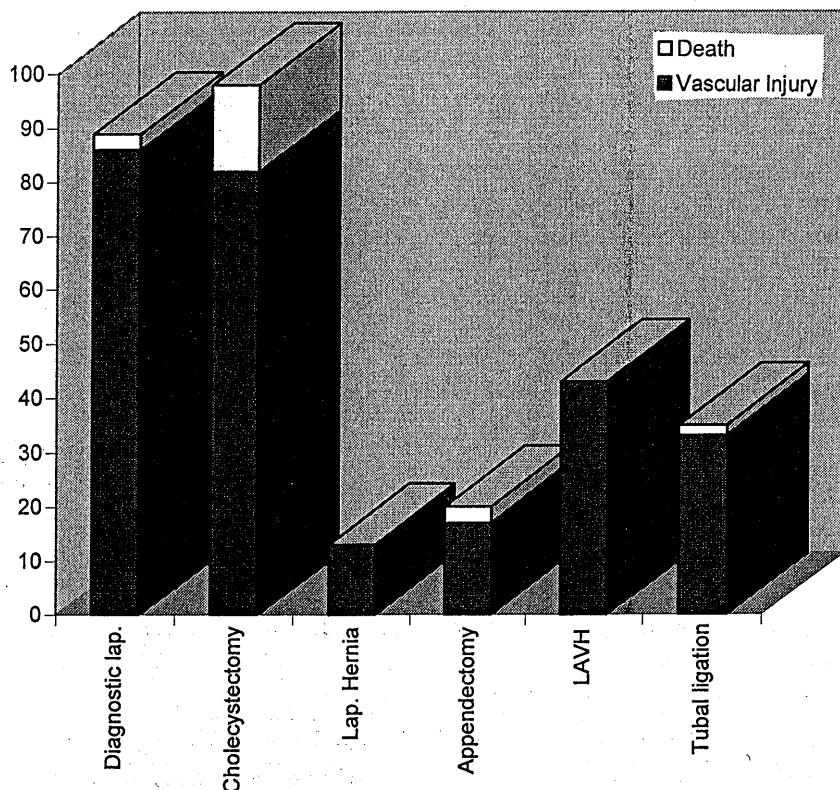
**Table 5.** Vessels Punctured in Nonfatal Vascular Injuries

Vessel injured	n
Iliac vessels	151
Aorta or IVC	69
Mesenteric vessel	32
Other vessels (not always specified)	129

tions in laparoscopic general surgery cited 34 trocar injuries of retroperitoneal vessels among 77,604 operations (0.04%), 3 of which were lethal.<sup>7</sup> Even though these data indicate that the problem is uncommon, a survey of Canadian gynecologists revealed that 25% had experienced trocar injuries.<sup>8</sup> The potential seriousness of these events prompted this study.

Trocar injuries can result from a defect in the instrument or from errors in usage. This paper examines both.

Most of the FDA cases involved devices that appeared to be functionally normal. The data would not support a contention that safety-shield malfunction was a common factor. There were few reports in which safety-shield malfunction was alleged to have contributed and even fewer in which malfunction was actually found.



**Figure 1.** Vascular injuries (fatal and nonfatal) with six of the most commonly reported procedures.

**Table 6.** Comments about Nonfatal Vascular Injuries

Comment	n
<b>Injuries associated with loss of pneumoperitoneum or excess force</b>	27
Injury occurred during reinsertion of trocar after loss of pneumoperitoneum	10
No insufflation used	6
Multiple attempts made to deploy trocar	5
Additional force applied after initial difficulty in penetrating abdominal wall	3
Injury caused by long trocar, after initial attempt to gain access with short trocar	1
Injury to gastroduodenal artery on fourth attempt to enter abdomen	1
Aorta, duodenum, and vertebral column injured	1
<b>Reports of device malfunction</b>	41
Question raised of faulty safety shield	38
Obturator broke and pierced vessel	2
Manufacturer confirms that dented trocar led to safety shield malfunction	1
<b>Admission of erroneous technique</b>	11
Vascular injury caused by accessory trocar under direct view	3
Surgeon acknowledged erroneous technique	8

This implies that the principal risks concern how safety-shielded trocars are used.

In general, trocar injuries to abdominal viscera occur 1) when the viscera are unusually close to the point of trocar insertion or 2) where the trocar penetrates too far into the abdominal cavity as it is inserted. The first of these situations can be anticipated when the patient has had a previous operation. The best way to avoid visceral injury in this case is to use the open Hasson technique or, if the closed technique is used, to place the first trocar at a site remote from the previous incision.

There were no reports of injuries occurring during the open (Hasson) technique of insertion, but such complications would not have been considered device-related and appropriate to submit to the FDA. There are case reports of injury,<sup>9,10</sup> and one retrospective review of 6,173 laparoscopies cited a 0.06% incidence of bowel

**Table 7.** Nonfatal Visceral Injuries

Viscera injured	n
Bowel (unspecified)	74
Small bowel	25
Large bowel	23
Stomach	5
Duodenum	1
Liver	20
Omentum	9
Bladder	5
Uterus	6
Pancreas	1
Ureter	1

injuries with the Hasson technique.<sup>11</sup> The Hasson method of trocar insertion, although less likely to cause a vascular injury, has not been adopted for routine use because it is more cumbersome in many ways. It is advisable in the presence of an aortic aneurysm or pregnant uterus, or when any other mass is close to the abdominal wall.

Safety shields obviously cannot prevent all visceral injuries; the unshielded sharp tip is always exposed to the abdominal contents at least briefly. It seems to us that there may be a tendency for surgeons to expect more than the modest protection that safety shields can provide.

One novel design intended to avoid visceral injuries is the direct-view trocar. The laparoscope and cannula are inserted as a unit, and the surgeon can see the tissues as the trocar passes through them. Presumably the surgeon would be able to see a viscus early enough to stop short of perforating it. Although there are claims that this device is safer than conventional cutting trocars,<sup>12-14</sup> the FDA data included deaths and major vascular and bowel injuries from direct-view trocars, and they have not become popular.

The data, including the surgeons' comments accompanying them, reveal specific technical errors that can

**Table 8.** Comments about Nonfatal Visceral Injuries

Comment
Alleged safety shield malfunction
Loss of insufflation
Patient not fully relaxed
Adhesions
Caused by accessory trocar
Injury repaired laparoscopically

attributed to trocar injuries. Common examples were inadequate stabilization of the abdominal wall, excessive resistance to trocar insertion, and excessive, misdirected, or poorly controlled force directed by the surgeon along the axis of the trocar.

Before inserting a trocar, the abdominal wall should be stabilized. The distance between the anterior abdominal wall and the retroperitoneal vessels is normally 3 to 4 cm, but in the average patient it can be increased to 8 to 14 cm by a pneumoperitoneum or by lifting the anterior abdominal wall with towel clips (external counter-traction) placed through the skin next to the incision made for the trocar. The objectives are to maximize this distance and to put the paralyzed abdominal wall under tension so it indents as little as possible with pressure from the trocar tip.

The FDA case reports included several injuries in situations in which a pneumoperitoneum was not used or was suddenly lost. For example, 27 vascular injuries occurred in the absence of a pneumoperitoneum or as the surgeon used too much force while inserting the trocar. Yerdel and colleagues<sup>15</sup> reported no serious complications with 1,030 direct trocar insertions using safety-shielded trocars and no pneumoperitoneum. Byron and colleagues<sup>16</sup> and Nezhat and colleagues<sup>17</sup> also found the direct entry method to be safe as long as counter-traction was used.

We use an initial pressure of 14 to 18 mmHg for the pneumoperitoneum, which puts the abdominal wall under firm tension. If the abdomen does not become distended as it should, the patient may be incompletely paralyzed. If the pneumoperitoneum appears to be adequate and the abdominal wall still dimples substantially with pressure from the trocar, the skin adjacent to the incision may be held by towel clips to provide additional resistance. Alternatively, the Hasson technique may be used. More than the usual amount of laxity in the face of an adequate pneumoperitoneum may be seen in very thin patients, after multiple pregnancies, or in any condition where the abdominal musculature has atrophied.

Once the abdominal wall is stabilized, the surgeon must make sure the skin incision is long enough that the skin edges no longer offer resistance to trocar insertion. When the incision is just 1 to 2 mm too short, it may look sufficient because the safety shield can be accommodated, but the rim of the cannula gets caught. The cause of the increased resistance may not be evident, so when the trocar is pushed the surgeon may think the fascia is just sturdier than usual. Then, as force is increased, the

entire instrument suddenly slips through the incision and the sharp tip may pass farther into the abdominal cavity than intended. The surgeon may incorrectly attribute the overshoot and resulting injury to abnormally thick fascia or failure of the safety shield to deploy. A reusable trocar whose cutting tip has become dull can produce a similar phenomenon, but most laparoscopic surgeons now use disposable trocars.

There were multiple injuries in which the surgeon reported excessive or uncontrolled axial force. With an optimal setup, passing the trocar through the abdominal wall should require only moderate force. Force is applied along the axis of the trocar against the resistance of the abdominal wall, the latter augmented by pneumoperitoneum or external counter-traction.

A major objective is to stop forward progress of the trocar as soon as it has gone through the abdominal wall (ie, within a few centimeters of entering the peritoneal cavity). The maneuver requires a balance of agonist muscles, which produce the forward thrust, and antagonist muscles, which stop it. Principles of human biomechanics<sup>18</sup> show that one's ability to control actions such as this is optimized if the muscles being used are midway between full contraction and full extension, if strong muscles are used at submaximal levels, and if the trocar is inserted slowly rather than quickly. The operating table should be at a height that allows the surgeon's shoulder to be slightly abducted.

Consequently, the technique for inserting the trocar should rely on force generated with the entire arm and shoulder, not just the wrist and forearm. In the most popular method, a right-handed surgeon stands on the supine patient's left side as the trocar is aimed toward the pelvic cavity (Fig. 2). Some surgeons prefer to stand on the opposite side and direct the trocar cephalad. The hand, arm, and shoulder should advance the trocar as a unit, giving it a twisting motion as it passes through the tissues. By going slowly and enlisting the strength of the entire upper extremity and shoulder, strong antagonist muscles are poised to halt further penetration when resistance from the abdominal wall suddenly ceases after the trocar enters the pneumoperitoneum.

Overshoot that allows the trocar tip to reach the retroperitoneum can be attributed to 1) the use of greater than the usual amount of force, which makes it more difficult to stop once the abdominal cavity is entered, and 2) laxity of the abdominal wall, which allows the abdominal wall to sag inward with pressure from the

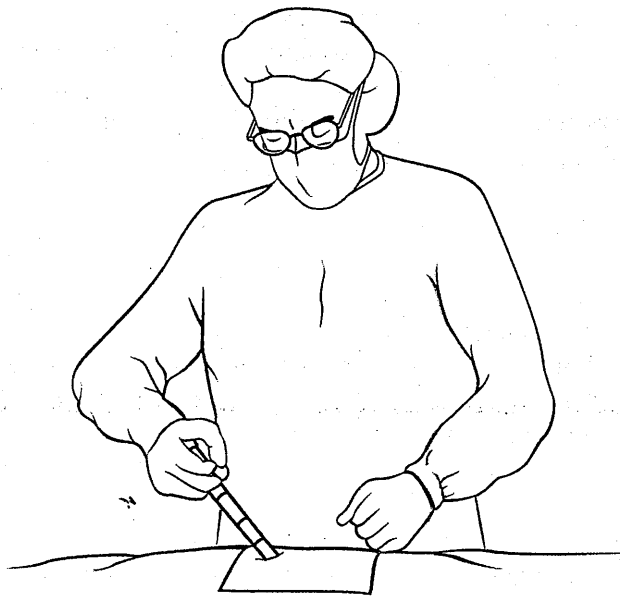


Figure 2. Technique for inserting a trocar.

trocar (bringing it closer to the retroperitoneal structures). Inserting the trocar perpendicular to the abdominal wall instead of at an angle fails to take advantage of the longer path available with the angled approach.

The bifurcation of the aorta is approximately at the level of the iliac crest. The abdominal wall is addressed at approximately a 45-degree angle, and the trocar should be kept to the midline plane. It should be aimed to miss the aorta and the iliac vessels no matter how deeply it penetrates.

Injury to retroperitoneal structures results from excessively deep entry of the trocar, an event that is under the control of the surgeon. Whether or not a safety shield is covering it, the tip of the trocar should never reach the retroperitoneal structures, where the most serious injuries occur (ie, to the aorta, vena cava, or their branches). The most common vascular injury in this review was to the common iliac artery or vein, and the largest group of fatal injuries (38%) involved the aorta or inferior vena cava.

Although cholecystectomy was the operation associated with the most deaths from vascular injuries (Fig. 1), this reflects only the relative frequency of this operation. Because the technique of trocar insertion does not vary appreciably among different laparoscopic operations, and the first trocar is usually placed in the midline, the risk of injury is largely independent of the specific operation.

Blunt, radially expanding trocars represent another

novel design that may have advantages with respect to safety. Initial reports are promising<sup>19</sup> but more data are needed before they can be compared with the cutting trocars.

### Conclusions

This study shows that safety-shielded and direct-view trocars cannot prevent serious visceral injuries. Vascular injuries are more likely to be fatal if they involve the aorta or inferior vena cava. An unrecognized bowel injury is highly lethal. A pneumoperitoneum or mechanical splinting of the abdominal wall should be used whenever trocars are inserted, and the axial force on the trocar should be controlled to avoid having the trocar tip come into contact with the retroperitoneum. Malfunction of a safety shield is rarely implicated as the cause of injury

**Acknowledgment:** We wish to thank Terry T Toyama for producing Fig. 2, and Laura Kemp for her help with downloading the data from the FDA web site.

### REFERENCES

1. Geers J, Holden C. Major vascular injury as a complication of laparoscopic surgery: a report of 3 cases and a review of the literature. *Am Surg* 1996;62:377-379.
2. Saville LE, Woods MS. Laparoscopy and major retroperitoneal vascular injuries. *Surg Endosc* 1995;9:1096-1100.
3. Wherry DC, Marohn MR, Malanoski MP, et al. An external audit of laparoscopic cholecystectomy in the steady state performed in medical treatment facilities of the department of defense. *Ann Surg* 1996;224:145-154.
4. Hashizume M, Sugimachi K. Needle and trocar injury during laparoscopic surgery in Japan. *Surg Endosc* 1997;11:1198-1201.
5. Bateman BG, Kolp LA, Hoegen K. Complications of laparoscopy—operative and diagnostic. *Fertil Steril* 1996;66:30-35.
6. MacCordick C, Lecurú F, Rizk E, et al. Morbidity in laparoscopic gynecological surgery. Results of a prospective single center study. *Surg Endosc* 1999;13:57-61.
7. Deziel DJ, Milikan KW, Economou SG, et al. Complications of laparoscopic cholecystectomy: a national survey of 4292 hospitals and an analysis of 77604 cases. *Am J Surg* 1992;165:9-14.
8. Yuzpe AA. Pneumoperitoneum needle and trocar injuries in laparoscopy. A survey on possible contributing factors and prevention. *J Reprod Med* 1990;35:485-490.
9. Kornfield EA, Sant GR, O'Leary MP. Minilaparotomy for laparoscopy: not a foolproof procedure. *J Endourol* 1994;8:353-355.
10. Sadeghi-Nejad H, Kavoussi LR, Peters CA. Bowel injury in open technique laparoscopic cannula placement. *Urology* 1994;43:559-560.
11. Woolcott R. The safety of laparoscopy performed by direct trocar insertion and carbon dioxide insufflation under vision. *Aust N Z J Obstet Gynaecol* 1997;37:216-219.

- Mettler L, Ibrahim M, Vinh VQ, Jonat W. Clinical experience with an optical access trocar in gynecological laparoscopy-pelviscopy. *J Soc Laparoendosc Surg* 1997;1:315-318.
13. Kaali SG, Barad DH, Merkatz IR. Comparison of visual and tactile localization of the trocar tip during abdominal entry. *J Am Assoc Gynecol Laparosc* 1994;2:75-77.
  14. Wolf JS Jr. Laparoscopic access with a visualising trocar. *Tech Urol* 1997;3:34-37.
  15. Yerdel MA, Karayalcin K, Koyuncu A, et al. Direct trocar insertion versus Verres needle insertion in laparoscopic cholecystectomy. *Am J Surg* 1999;177:247-249.
  16. Byron JW, Markenson G, Miyazawa K. A randomized comparison of Verres needle and direct trocar insertion for laparoscopy. *Surg Gynecol Obstet* 1993;177:259-262.
  17. Nezhat FR, Silfen SL, Evans D, Nezhat C. Comparison of direct insertion of disposable and standard reusable laparoscopic trocars and previous pneumoperitoneum with Verres Needle. *Obstet Gynecol* 1991;1978:148-150.
  18. Marras WS. Biomechanics of the human body. In: Salvendy G, ed. *Handbook of human factors and ergonomics*. 2nd edition. New York: Wiley-Interscience; 1997:233-267.
  19. Bhojrul S, Payne J, Steffes B, et al. A randomized prospective study of radially expanding trocars in laparoscopic surgery. *J Gastrointest Surg* 2000;4:392-397.