

CHAPTER 33

Salpingoscopy and Falloposcopy

Eric S. Surrey, Mark W. Surrey, and John F. Kerin

Significant technical advances have allowed reproductive surgeons to visualize the entire length of the fallopian tube lumen from the fimbriated end to the uterotubal ostium. Two microendoscopic techniques that aid in achieving this end shall be presented in this chapter: salpingoscopy and falloposcopy. Salpingoscopy allows for visualization of the ampulla, infundibulum, and fimbria through a transfibrial approach performed at laparoscopy. Falloposcopy affords visualization of the entire length of the fallopian tube by a nonincisional transcervical approach.

ANATOMY AND PHYSIOLOGY

The average length of the human fallopian tube is 8–13 cm (1). The intramural portion of the tube extends 1.5–2.0 cm from the uterotubal ostium. It is the narrowest segment measuring between 0.4 and 0.5 cm in diameter and has three distinct muscle layers: outer spiral, inner longitudinal, and intermediary circular. The mucosa contains a high degree of secretory elements with a greater proportion of ciliated cells than in the isthmus. The isthmus region extends from the cornua to the ampulla and measures 2–3 cm in length and 1–2 cm in diameter. The longitudinal muscle layer becomes more attenuated as it approaches the ampulla. On cross-section, the isthmus takes on a cruciate appearance. There is a relative dearth of ciliated cells. The normal ampulla represents the distal two thirds of the fallopian tube ex-

tending from the ampullary-isthmus junction to the infundibulum. The diameter widens dramatically to approximately 1 cm. The muscular layers become significantly attenuated with virtual loss of the longitudinal layers and extensive thinning of the middle circular layer. Secretory and ciliated cells are abundant in this region.

The fallopian tube represents a complex neuroendocrine organ. The lush folds within the ampulla, infundibulum, and fimbria serve as the sites for ovum capture, fertilization, and early embryo development. The time course of ovum transport in the human fallopian tube is approximately 80 hr, of which 72 are spent in the ampulla after rapidly traversing the distance from the fimbria (2). Ampullary embryo transport appears intimately related to the presence of an adequate number of cilia located on the mucosal ridges, although other factors play a role. The functioning muscularis and secretory activity of glands within the folds create a turbulent system. Secreted cytokines and growth factors may also be a factor in enhancing early embryo development and uterine receptivity. More proximally, the isthmus and intramural regions with a more distinctive muscularis and relative dearth of ciliated cells are characterized by rapid embryo transport, which may reflect the function of enhanced muscular contractility in this region.

PATHOPHYSIOLOGY

Distal tubal occlusion and hydrosalpinx formation primarily results from ascending or descending infection or a noninfectious inflammatory response (e.g., endometriosis, surgical adhesions). The pathophysiology of this disorder has been extensively reviewed elsewhere in this book. It had previously been assumed that the etiologies of proximal and distal tubal occlusion are identical. Re-

E. S. Surrey and M. W. Surrey: Center for Reproductive Medicine and Surgery, Beverly Hills, California 90210.

J. F. Kerin: Department of Obstetrics and Gynecology, Flinders University, Bedford Park, South Australia 5042.

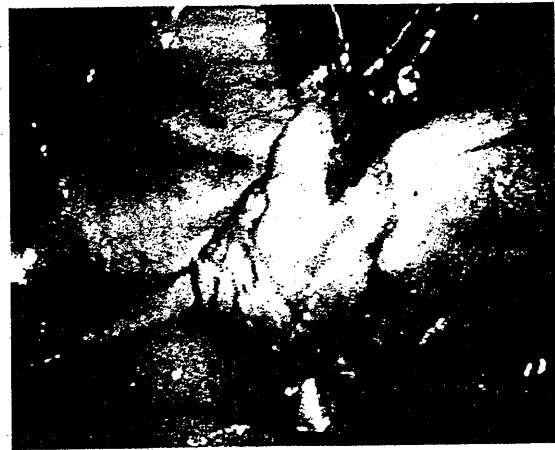
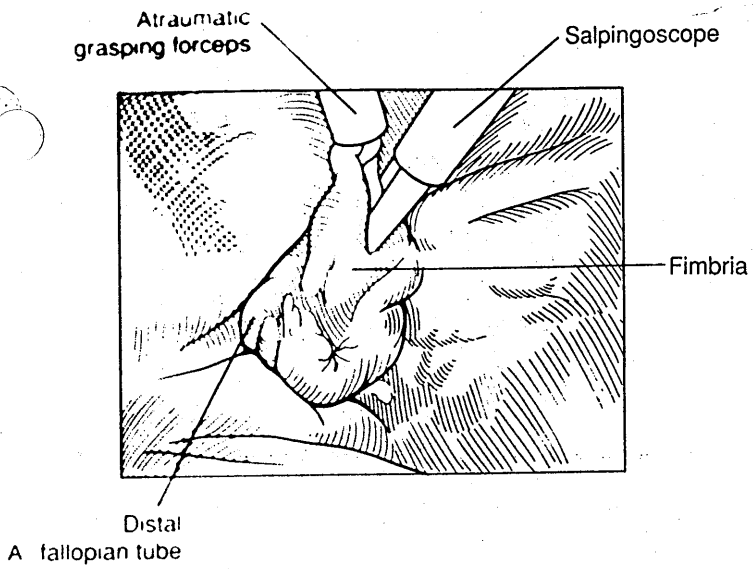


FIG. 2. A: Flexible salpingoscope introduced into fimbriated end of fallopian tube. The serosal surface has been grasped just proximal to the fimbria with atraumatic grasping forceps. **B:** Heparinized lactated Ringer's solution is infused through the accessory port of the salpingoscope as a distension medium.

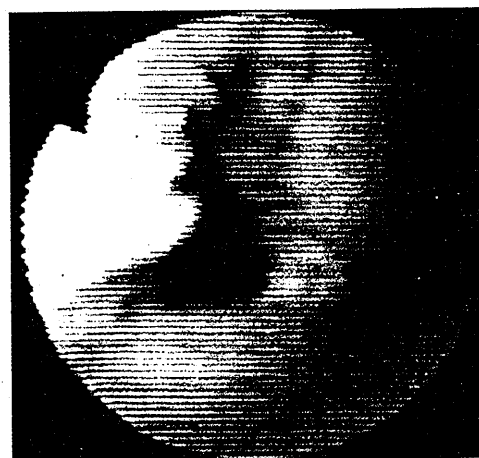
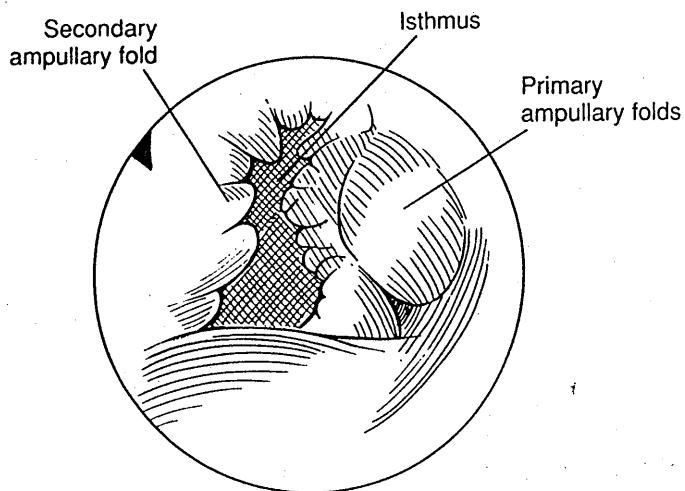


FIG. 3. Salpingoscopic view of the ampullary-isthmus junction. Note initiation of primary radial folds with rare secondary folds.

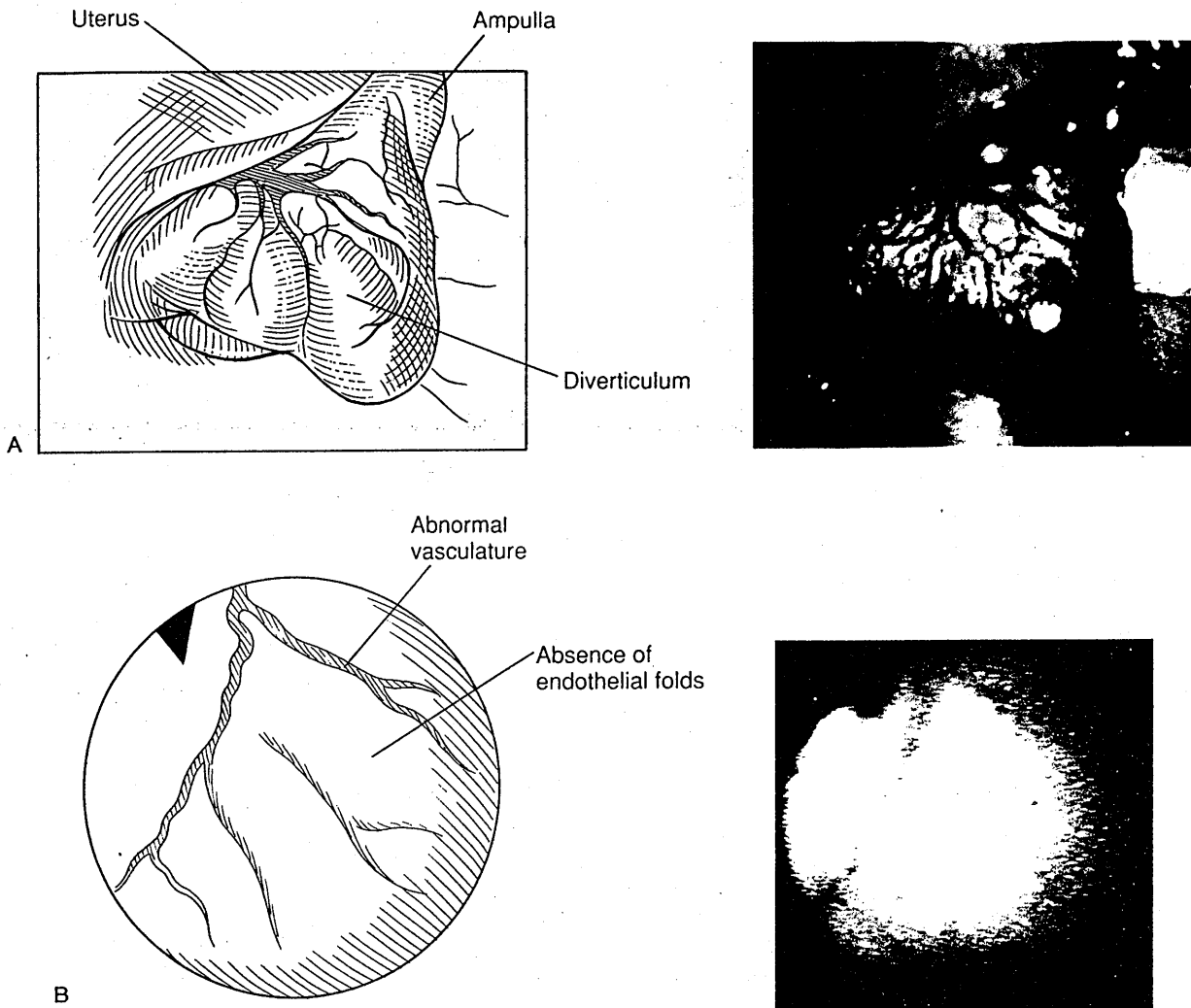


FIG. 6. A: Apparent diverticulum in distal ampullary region noted after distention during chromotubation in patient with unexplained infertility. Hysterosalpingogram and tubal appearance prior to chromotubation were normal. **B:** Salpingoscopic view of diverticulum described in Fig. 6A. Note complete absence of primary or secondary ampullary endothelial folds and abnormal vascular pattern.

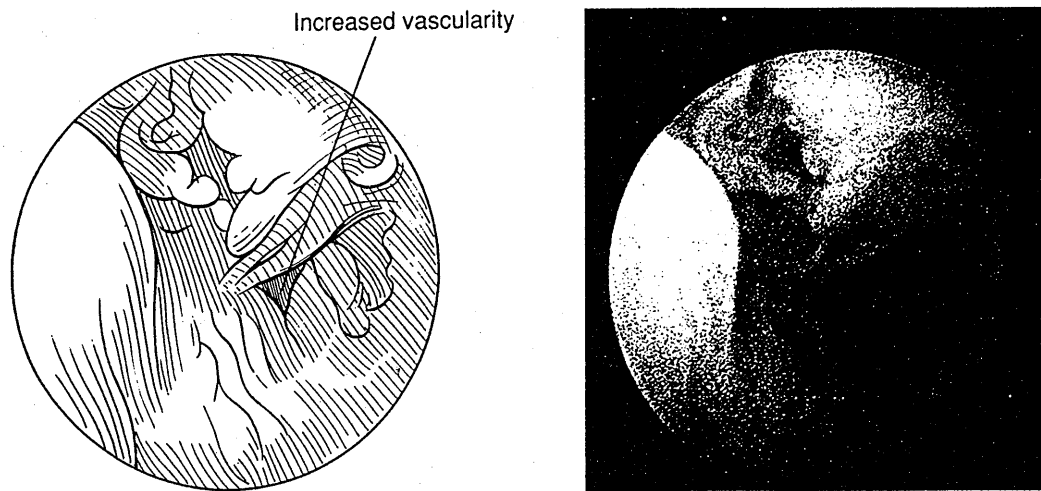
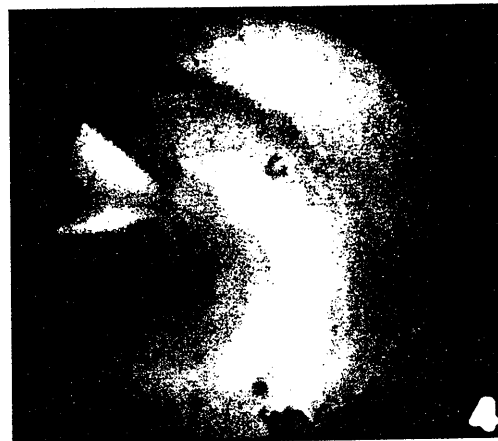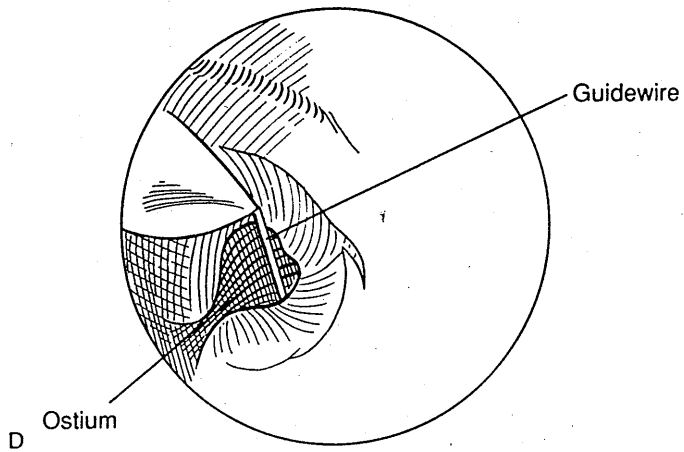
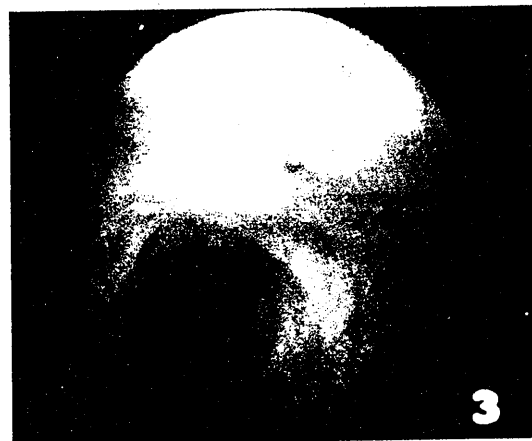
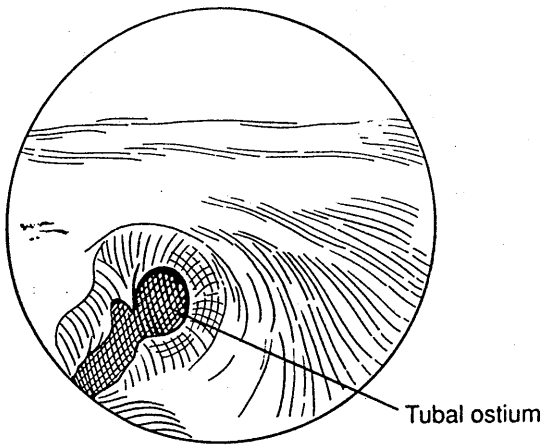
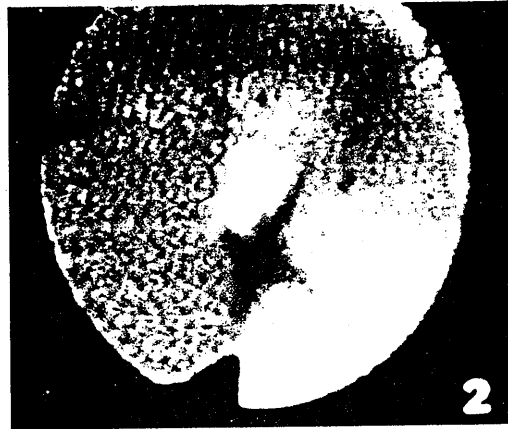
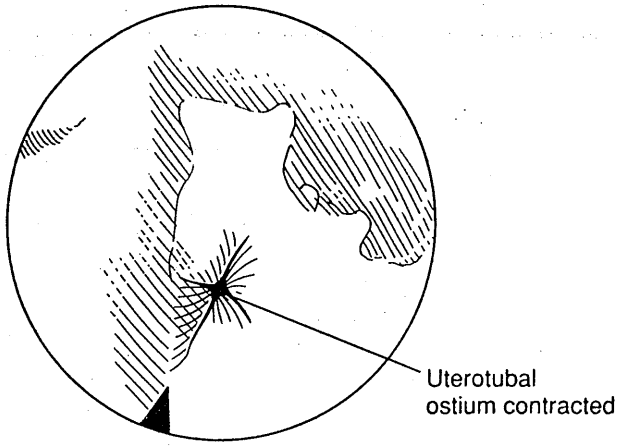
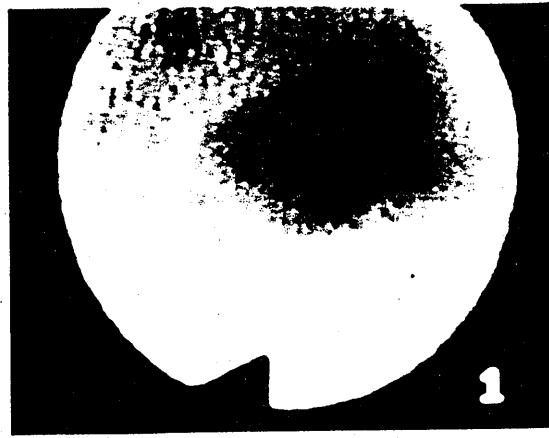
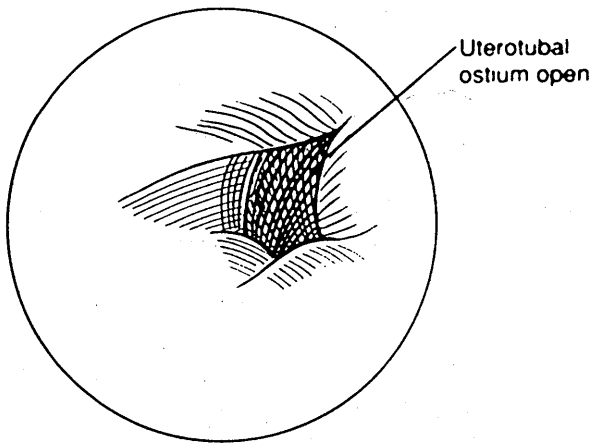


FIG. 7. Increased vascularity in patient with moderate tubal disease as viewed through the salpingoscope. (From ref. 14, with permission.)



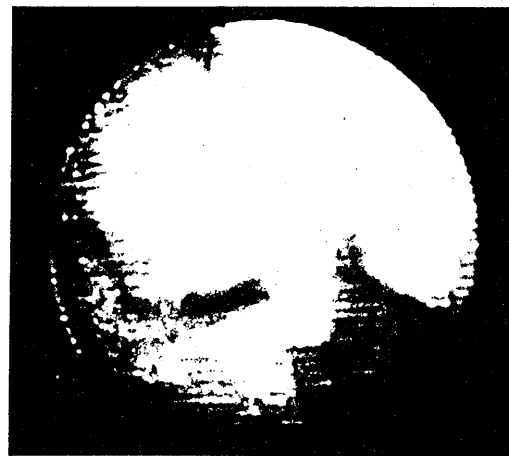
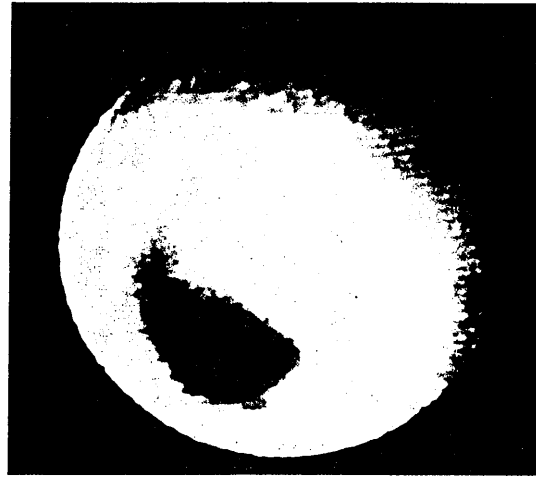
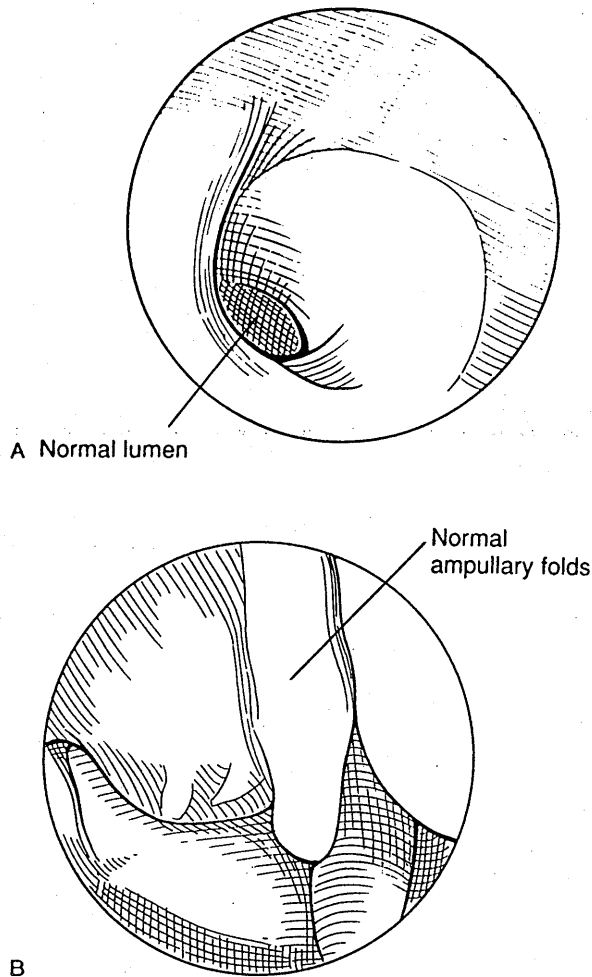


FIG. 13. A: Image of normal isthmus obtained with LEC fallopscopy system. B: Image of normal ampulla obtained with LEC fallopscopy system. (From ref. 22, with permission.)

Technical failure, defined by the inability to advance the falloposcope or to visualize the tubal lumen in the absence of detectable lesions, has been reported in only 8.5% of coaxial- and 13.4% of LEC-directed procedures (22,23).

Normal Anatomy and Pathologic Findings

The intramural portion of the oviduct is generally fairly straight in its course, but it may form an acute angle with the endometrial cavity. Its lining has several flattened folds. It is important to note that once emerging from the uterine wall the tube may bend in as much as a 60° angle. The normal isthmus is pink with four to six longitudinal folds. A falloposcopic view of this region is shown in Fig. 13A. The endotubal appearance of the more distal aspects of the fallopian tube have been de-

scribed above. An image of the normal ampulla obtained at fallopscopy with the LEC is shown in Fig. 13B. Although the wider salpingoscopes currently provide enhanced image resolution of this region, fallopscopy has the potential of being performed as an office procedure for circumstances in which laparoscopy would otherwise be unnecessary (24).

Endotubal lesions recognized at fallopscopy were initially described by Kerin and co-workers (25). Intraluminal adhesions and mucous plugs are often best detected after performance of selective chromotubation with dilute methylene blue dye (Fig. 14). Polyps protruding into the tubal lumen may present as incidental findings or represent an etiology of partial tubal occlusion (Fig. 15). Progressive stenosis leading to complete fibrotic obstruction has also been characterized (Fig. 16). Intraluminal diverticulae have been recognized in patients with classical findings of salpingitis isthmica nodosa at laparoscopy

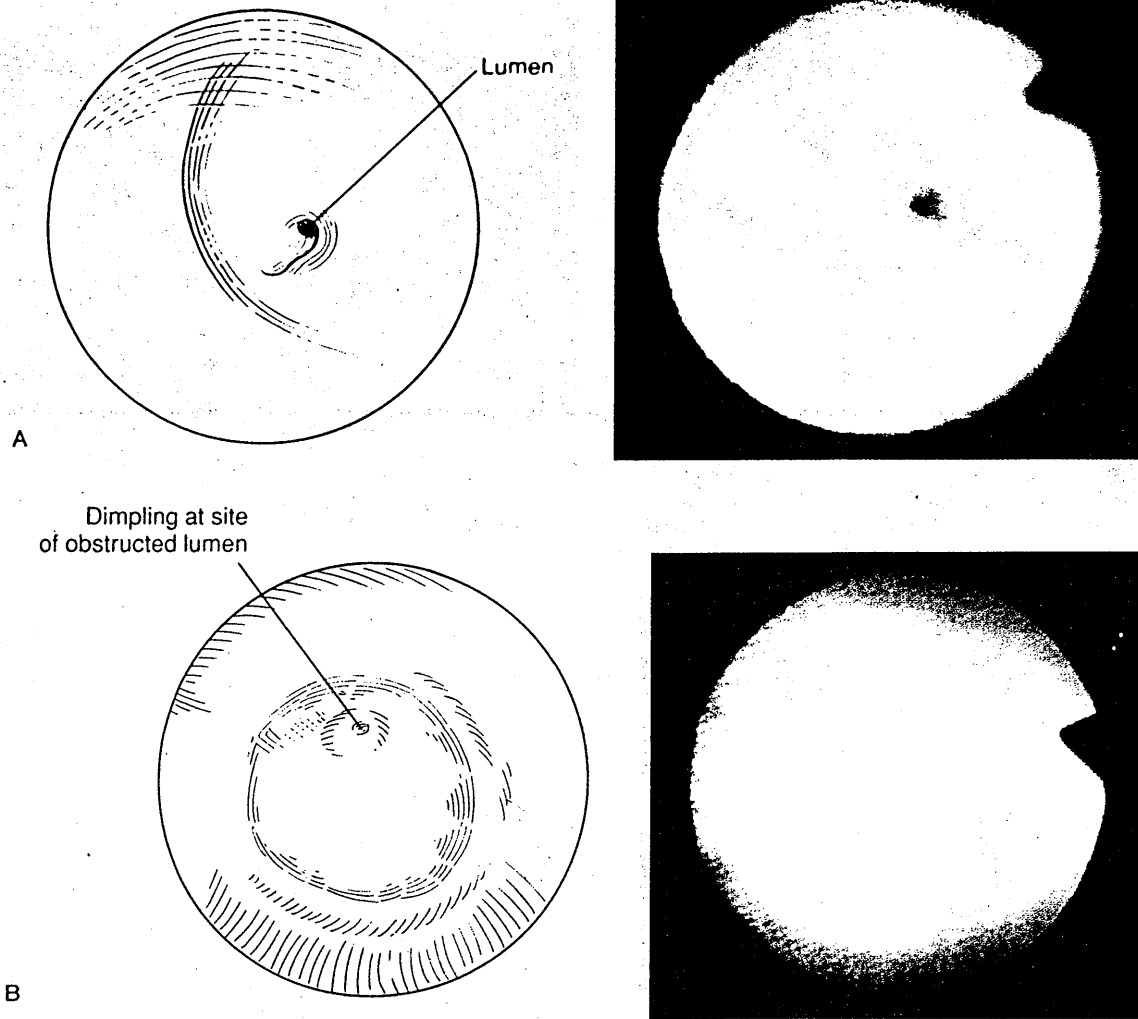


FIG. 16. A: Falloposcopic view of severe isthmic stenosis. B: View of complete fibrotic isthmic obstruction noted during coaxial falloposcopy. Note dimpling at site of obliterated lumen.

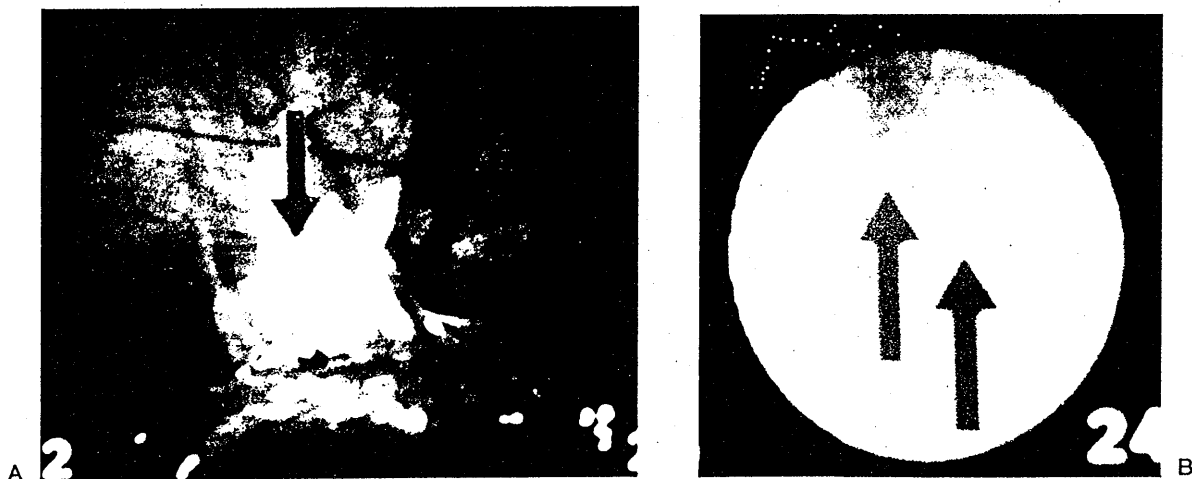


FIG. 17. A: Peritubal adhesions between fibrotic left isthmus and bladder peritoneum in patient with hysterosalpingogram findings compatible with salpingitis isthmica nodosa. B: View through falloposcope of lumen of the same tube demonstrating stenosis, fibrosis, and two diverticular openings from lumen (arrows) extending into muscularis. (From ref. 3, with permission.)

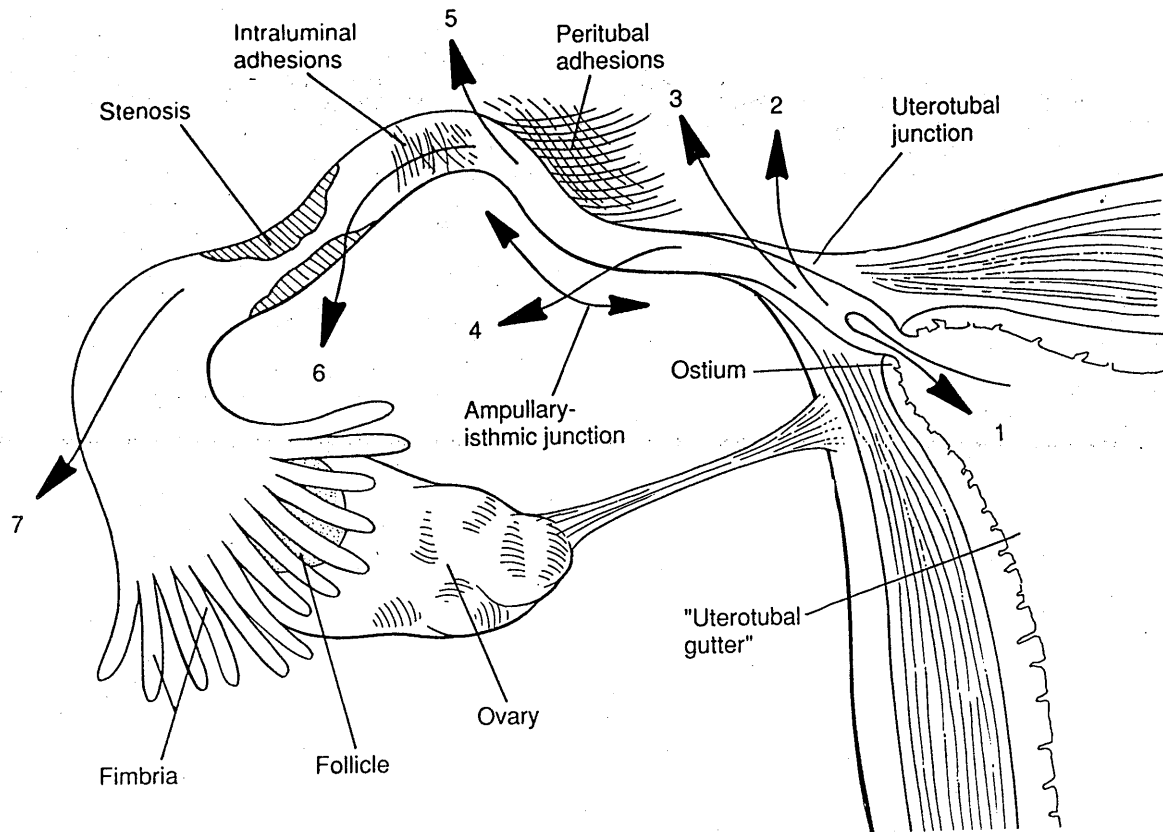


FIG. 19. Most vulnerable sites for perforation during tubal cannulation prior to falloposcopy. (From ref. 30, with permission.)

REFERENCES

- Hoffman JJ. Anatomy and physiology of the fallopian tube. In: Hunt RB, ed. *Atlas of female infertility surgery*. Chicago: Year Book Medical; 1986:3-10.
- Croxatto HB, Ortiz ME, Diaz S, Hess R, Balmaceda J, Croxatto HD. Studies on the duration of egg transport by the human oviduct. II. Ovum location at various intervals follow luteinizing hormone peak. *Am J Obstet Gynecol* 1978;132:629-634.
- Kerin JF, Williams DB, San Roman GA, Pearlstone AG, Grundfest WS, Surrey ES. Falloposcopic classification and treatment of fallopian tube lumen disease. *Fertil Steril* 1992;57:731-741.
- Letterie GS, Sakas EL. Histology of proximal tubal obstruction in cases of unsuccessful tubal canalization. *Fertil Steril* 1991;56:831-835.
- Sulak PJ, Letteire GS, Coddington CC, Hayslip CC, Woodward JE, Klein TA. Histology of proximal tubal obstruction. *Fertil Steril* 1987;48:437-441.
- Siegler AM. Evaluation of tubal factors in infertility and management of tubal obstruction. *Clin Obstet Gynecol* 1978;22:81.
- McComb PF, Rowe TC. Salpingitis isthmica nodosa: evidence it is a progressive disease. *Fertil Steril* 1989;51:542-545.
- Majmudar B, Henderson PH, Semple E. Salpingitis isthmica nodosa: a high risk factor for tubal pregnancy. *Obstet Gynecol* 1983;62:73-78.
- World Health Organization. Comparative trial of tubal insufflation, hysterosalpingography, and laparoscopy with dye hydrotubation for assessment of tubal patency. *Fertil Steril* 1986;46:1101-1107.
- Snowden EU, Jarrett JC II, Dawood MY. Comparison of diagnostic accuracy of laparoscopy, hysteroscopy, and hysterosalpingogram in evaluation of female fertility. *Fertil Steril* 1984;41:709-713.
- Gabos P. A comparison of hysterosalpingography and endoscopy in evaluation of tubal function in infertile women. *Fertil Steril* 1976;27:238-243.
- Gleicher N, Pratt D. Transvaginal procedures for infertility. In: Behrman SJ, Patton GW Jr, Holtz G, eds. *Progress in infertility*. Boston: Little Brown; 1994:225-248.
- Henry-Suchet J, Tesquier L, Pez JP, Loffredo U. Prognostic value of tuboscopy vs. hysterosalpingography before tuboplasty. *J Reprod Med* 1984;29:609-612.
- Herschlag A, Seifer DB, Carcangiu ML, Patton DL, Diamond MP, DeCherney AH. Salpingoscopy: light microscopic and electron microscopic correlations. *Obstet Gynecol* 1991;77:399-405.
- Cornier E. Ampullosalpingoscopy. In: Siegler AM, ed. *The fallopian tube: basic studies and clinical contributions*. White Plains, NY: Futura; 1986:383-390.
- Shapiro BS, Diamond MP, De Cherney AH. Salpingoscopy: an adjunctive technique for evaluation of the fallopian tube. *Fertil Steril* 1988;49:1076-1079.
- Puttemans P, Brosens I, Delattin P, Vasquez G, Boeckx W. Salpingoscopy versus hysterosalpingography in hydrosalpinges. *Hum Reprod* 1987;2:535-540.
- Henry-Suchet J, Loffredo V, Tesquier L, Pez JP. Endoscopy of the tube (tuboscopy): its prognostic value for tuboplasty. *Acta Eur Fertil* 1985;16:139-145.
- Surrey ES, Surrey MW. The role of transfibrial salpingoscopy in the management of distal tubal disease: correlation with traditional criterion. Program of the 42nd Annual Meeting of the Pacific Coast Fertility Society: April 20-24, 1994, (Abstract P-1).

20. Kerin J, Daykhovsky L, Grundfest W, Surrey E. Falloposcopy: a microendoscopic transvaginal technique for diagnosing and treating endotubal disease incorporating guide wire cannulation and direct balloon tuboplasty. *J Reprod Med* 1990;35:606-612.
21. Kerin J, Daykhovsky L, Segalowitz J, Surrey E, et al. Falloposcopy: a microendoscopic technique for visual exploration of the human fallopian tube from the uterotubal ostium to the fimbria using a transvaginal approach. *Fertil Steril* 1990;54:390-400.
22. Pearlstone AC, Surrey ES, Kerin JF. The linear everting catheter: a nonhysteroscopic, transvaginal technique for access and microendoscopy of the fallopian tube. *Fertil Steril* 1992;58:854-857.
23. Kerin JF, Surrey ES. Tubal surgery from the inside out: falloposcopy and balloon tuboplasty. *Clin Obstet Gynecol* 1992;35:299-312.
24. Scudamore IW, Dunphy BC, Cooke ID. Outpatient falloposcopy: intra-luminal imaging of the fallopian tube by trans-uterine fiberoptic endoscopy as an outpatient procedure. *Br J Obstet Gynecol* 1992;99:829-835.
25. Kerin JF, Surrey E, Daykhovsky L, Grundfest WS. Development and application of a falloposcope for transvaginal endoscopy of the fallopian tube. *J Laparosc Surg* 1990;1:47-56.
26. Thurmond AS. Selective salpingography and fallopian tube recanalization. *AJR* 1991;156:33-38.
27. Confino EC, Tur-Kaspa I, DeCherney A, et al. Transcervical balloon tuboplasty: a multicenter study. *JAMA* 1990;264:2079-2082.
28. Maroulis GB, Yeko TR. Treatment of cornual obstruction by transvaginal cannulation without hysteroscopy or fluoroscopy. *Fertil Steril* 1992;52:1136-1138.
29. Lisse K, Sydow P. Fallopian tube catheterization and recanalization under ultrasonic observation: a simplified technique to evaluate tubal patency and open proximally obstructed tubes. *Fertil Steril* 1991;56:198-201.
30. Kerin JF, Pearlstone A, Surrey ES. Cannulation of the fallopian tube and falloposcopy: difficulties and complications. In: Corfman RS, Diamond MP, DeCherney A, eds. *Complications of laparoscopy and hysteroscopy*. Boston: Blackwell Scientific; 1993:223-232.

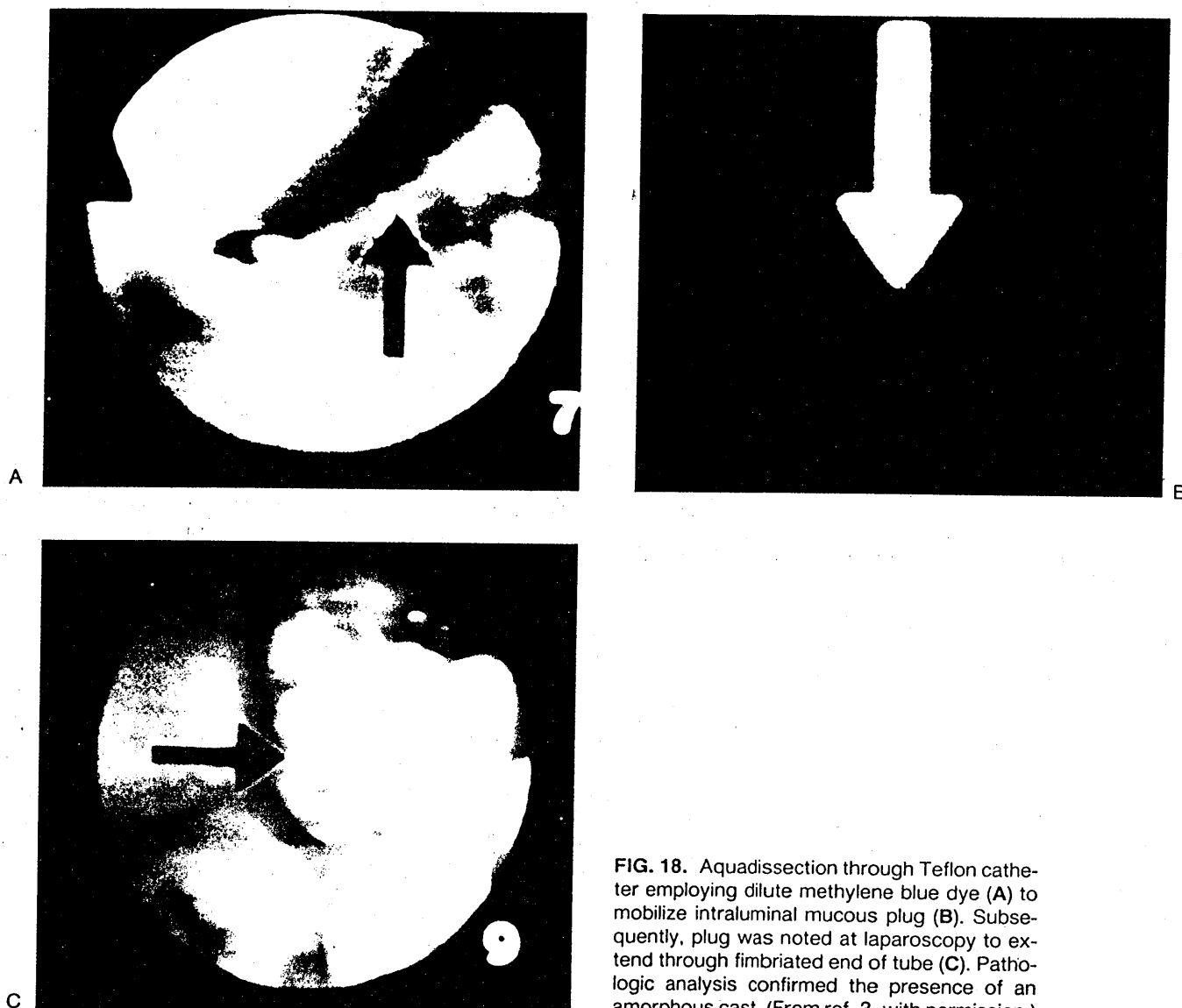


FIG. 18. Aquadissection through Teflon catheter employing dilute methylene blue dye (A) to mobilize intraluminal mucous plug (B). Subsequently, plug was noted at laparoscopy to extend through fimbriated end of tube (C). Pathologic analysis confirmed the presence of an amorphous cast. (From ref. 3, with permission.)

and then advanced until the obstruction is bypassed. The falloposcope is removed prior to passage of the balloon or wire and subsequently replaced both to confirm patency and to rule out intraluminal damage. In our initial report, moderate stenoses were successfully dilated in 39% (5 of 13) of cases, whereas moderate stenoses were dilated in 33% (4 of 12) of cases employing these techniques. However, no tubal patency could be achieved by these techniques in 11 cases of complete fibrotic obstruction (20,25).

Operative falloposcopy should be performed under laparoscopic guidance in an effort to prevent tubal perforation. Diagnostic falloposcopy does not require concomitant laparoscopy unless otherwise indicated. No significant complications have been reported in over 120 cases of diagnostic falloposcopy. Six perforations without sequelae have been described; all occurred in patients

with severe fibrotic occlusion in over 60 operative procedures (30). The most frequent sites for tubal perforation are diagrammed in Fig. 19. Peritubal adhesions, which kink the tube, intraluminal adhesions, and stenoses all predispose to perforation.

HIGHLIGHTS

Falloposcopy and salpingoscopy represent complementary, minimally invasive means of visualizing one of the last frontiers of the female reproductive system: the fallopian tube lumen. Falloposcopy has great promise for use as an office-based procedure. Both techniques allow reproductive surgeons to diagnose and create management strategies more appropriately for patients with suspected tubal disease and unexplained infertility.

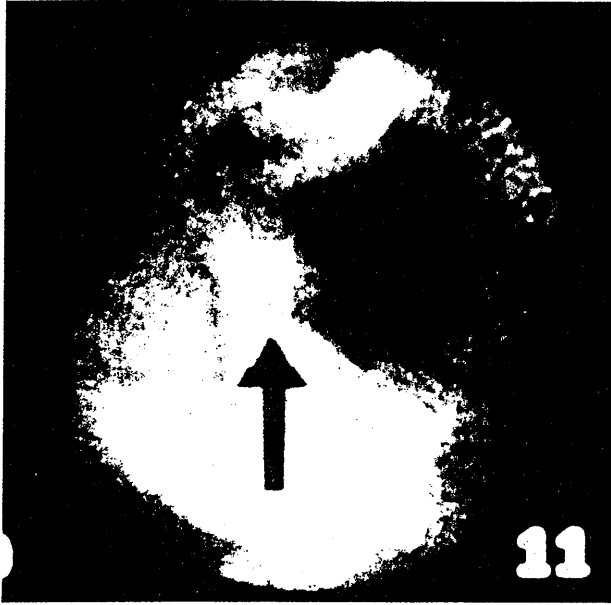


FIG. 14. Stringy intraluminal isthmic adhesions. These are nonobstructive but are coupled with devascularized atrophic epithelium. Hysterosalpingogram and laparoscopy were normal in patient with otherwise unexplained infertility. (From ref. 3, with permission.)

and hysterosalpingography (Fig. 17). A classification system based on such falloposcopic findings as epithelial pallor, vascularity, luminal narrowing, and adhesions has been presented (3). In one series in which 112 tubes were adequately visualized in patients with suspected

tubal disease, no disease was noted in 46% (23). Severe obstruction was noted in 25% of patients, none of whom had conceived within a year of surgery. Of 72 patients with mild-to-moderate disease, only 2 had conceived spontaneously a year postoperatively.

OPERATIVE FALLOSCOPY

Several minimally invasive approaches to proximal tubal occlusion with wire probes or balloons have been described. Investigators have achieved access to the fallopian tube employing tactile, sonographic, and fluoroscopic techniques (26–29). Unfortunately, these modalities do not allow for direct visualization of the cause of the occlusion. With the use of concomitant falloposcopy, the appropriate means for approaching proximal tubal obstruction may be selected based on identification of etiology. Intraluminal debris, mucous plugs, and filmy adhesions may be effectively managed by either aquadissection or gentle advancement of the flexible guidewire (Fig. 18). In our reported experience, aquadissection and/or guidewire cannulation was successfully used to lyse nonobstructive intraluminal adhesions in 60% (9 of 15) cases (20,25). Thicker adhesions, moderate stenoses, and intraluminal polyps may be effectively treated by gently advancing flexible dilation wires with up to 0.8 mm OD (Target Therapeutics; Cook Ob/Gyn). Thicker adhesions and narrower stenoses may also respond to the use of small balloon catheters (1.0 cm deflated, 2.5 cm inflated) (Target Therapeutics) (20,25). These balloons are passed to the point of obstruction, inflated, deflated,

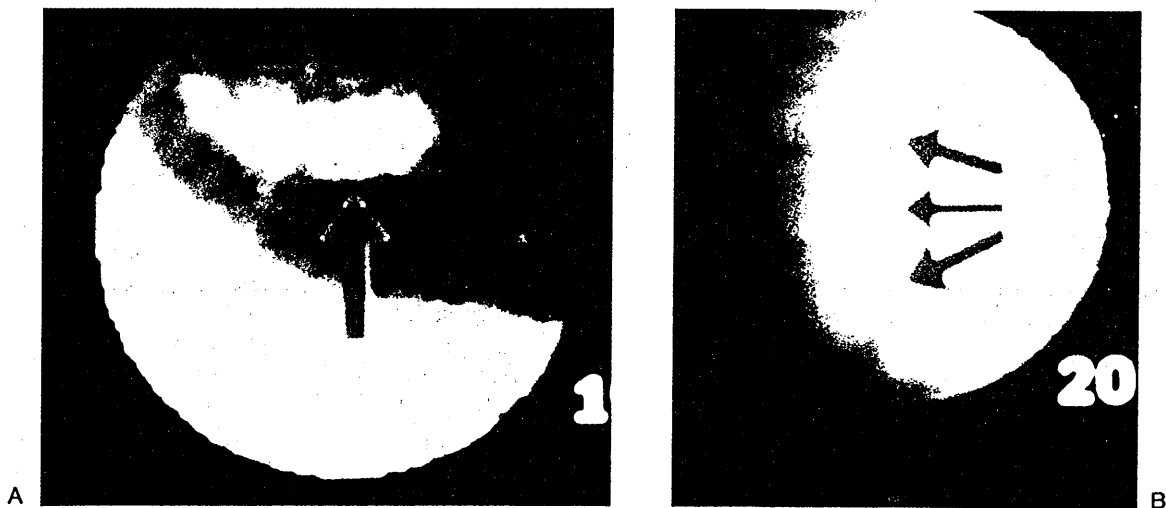


FIG. 15. **A:** Intraluminal polyp appreciated at the ampullary-isthmic junction noted during falloposcopy. This 1 × 0.3-mm simple polyp was an incidental finding in an otherwise normal tube. **B:** A broad-based papillary isthmic polyp noted at falloposcopy in a patient with primary infertility and normal hysterosalpingogram. (From ref. 3, with permission.)

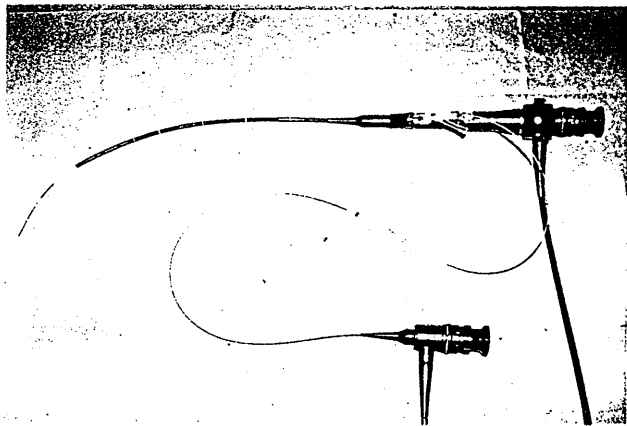


FIG. 10. Falloscope introduced through Y connector attached to over-the-wire Teflon catheter. Entire system has been previously thread through the operating channel of flexible hysteroscope.

The linear everting catheter (LEC) represents an alternative means of transcervically accessing the proximal portion of the fallopian tube for falloscopy (22). This system (Imagyn, Laguna Niguel, CA) is composed of outer and inner catheter bodies joined by a distal balloon, which everts as the inner body is advanced (Fig. 11). The balloon is pressurized, resulting in a slow eversion of the catheter tip (Fig. 12). This process allows the balloon to conform to the tortuous course of the tube and results in a reduction of lateral shear forces. The falloscope is introduced through the catheter lumen. Imaging is performed in a retrograde fashion as well.

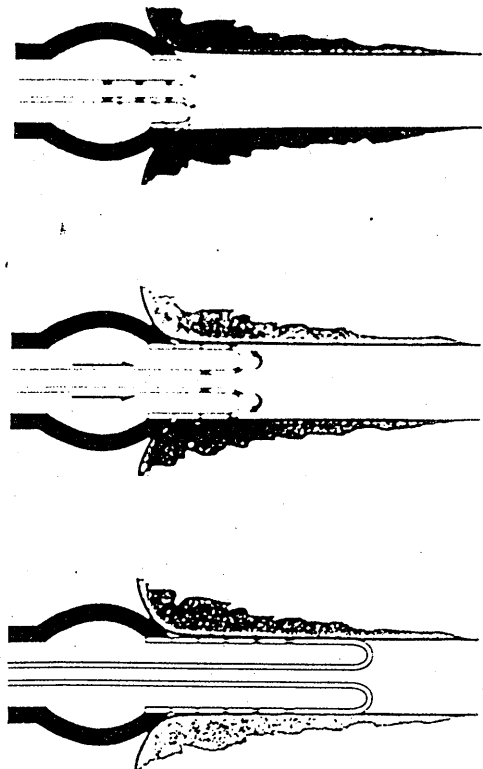


FIG. 12. Mechanism of eversion with LEC falloscopy system. (From ref. 22, with permission.)

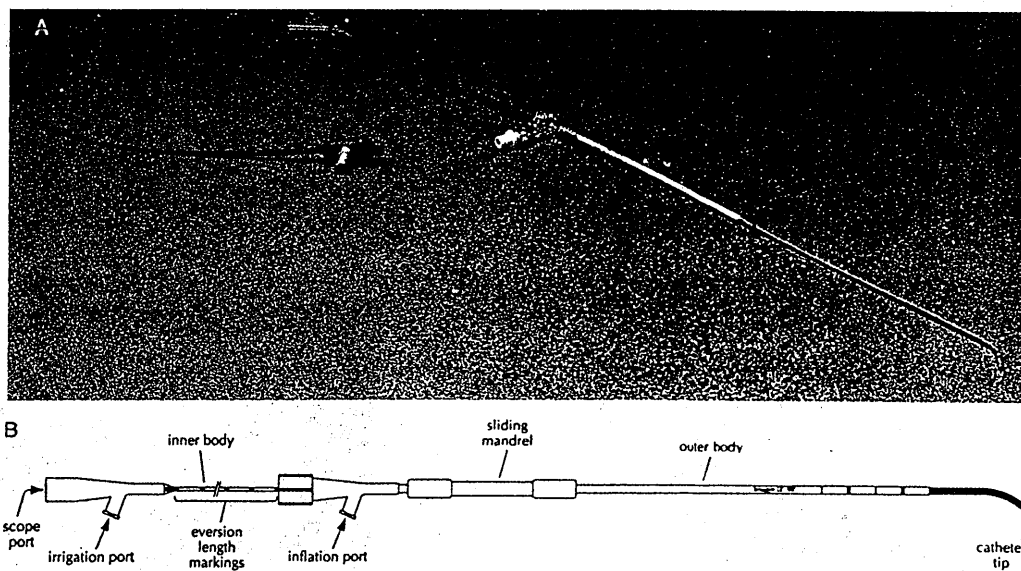


FIG. 11. Linear everting catheter. A: Actual photograph. B: Labeled diagram. (From ref. 22, with permission.)

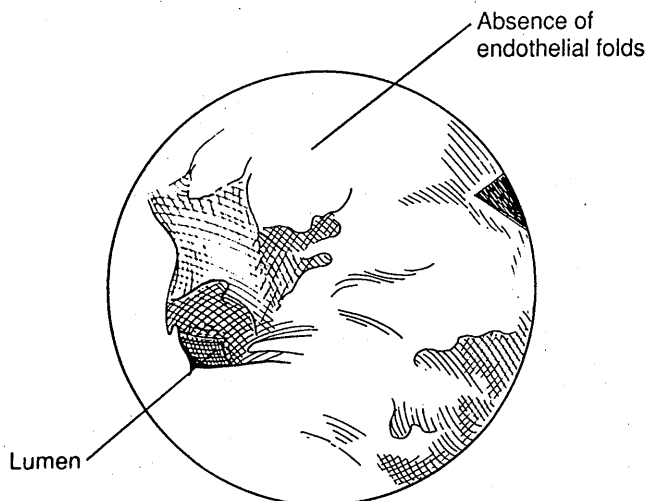
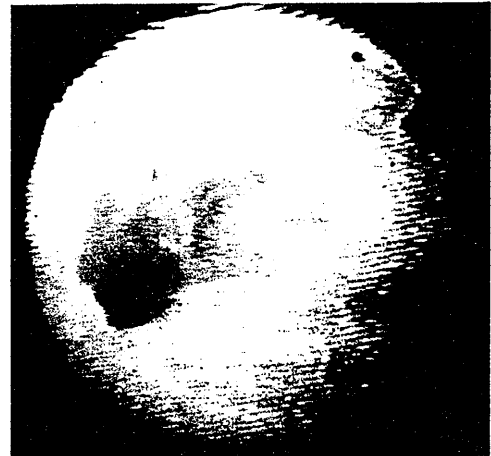


FIG. 8. Loss of endothelial folds and absence of normal vascular pattern in patient with hydrosalpinx as viewed through a flexible salpingoscope.



mesenteric border at which the tube is grasped can occur. This should resolve spontaneously.

FALLOPOSCOPY

Technique

Fallopscopy involves a transvaginal, transcervical approach to visualization of the tubal lumen. This can be performed with either a coaxial or a linear everting catheter delivery system. Kerin and colleagues first described the successful visualization of the entire length of the fallopian tube lumen by a coaxial technique in 1990 (20,21). This procedure is ideally performed during the midfollicular phase of the menstrual cycle after cessation of menses. Antibiotic prophylaxis should be administered.

A flexible hysteroscope with 1.5–3.5 mm OD (Olympus Corp., Lake Success, NY; Intramed Laboratories, San Diego, CA; Mitsubishi Cable Industries, Atami, Japan) is introduced into the uterine cavity under video monitoring. The uterine cavity is sounded but the cervix is not dilated. The hysteroscope is directed to within 1–2 mm of the uterotubal ostium. A Tuohy-Borst Y connector (Cook Ob-Gyn, Spencer, IN) is attached to the accessory port of the hysteroscope. Ringer's lactate is infused as a distension medium through one arm of the Y connector. A platinum-tipped, floppy guidewire coated with Teflon or stainless steel and with an OD of 0.3–0.8 mm

(Conceptus, Inc., San Carlos, CA; Target Therapeutics, San Jose, CA; Cook Ob-Gyn; Guidewire Medi-Tech, Watertown, NH) is then introduced through the other arm of the Y connector. It is advanced through the ostium under direct visualization for a distance of 15 cm or until resistance is met. To avoid perforation, the operator should not advance the wire past a point of resistance. Gentle torque may be required to advance the wire through the acute angles of the intramural portion of the fallopian tube. A flexible Teflon catheter with OD 1.2–1.3 mm (Conceptus Inc; Target Therapeutics; Cook Ob-Gyn) and a second Y connector attached to its proximal end is introduced over the wire for a similar length. Care should be taken to avoid manipulation of the uterotubal ostia during spasm to avoid bleeding and traumatic entry into the tube (Fig. 9). The guidewire is then withdrawn. A falloscope is then introduced through the straight arm of the Y connector. These devices vary from 1.0 to 1.5 cm in length and from 0.35 to 0.5 mm OD (Mitsubishi Cable; Olympus Corp.; Intramed Laboratories; Medical Dynamics, Englewood, CO). The surrounding catheter provides protection for the highly flexible and fragile falloscope (Fig. 10). A high-resolution camera chip is attached to a second video monitor. Ringer's lactate is infused with minimal pressure through the angled arm of the Y connector. Visualization is performed in a retrograde fashion while maintaining the falloscope just within the catheter lumen to avoid a white-out.

FIG. 9. View 1(A): Hysteroscopic view of the uteroutubal ostium in the relaxed state. View 2(B): Same ostium several seconds later during contraction. Note typical four-segment puckered appearance. View 3(C): Ideal distance and end-on view of ostium prior to guidewire insertion. View 4(D): Introduction of the guidewire along the intramural tubal lumen visualized hysteroscopically.

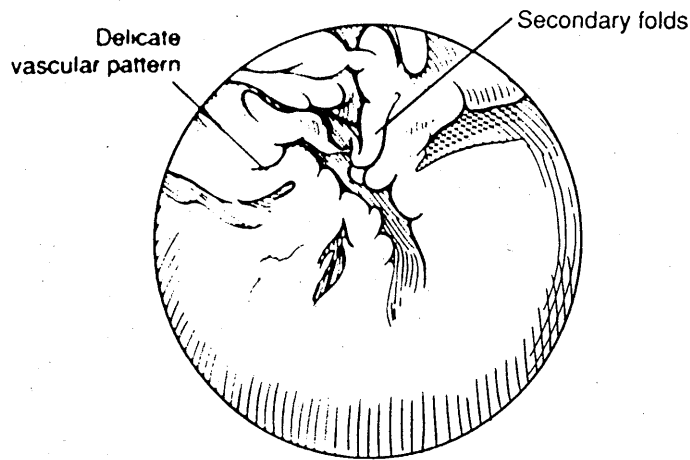


FIG. 4. Salpingoscopic view of distal ampulla-infundibulum. Note delicate vascular pattern and presence of extensive network of secondary folds.

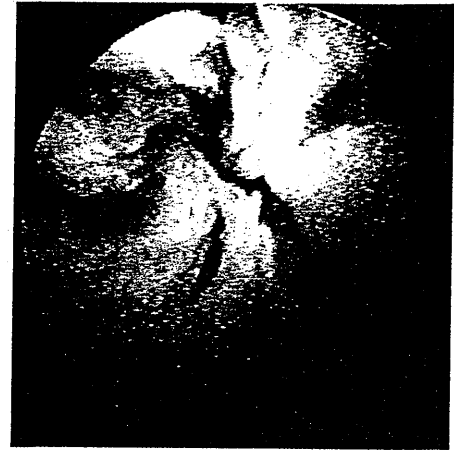
If a hydrosalpinx is encountered, access to the tubal lumen is obtained by creating a small terminal neosalpingostomy, which is made only large enough to accommodate the salpingoscope, using standard endoscopic techniques. This opening can serve as an initiating point for a more complete reconstructive procedure should the quality of the endothelial lining be acceptable. If this is not the case, the opening can easily be closed with coagulation or laser techniques or the tube can be removed entirely as appropriate.

Normal Anatomy and Pathologic Findings

As the surgeon progresses from the ampullary-isthmic junction into the ampulla, a series of radially arranged primary folds, approximately 4 mm in height can be viewed (Fig. 3). Secondary folds with delicate vascular patterns approximately 1 mm in height become more pronounced in the distal aspect of the tube. The number of folds increases toward the fimbriated end (Fig. 4).

A variety of abnormal findings have been reported. These include intraluminal synechiae (Fig. 5), stenoses (15), ampullary diverticulae (Fig. 6), inflammatory vascular patterns (Fig. 7), mucosal atrophy and loss of endothelial folds (Fig. 8). Several authors have attempted to classify the severity of luminal abnormalities detected at salpingoscopy (14,17).

The prognostic value of salpingoscopic findings in the management of distal tubal disease or unexplained infertility has been investigated. Henry-Suchet et al. reported that of 136 women who underwent a tuboplasty, intrauterine pregnancies were achieved only in those with at least one tube which was normal at salpingoscopy (18). Cornier described intraluminal adhesions in 37% of tubes visualized in patients with prior diagnosis of unex-



plained infertility with normal findings at laparoscopy and hysterosalpingogram (15). We recently reported that a relation between salpingoscopic findings and those noted at laparoscopy was high in patients with moderate to severe disease but poor in patients with laparoscopically staged mild disease (19).

Complications are extremely rare after salpingoscopy. A single case of postsalpingoscopy infection has been reported (13). Minimal bleeding at the point of the anti-

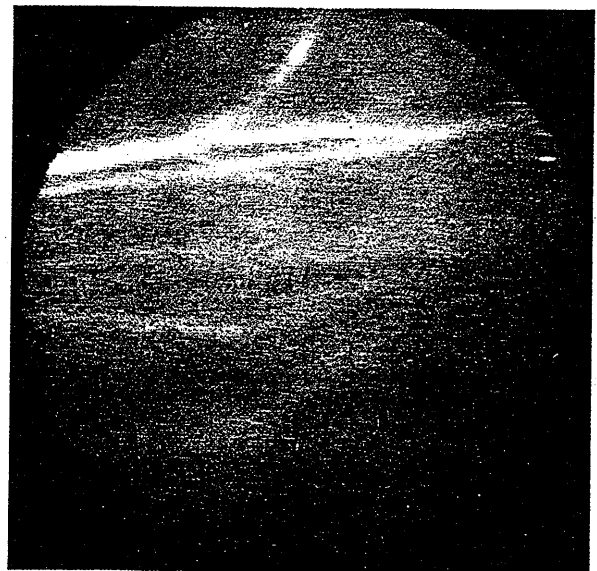

FIG. 5. Close-up view through salpingoscope of intraluminal adhesions in the midampullary region of the oviduct. This patient had a history of primary infertility and pelvic inflammatory disease. Hysterosalpingogram was normal and laparoscopy revealed minimal peritubal adhesions with normal-appearing fimbria.

cent studies have raised questions regarding this concept. Intraluminal adhesions, fibrosis, debris, polyps, mucous plugs, and endometriosis have been described as causes of proximal obstruction (3-6). Sulak and co-workers reported pathologic findings in 18 patients who underwent resection and reconstruction of proximal tubal segments thought to be obstructed based on hysterosalpingogram and laparoscopic chromotubation (5). No occlusion was noted in 11 patients, whereas in 6 patients an amorphous material compatible with a mucous plug was noted.

Salpingitis isthmica nodosa (SIN), a disorder uniquely limited to the isthmic region, is characterized by nodular thickening, which may contain glandular elements. Multiple diverticulae lined by tubal epithelium, which penetrate the muscularis and are in communication with the tubal lumen, are pathognomonic of SIN. Inflammatory cells are rarely present, which calls into question the likelihood of an infectious etiology. This disorder appears to be progressive and is associated with proximal occlusion and an increased incidence of tubal pregnancy (7,8).

Hysterosalpingography, laparoscopy, and hysteroscopy have been the traditional means for assessing the fallopian tube. Correlation between findings achieved with these modalities has been variable (9-11). The diagnosis of proximal tubal occlusion can also be confused by tubal spasm, which may provide a false-positive finding. Others would suggest that this finding may be associated with intrinsic tubal abnormalities and lower pregnancy rates (12). Needless to say, these techniques primarily afford information regarding tubal patency, degree of dilation, and peritubal disease. Direct visualization of the tubal lumen and endothelial lining cannot be achieved.

SALPINGOSCOPY

Technique

Salpingoscopy affords visualization of the oviductal lumen from the ampullary-isthmic junction to the fimbria. The salpingoscope is introduced transimbrically at the time of laparoscopy or laparotomy. Both flexible (Olympus Corp., Lake Success, NY) and rigid (Karl Storz, Culver City, CA) salpingoscopes with outer diameters (OD) of 1.5-2.8 mm have been employed (13-16) (Fig. 1). The size of these instruments prevents direct access to the isthmic and intramural segments. Flexible salpingoscopes are less traumatic and can more closely approach the ampullary-isthmic junction, whereas rigid endoscopes afford greater image quality.

The salpingoscope is introduced into the peritoneal cavity through a 3-mm reducer placed through an accessory trocar during laparoscopy. The fimbriated end of the tube is stabilized with atraumatic grasping forceps (Fig. 2A). The salpingoscope is advanced gently until resistance is reached. In the absence of obstruction, this should be at the point of the ampullary-isthmic junction. Heparinized Ringer's lactate solution is gently infused by a hand-held syringe through extension tubing connected to the irrigating channel of the salpingoscope (Fig. 2B). The use of carbon dioxide as a distention medium may hamper adequate visualization by flattening ampullary folds. The endothelial lining and tubal lumen are visualized in a retrograde fashion as the salpingoscope is slowly withdrawn. A separate standard camera chip, light source, and video monitor are employed. The procedure is performed after prophylactic antibiotics have been administered.

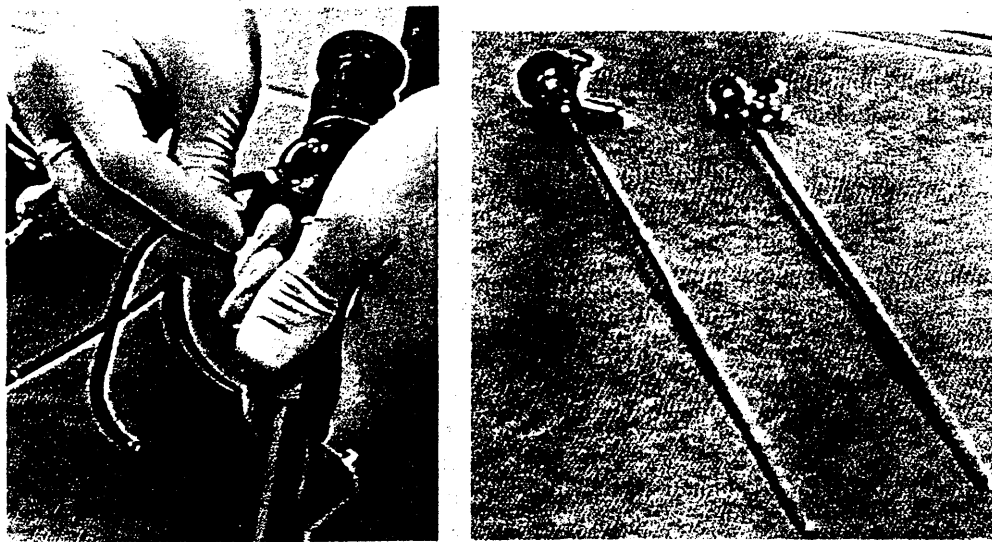


FIG. 1. A: Flexible salpingoscope (Olympus Corp., Lake Success, NY). B: Rigid salpingoscope (left) and sheath (right) (Karl Storz, Culver City, CA).