

Operative Laparoscopy (Minimally Invasive Surgery): State of the Art

CAMRAN NEZHAT, M.D.,¹ FARR NEZHAT, M.D.,¹ and CEANA NEZHAT, M.D.³

ABSTRACT

In any body cavity, endoscopic surgery is possible and usually preferable. Advantages include better exposure, magnification, and operating very close to the affected tissue. We demonstrate some of the past, present, and future of laparoscopy. (J GYNECOL SURG 8:111, 1992)

INTRODUCTION

THE FIRST ATTEMPT AT ENDOSCOPY was by Philip Bozzini of Italy in 1805, using a tube and a candle. Since that time, the instrumentation for laparoscopy has developed at an acceptable rate, although the applications lagged. Laparoscopy was moderately successful in Europe during the first half of the twentieth century.¹ After Jacobaeus of Sweden first induced pneumoperitoneum and placed a Nitze cystoscope into the peritoneal cavity (1910), the technique was applied to diagnostic and simple sterilization procedures by Kalk (Germany) and by Ruddock and Hope (United States) in the 1930s.¹ Although the reported results were promising, the procedure was not accepted in the United States. The next significant developments occurred in the 1950s. These were cold light (Fourestier, Gladu, and Valmiere) and fiberoptics (Kampany and Hopkins). In the late 1940s, Raoul Palmer of France was the main promoter of laparoscopy in gynecology. He reported the first human tubal fulguration in 1962.¹

With the groundwork for operative laparoscopy established, the next logical progression would seem to have been a gradual increase in the application to various types of pelvic and abdominal surgery. Instead, the laparoscope received limited use as a diagnostic tool.

The advantages of this instrument were diminished by three serious drawbacks. First, the surgeon had to work crouched over the patient and had to peer with one eye through the scope. Visibility was limited, the position was uncomfortable, and the surgeon's back was easily fatigued. Second, the rest of the surgical team was unable to view the procedure and, as a result, was prevented from anticipating the surgeon's needs. Third, the auxiliary instruments were not available to perform procedures more complicated than tubal ligation.

Victor Gomel¹ began reporting the merits and safety of operative laparoscopy in the early 1970s despite these limitations. He successfully performed a number of procedures, including salpingo-ovariolysis, salpingo-oophorectomy, fimbrioplasty, and management of ectopic pregnancy. In 1977, he reported his experience with salpingostomy in a small series of patients.²

At the same time, Kurt Semm headed the German-based Kiel School's development of instruments for use in operative laparoscopy, particularly fertility-enhancing procedures.³ In 1971, John Leventhal et al. (Boston, MA) reported the first laparoscopic removal of an intraabdominally displaced intrauterine contraceptive device following perforation.⁴ Bruhat, Manhes, and their colleagues contributed significantly by reporting their experience in the endoscopic management of ectopic pregnancy.⁵

¹Department of Obstetrics and Gynecology, Mercer University School of Medicine, Macon, Georgia.

²Department of Obstetrics and Gynecology, Ravens Wood Hospital, Chicago, Illinois.

³Center for Special Pelvic Surgery, Atlanta, Georgia.

Gomel, Bruhat, Semm, and others significantly contributed to this new technique during the 1970s, but operative laparoscopy was not integrated into the operative arena. It was performed and promoted by a limited group of surgeons and was not accepted by the medical community at large.

As laparoscopy stagnated, another medical breakthrough was evolving. The CO₂ laser, developed by Patel in 1964, was used in experimental surgery the following year. The high-tech concept of the laser gained public attention. Through lay publications, attention was focused on this new surgical tool. Its development continued until the late 1970s and early 1980s, when it was used in conjunction with the laparoscope. Bruhat et al.⁶ and Tadir et al.⁷ were among the first to report laser laparoscopy, using the second puncture and a joystick arrangement, respectively. The CO₂ laser using a fiber for delivery rather than a beam has been used by Baggish et al.^{8,9} Other fiber lasers, including the YAG,^{10,11} KTP-532,^{11,12} and argon,^{11,13} were used with the laparoscope to treat various pelvic disorders, with acceptable results. However, these lasers did not become popular with gynecologists, who continued to use primarily the CO₂ laser. Unfortunately, laser laparoscopy was still subject to the earlier mentioned limitations and not frequently used. In 1972, the American Association of Gynecologic Laparoscopists was established, and since that time, has played an important role in advancing operative laparoscopy.

In the late 1970s, several groups, including us, experimented with a video camera attached to the eyepiece of the scope in human and animal laboratories.¹⁴⁻¹⁶ The camera magnified the image and projected it onto monitors in the operating room. The major disadvantages of the laparoscope were eliminated, but the early cameras were cumbersome, and the first videolaparoscopic surgeries on humans were difficult because of the cameras' weight, inadequate light source, and poor resolution. As a result, its usage was not recommended and was even criticized by some. However, the senior author persisted in using and promulgating videolaparoscopy. In the early 1980s, equipment companies began to recognize the potential market for a miniature video camera and produced lighter versions with higher resolution and better light sources. With these final modifications, all the elements were in place by 1983-1984 for a revolution in abdominal and pelvic surgery.¹⁷

At the combined annual meetings of the American Fertility Society and Canadian Fertility and Andrology Society in November, 1986, the senior author presented the benefits of videolaparoscopy and the results of over 600 endometriosis surgeries performed using this technique.¹⁷ Using the more refined cameras combined with the CO₂ laser and laparoscope, we successfully performed laparoscopic procedures on over 1000 patients, including those with extensive endometriosis.¹⁸ Through the publication of both case reports and results of detailed studies, as well as national and international meetings, we have promulgated the use of videolaparoscopy in abdominal surgery (benign and malignant pathology),¹⁹⁻²⁴ gastroenterology,^{25,26} and urology.²⁷ Awareness of the technique was finally created when patients recommended the procedure to acquaintances. Media attention^{28,29,30} and word-of-mouth made operative laparoscopy one of the first truly consumer-driven medical advances. Unfortunately, over the last few years, it has become an easily marketable commodity and a source of heavy profit for some instrument companies. Laparoscopy has become more of an industry than a patient-driven advance.

A rapid increase has been witnessed in both the applications of operative laparoscopy and the number of surgeons who are learning this technique. Operative videolaparoscopy offers several benefits over an open procedure. First, pelvic and abdominal anatomy are magnified by the video camera and scope, allowing the surgeon to perform microsurgical procedures. Second, the pressure created by pneumoperitoneum decreases bleeding and provides a cleaner operating field. Third, such areas as the upper abdomen, posterior cul-de-sac, and posterior aspect of the broad ligaments may be more thoroughly evaluated, and with technological advances, such as the development of the CO₂ laser, disease may be treated more precisely and, possibly, with a greater margin of safety. Fourth, operative laparoscopy produces fewer *de novo* adhesions^{31,32} and requires a shorter recovery period. Finally, when performed by a trained and experienced surgeon, the occurrences of intraoperative and postoperative complications and morbidity, such as small bowel ileus and infection, are fewer than with laparotomy. An added benefit of the addition of video is the permanent record created by taping the procedure, which may be used for future reference. This tape can be used to demonstrate techniques to other physicians, explain a procedure to a patient, review a patient's condition should further treatment become necessary, or provide information for research.

PREPARATION FOR LAPAROSCOPY

To prepare a patient for operative laparoscopy, the surgeon should follow a protocol similar to that for laparotomy, including thorough clinical and laboratory evaluation. Pelvic ultrasound and, in selected cases, hysterosalpingogram are recommended to evaluate uterine and adnexal abnormality. Additionally, the

procedure is explained to the patient, and proper consent is obtained. The evening before surgery, patients with more advanced disease or previous laparotomy are given a bowel preparation consisting of 4 L polyethylene glycol-3350 (Go-LYTELY, Braintree Laboratories, Braintree, MA) and take 1 g metronidazole (Flagyl, G.D. Searle, Chicago, IL) at 11:00 PM. One gram of cefoxitin (Mefoxin, Merck, Sharp and Dohme, West Point, PA) is administered prophylactically, both preoperatively and postoperatively.

The room setup and trocar placement have been described in detail before.^{33,34} Videolaparoscopy is performed under general endotracheal anesthesia, with the patient placed in a modified dorsolithotomy and Trendelenburg position.

The authors recommend identifying sensitive structures in the pelvic and abdominal cavities, such as the bowel, ureters, and major blood vessels. When the procedure is complete, the patient should be placed in a reverse Trendelenburg position to facilitate the evacuation of any fluid in the upper abdomen. The pelvic cavity should be inspected as thoroughly as possible, with careful attention given to all surgical sites to ensure complete hemostasis.²²

As a final note, we make frequent reference to the CO₂ laser as a cutting modality. This is a personal preference. Scissors, electro-surgical devices, and fiber lasers are effective and appropriate when cutting is necessary.

APPENDECTOMY

During laparoscopic treatment of diverse pelvic pathologic conditions, appendectomy is often performed.²⁰ We use the following technique to remove the appendix when indicated.

The current procedure evolved from efforts initiated in 1983 using video-augmented instrumentation at hand to develop optimal techniques for laparoscopic surgery, including appendectomy. The trocar punctures allow the introduction of ancillary instruments, such as grasping forceps, Endoloop suture applicators, suction-irrigator probe (American Hydrosurgical Instruments, Delray Beach, FL), and bipolar electrocoagulator (Fig. 1). Hemostasis is accomplished with the bipolar electrocoagulator.

Appendectomy may be a primary procedure or may be performed concomitantly with other pelvic or abdominal surgeries. The incidental finding of appendiceal endometriosis or other appendiceal pathology during routine gynecologic cases, and patients' frequent desire for appendectomy at the time of gynecologic surgery warrant a thorough knowledge of appendectomy technique by gynecologic surgeons. As it carries the danger of contamination from bowel contents, appendectomy is usually performed after all other dissection and manipulation is completed.

With the surgeon standing at the patient's left side, preparation for appendectomy includes inserting grasping forceps through the lower right quadrant trocar sleeve and passing the bipolar electrocoagulator and suction-irrigator probe through the midline and lower left quadrant punctures, respectively. Next, with the video laparoscope system in the umbilical channel, the appendix is located. Subsequently, a direct lens coupler is attached (Coherent, Palo Alto, CA) to connect the CO₂ laser. The CO₂ laser beam is used through the operating channel of the laparoscope as a long knife. The appendix is mobilized and examined following lysis of periappendiceal or pericecal adhesions as necessary, proceeding carefully in case of attachment to the lateral pelvic wall or retrocecal appendix. The bipolar electrocoagulator and the CO₂ laser (Coherent) are used sequentially to coagulate and cut the mesoappendix 0.2–0.5 cm from the ileocecal area (Fig. 2). When using the bipolar electrocoagulator in this area, caution should be exercised to prevent thermal damage to the cecum. Additionally, a backstop is required when using the CO₂ laser to avoid injury to the major blood vessels in this area (external iliac artery and vein).

At this point, the bipolar electrocoagulator is withdrawn, and the Endoloop applicator (Ethicon, Somerville, NJ) is inserted through the suprapubic midline puncture. Two chromic Endoloop sutures (Ethicon) or polydioxanone sutures (Ethicon) are passed over the base of the appendix 2–5 mm from the cecum and then tied, one on top of the other. Both suture ends are cut with the CO₂ laser or scissors. A third Endoloop suture is applied < 1 cm distal to the other sutures and then cut long, leaving a 15 cm tail to facilitate retrieval should the appendix inadvertently fall into the pelvic well (Fig. 3). Using the CO₂ laser, the appendix is cut between the second and third sutures placed. Luminal portions of the appendiceal stump and the removed appendix are seared with the CO₂ laser, and the tissues are copiously irrigated with lactated Ringer's solution (Baxter Healthcare, Deerfield, IL).

The appendix is removed from the abdomen with a long grasping forceps passed through the operating channel of the laparoscope, suprapubically with the short grasper or with an Endopouch tissue removal bag (Ethicon). If appropriate, an appendix extractor may be placed via the sleeve of a 10 mm trocar, replacing the

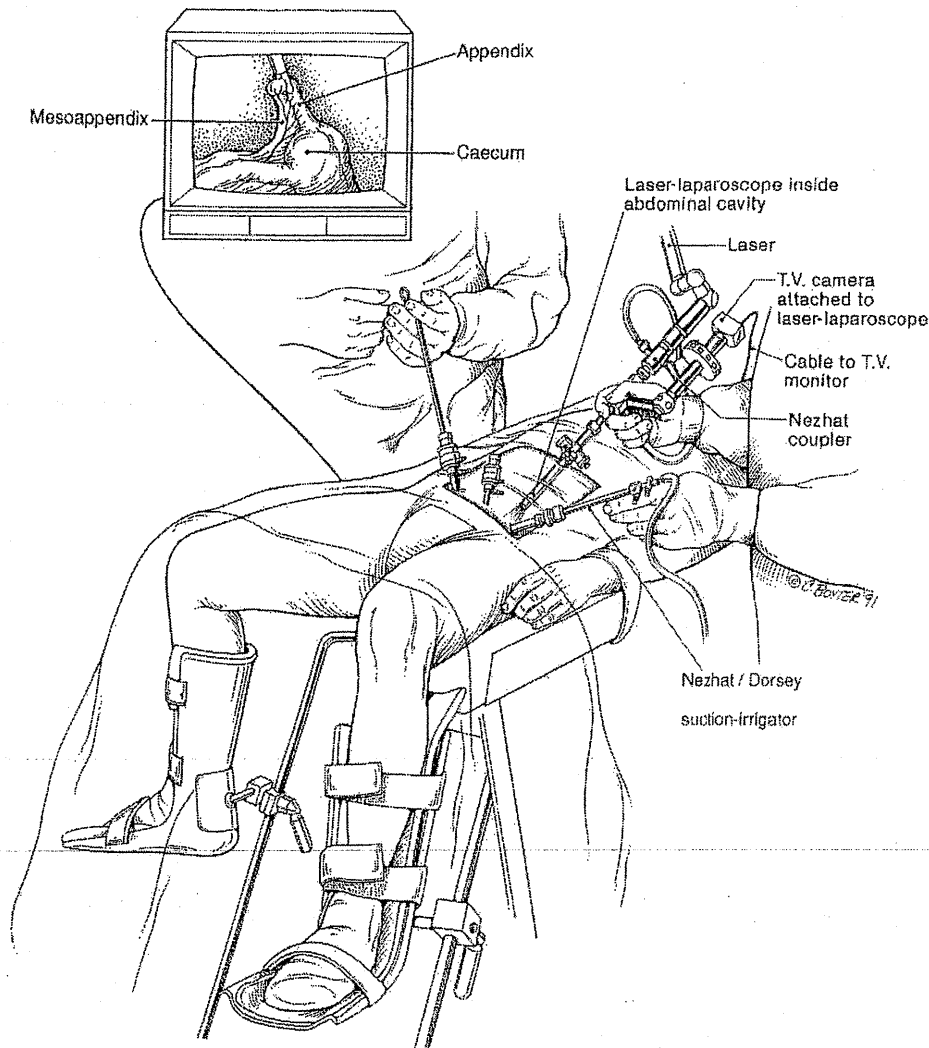


FIG. 1. Room setup for laparoscopy.

central 5 mm one. Instruments, which may be contaminated, are removed from the surgical area. No adjunctive therapy is necessary. Finally, the appendiceal and other operative sites are inspected for hemostasis and then irrigated with lactated Ringer's solution.²²

Appendectomies may last from 4 to 21 minutes. Postoperative instructions should include avoiding solid food for 24 hours. Otherwise, instructions are routine for gynecologic procedures, including an outpatient evaluation the day after surgery.

In a series of 254 appendectomies, no major intraoperative complications were noted. Postoperatively, one woman had a small pelvic abscess that required surgical intervention. All patients were discharged from the hospital within 24 hours of surgery.²⁰

Semm³⁵ has described a technique that uses sutures and crocodile forceps. After the appendix is freed from any adhesions, two sutures are placed at the base, and the area between the sutures is electrocoagulated using the crocodile forceps. The appendix is separated using hooked scissors and removed. Stapling devices may be used. However, they required a 12-mm trocar and are cost-prohibitive at present. Further, the use of this instrument has been associated with malfunction and several postoperative complications.²³

BLADDER RESECTION FOR SEVERE ENDOMETRIOSIS

Preoperatively, a standard bowel preparation is used, and the patients are given a povidone-iodine (Betadine) douche the night before and immediately before the procedure. Two 1 g doses of cefoxitin

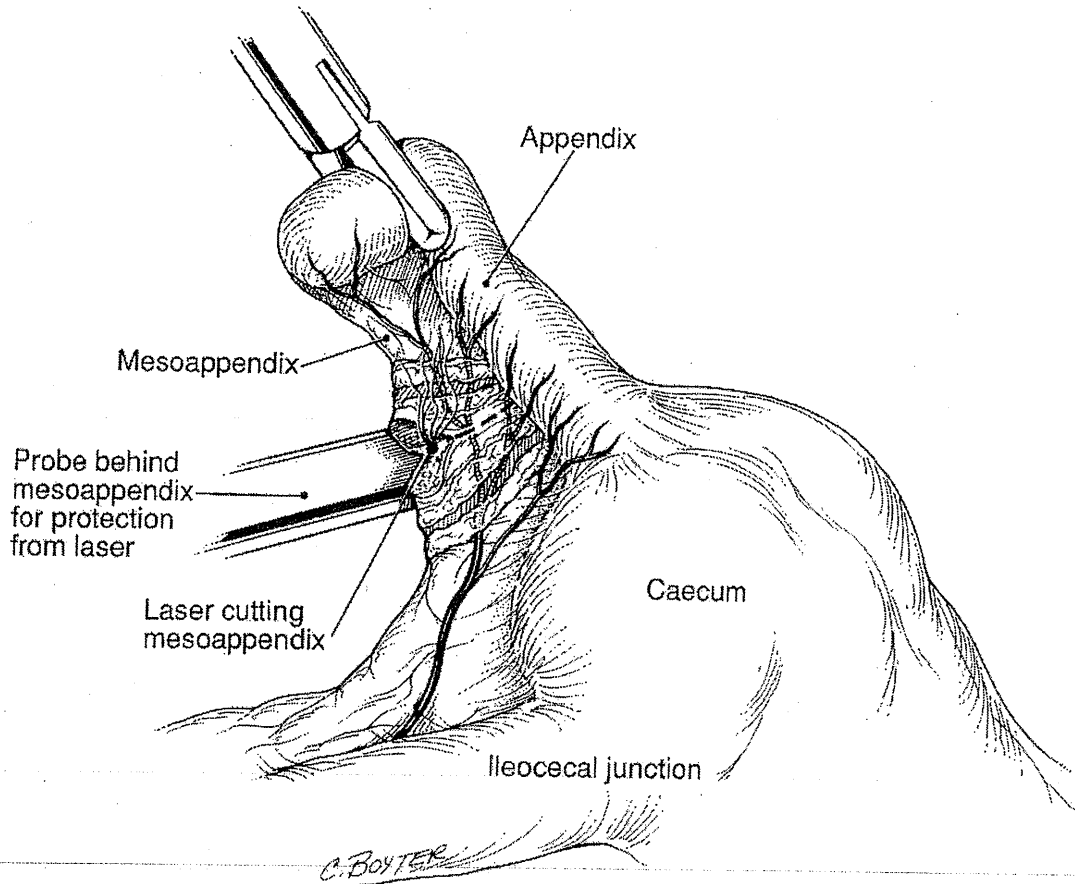


FIG. 2. Laser cutting the mesoappendix.

(Mefoxin, Merck, Sharp and Dohme, West Point, PA) are administered 1 hour preoperatively, and 1 g is administered postoperatively.

The CO₂ laser, hydrodissection, and bipolar electrocoagulation are used to excise the endometriosis nodule, including the mucosal layer.³⁶ Grasping forceps are used for tissue manipulation. After the nodule is removed and the bladder is closed,³⁷ cystoscopic evaluation is performed to determine if the closure is watertight. Any remaining pelvic endometriosis is treated, and the procedure is terminated. On release from the hospital, the patients are instructed to take trimethoprim and sulfamethoxazole (Septra DS, Burroughs Wellcome, Research Triangle Park, NC) for 2 weeks. The Foley catheters may be removed 7-10 days later and cystograms performed.

We have performed three partial cystectomies for severe bladder endometriosis. All patients are doing well, at 12, 5, and 2 months postoperatively.³⁸

ECTOPIC PREGNANCY MANAGEMENT

The chance of managing unruptured ectopic pregnancy laparoscopically has increased with rapid serum human chorionic gonadotrophic (hCG) assays and high-resolution vaginal ultrasound studies.^{5,39,40} New medical management techniques using ultrasonically guided injection of methotrexate, potassium, or prostaglandin F₂α may some day replace primary laparoscopic management of ectopic pregnancy.

When an unruptured tubal pregnancy is confirmed laparoscopically, surgical management should be instituted at that time. The surgeon should talk to the patient preoperatively to ascertain her desire for fertility preservation and to determine whether or not her history is significant for previous ectopic pregnancies. The patient must understand that salpingectomy or laparotomy may become necessary. However, an experienced

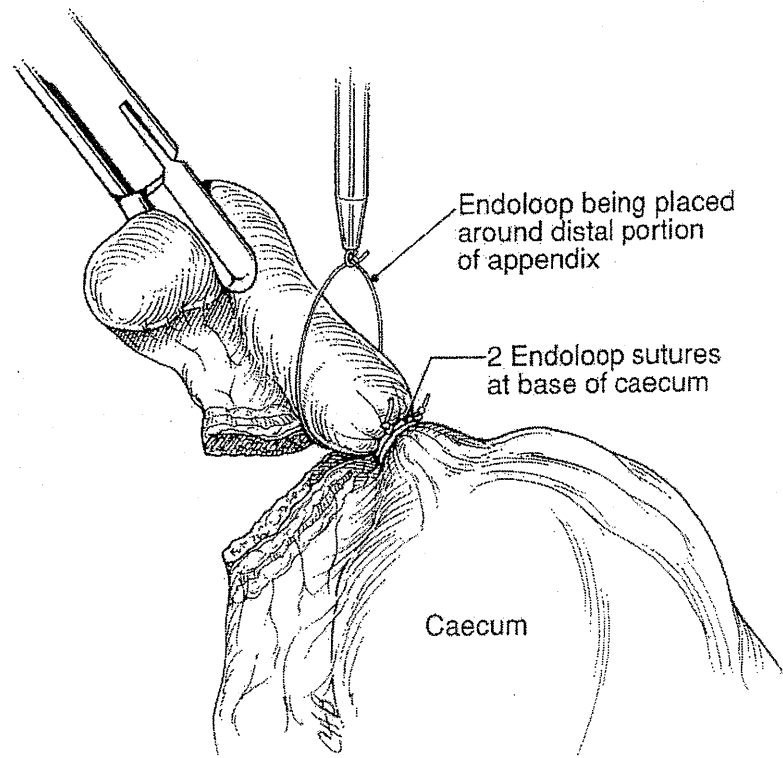


FIG. 3. Placement of Endoloop sutures.

endoscopic surgeon can laparoscopically manage ectopic pregnancies, regardless of size and independent of location.⁴¹ Finally, the need for careful follow-up with conservative management must be explained to the patient.

In patients who prefer permanent sterilization, coagulation using bipolar Kleppinger forceps over a small ectopic pregnancy will destroy the tubal pregnancy and sterilize the patient. For larger ectopics (greater than 6 cm), cases of spontaneous tubal rupture, or more than one recurrent ipsilateral ectopic pregnancy, salpingectomy may be indicated.²² This procedure is accomplished by placing the fallopian tube under traction using grasping forceps. The isthmus and mesosalpinx are serially coagulated with bipolar electrocoagulator and cut with the laser, scissors, or unipolar electrocoagulation (Figs. 4, 5). An alternative to electrocoagulation involves using an automatic stapling device,⁴² which is placed along the mesosalpinx perpendicular to the fallopian tube and triggered, simultaneously clamping and cutting the pedicle. At present, this technique is cost-prohibitive and has been associated with postoperative hematoma and ureteral injury.

Salpingotomy has been shown to produce higher subsequent pregnancy rates and a higher recurrence of ectopic pregnancy than salpingectomy.³⁹ Linear salpingotomy should be performed in patients who want to preserve the affected tube and are hemodynamically stable. Dilute vasopressin is injected into the mesosalpinx using a 22-gauge aspirating needle inserted through a 5 mm portal or using a 22-gauge spinal needle inserted directly through the abdominal wall. Direct vascular injection of vasopressin must be avoided. The fallopian tube is grasped and extended, and a 1.5 cm linear incision is made along the antimesenteric surface of the tube. The products of conception are allowed to extrude through the newly created salpingotomy or are flushed out using a suction-irrigator probe inserted into the tubal opening, then grasped and removed from the abdomen. An Endopouch specimen removal bag may also be used. Copious irrigation within the tube and the pelvis will ensure removal of the tissue and adequate hemostasis. Chromotubation with indigo carmine will indicate tubal patency and also will flush the remaining products from the tube. Putting vigorous traction on products of conception adherent to the mucosa may cause hemorrhage and must be avoided. Weekly hCG levels must be followed until they decrease to nonpregnant levels. Consistent or rising levels require further medical or surgical management.

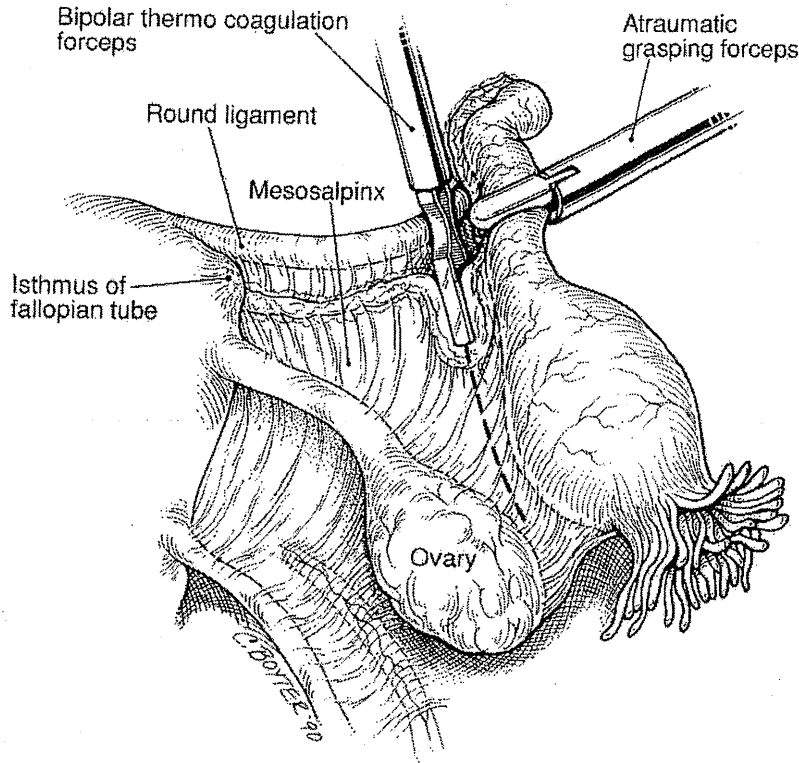


FIG. 4. Salpingectomy for ectopic pregnancy.

Segmental resection of the tube has a better prognosis in the narrow isthmic portion of the tube. This technique may be preferable because pregnancies in this site tend to infiltrate deeper into tubal tissue layers, are smaller, and less well defined for surgical manipulation.³⁹ Segmental resection also may be used in some cases of spontaneous rupture without active bleeding or persistent tubal pregnancies. The segment to be excised is coagulated at each end, using bipolar electrocoagulator or sterilization clips, and transected using the laser.^{5,22,39-41,43} The mesosalpinx of the segment is then coagulated and incised. As much fallopian tube as possible should be preserved so that reanastomosis with microsurgical technique can be accomplished at a later date.

HYSTERECTOMY

Laparoscopic hysterectomy (LH) may be defined as the complete endoscopic excision of the uterus from its attachments. In a total hysterectomy, the vaginal cuff may be repaired laparoscopically or vaginally. In a laparoscopic supracervical hysterectomy (LSH), the cervical stump is closed laparoscopically. All other combinations are variations of laparoscopically assisted hysterectomy.⁴⁴

Gynecologists recognize that vaginal hysterectomy patients experience less postoperative morbidity and pain and require a shorter period of recuperation when compared to patients having abdominal hysterectomies. However, approximately 70% of hysterectomies are still done by laparotomy. Laparoscopic and laparoscopically assisted vaginal hysterectomies have been introduced to provide an alternative to abdominal hysterectomy. Preliminary results confirm less intraoperative blood loss and shorter recuperation, without increased risk of complications.²³

Laparoscopic inspection and management, including adhesiolysis, endometriosis vaporization or excision, and salpingo-oophorectomy when indicated, are accomplished as described before.³³ The uterus may then be removed by standard vaginal hysterectomy technique, retaining the laparoscope for later inspection of the surgical site, or the procedure may be continued laparoscopically.

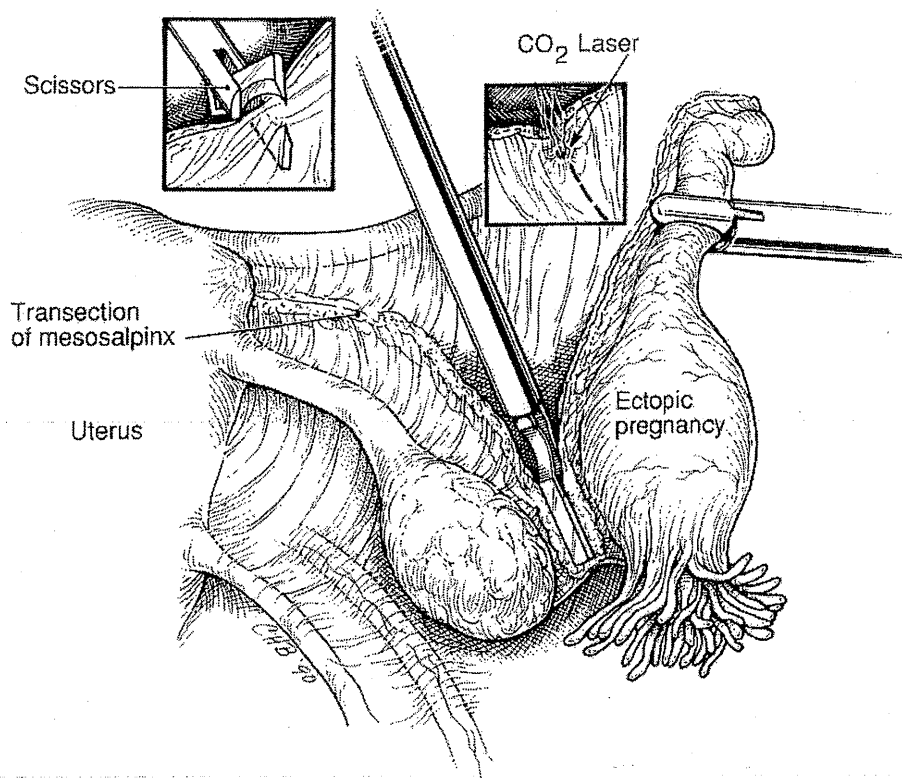


FIG. 5. Salpingectomy for ectopic pregnancy.

After evaluating the ureters, the infundibulopelvic ligament (or uteroovarian ligament if the adnexa are to be retained) and the round ligament are desiccated, suture ligated, or clipped using an automatic stapling device, then incised. Hydrodissection is used to create a bladder flap, which is then incised with CO₂ laser or scissors. The upper portion of the broad ligament is coagulated and incised anteriorly and posteriorly. The uterine vessels are identified, skeletonized, coagulated, and divided. A darkened right angle retractor placed in the vagina allows posterior and anterior culdotomy incisions to be accomplished with the CO₂ laser or other modalities. The uterosacral and base of the cardinal ligaments are approached vaginally, clamped, and incised, the uterus is removed, and the vaginal mucosa is closed using standard vaginal hysterectomy technique. For those patients in whom supracervical hysterectomy or complete laparoscopic hysterectomy with vaginal removal of the uterus is indicated, intraabdominal suturing is required to close the cervical stump or vaginal apex, respectively. Future vaginal wall prolapse can be prevented by obliterating the posterior cul-de-sac with the Moschowitz procedure. Before the procedure is terminated, the vaginal apex and pedicles are evaluated under decrease pneumoperitoneum with and without hydroflotation. All patients are given one prophylactic dose of antibiotics preoperatively and two doses postoperatively. Most patients can be discharged from the hospital within 24–48 hours of the procedure. We have been favorably impressed with the postoperative recovery of and low morbidity in these patients, particularly those women who had significant pelvic pathology, such as severe pelvic endometriosis, adhesions, and leiomyomas.

In a series of 156 laparoscopic or laparoscopically assisted hysterectomies for a variety of indications between July of 1987 and July of 1992 (7 for malignancy), there were no major complications.

We do not advocate converting vaginal hysterectomies to laparoscopic or laparoscopically assisted hysterectomies. Rather, the laparoscopic approach is an appropriate alternative to those procedures that otherwise would require laparotomy.⁴⁵

Radical hysterectomy

To date, we have performed 7 radical hysterectomies, 2 of them for stage IB cervical cancer. Our first radical hysterectomy was performed in June of 1989. We use the following technique to perform radical

hysterectomy and lymphadenectomy laparoscopically.²⁴ All pedicles are coagulated with bipolar electrocoagulator and incised with CO₂ laser, scissors, or unipolar electrocoagulator.²¹ Sutures are not necessary, and peritoneal incisions may be left to heal secondarily.

For the right common iliac and paraaortic lymphadenectomy, the patient is tilted to the left and placed into deep Trendelenburg at 35–40 degrees. After identification of the ureter, a peritoneal opening is made just above the sacral promontory. Using hydrodissection,⁴⁶ the retroperitoneal space is injected with lactated Ringer's solution and incised with the CO₂ laser toward the duodenal bulb.²⁴ The common iliac and paraaortic nodes are removed from the veins' surface by blunt dissection, electrocoagulation, hydrodissection, and CO₂ laser. Larger bleeders, such as the venous perforators of the vena cava, are coagulated first with the bipolar electrocoagulator.²¹ Following further identification of the ureter, dissection may be taken to 2–7 cm above the aortic bifurcation. Next, the rectovaginal, paravesical, and pararectal spaces are dissected. The round ligaments are coagulated close to the pelvic side walls and transected. The uterine vessels are identified, skeletonized, and coagulated medial to their origin and transected, then rotated anterior to the ureters.²⁴ The vesicovaginal space is developed using techniques described previously.

The uterine vessels are dissected medially for approximately 4 cm and elevated from the ureter using the CO₂ laser or other means of dissection. The anterior parametrium is transected, and the ureters are freed from the peritoneum and skeletonized down to the bladder. The uteroovarian pedicles are coagulated and transected.²¹ Left common iliac nodes are removed in the same manner as those on the right.

External iliac nodes between the external iliac vein and artery and obliterated hypogastric artery are carefully stripped to the deep circumflex veins. The obturator nerve is exposed, and the hypogastric and obturator nodes are removed. The obturator nerve should be dissected and cleaned caudally until leaving the pelvis. The nodal tissue between the obturator nerve and external iliac vein is dissected. The inferior aspect of the external iliac vein is separated until the internal obturator muscle and pelvic bone are seen. Venous anastomosis between obturator and external iliac veins may be visualized and saved. Lymph nodes posterior to the obturator nerve are excised. The uterosacral ligaments and lateral parametria are coagulated and sequentially transected lateral to the cervix. The dissection is taken down to 3 cm below the cervix. The vagina is entered anteriorly and posteriorly, with sponges placed to prevent escape of pneumoperitoneum.

The radical hysterectomy is completed vaginally by incising the vagina 3 cm distal to the cervix. Mobilizing anteriorly and posteriorly, the residual cardinal ligaments are divided approximately 2–3 cm lateral to the cervix and then suture ligated.²⁴ The uterus and pelvic nodes are removed transvaginally.²⁴ The vaginal vault is then closed, and a vesical suprapubic catheter is placed. The patient may begin eating within 24 hours and may be discharged as early as 48 hours. The suprapubic catheter can be removed on the seventh postoperative day.

The role of operative laparoscopy in gynecologic oncology remains controversial, and it has not been determined which cases are best served by this technique. Laparoscopy has been used successfully to treat cervical cancer,^{24,47} endometrial cancer,^{23,48} and early ovarian cancer.^{44,49} Several authors have used laparoscopy to perform pelvic node dissection,^{50,51} and we began reporting our experience with paraaortic and pelvic node dissection in 1989.^{52–55}

Marshall-Marchetti-Krantz (MMK) and Burch Procedure

Preoperative evaluation includes history, physical examination, pelvic examination, imaging techniques, and urodynamic testing (basic, or complex with or without urologic consult).

Placing the patient in Allen stirrups (Allen Medical, Mayfield, OH) permits an assistant to elevate the vaginal and paravaginal tissues for suture placement and subsequent knot tying.⁵⁶ A Foley catheter is placed in the urethra and bladder.

The transabdominal approach to the space of Retzius is accomplished using instrumentation reviewed previously.⁵⁶ The space of Retzius is entered using hydrodissection combined with the CO₂ laser set at 40–80 W, unipolar electrocoagulation, or scissors through a transverse intraperitoneal incision. The incision is placed cephalad to the suprapubic trocar site. The anatomic landmarks that avoid bladder entry are the trocar sites and the exit of the round ligaments from the internal ring.

In exposing the retropubic space, one should stay close to the back of the pubic bone, dropping the anterior bladder wall, vaginal wall, and urethra downward. The dissection should be limited over the urethra in the midline to protect the delicate musculature of the urethra from injury. While the assistant performs vaginal examination with one finger on each side of the catheterized urethra, the overlying fibrofatty tissue is cleared

from the anterior vaginal wall. Under videolaparoscopic magnification, the thin-walled venous plexus in this extremely vascular area is identified and protected from surgical trauma. Pneumoperitoneal pressure further assists the surgeon in controlling bleeding from very small vasculature.

The dissection is continued until the vesicourethral junction becomes clear and apparent. Videolaparoscopy and pneumoperitoneal pressure further aid dissection by magnifying the direct view of the area and expanding the space, both of which provide better exposure. Every effort should be made to protect the muscle fibers of the vesicourethral junction from any surgical dissection. After mobilizing the vesicourethral segment so that it can be lifted easily to a normal position, sutures are applied.

Bipolar electrocoagulation is used for hemostasis. Grasping forceps and a suction-irrigator probe are used to dissect the space of Retzius and debride the space of fat. The urethra, bladder, and urethrovesical junction are viewed. The retropubic ligaments and Cooper's ligament should be easily exposed. Pressure from the CO₂ gas provides clear, well-illuminated exposure of the contents of the space out to the obturator foramen and obturator nerve.

The paravaginal fascia may be identified using the grasping forceps. A single suture of 0 vicryl or polypropylene (Prolene, Ethicon) on a straight or curved needle is passed down the trocar sleeve. The sutures are placed using an assistant's finger as a guide and driven using a Storz needle driver (Karl Storz, Culver City, CA) and atraumatic grasping forceps. The suture is placed bilaterally from the paravaginal fascia to the retropubic ligament (MMK) or Cooper's ligament (Burch procedure)⁵⁷ and tied either intracorporeally or extracorporeally. The sutures are applied as far laterally as technically possible in the anterior vaginal wall. We apply one or two sutures on either side. Three sutures may be necessary in cases of poor tissue quality. The suture is placed just below the reflexion of the anterior bladder wall at the level of the vesicourethral junction and far laterally from it. A good bite in the vaginal wall parallel to the urethra is taken. Using the assistant's fingers as a guide, the full thickness of the vagina, excluding the mucosa, is included.

The suture is fixed to Cooper's ligament (Burch) or in the midline of the symphysis pubis (MMK). These sutures are tied one at a time either intracorporeally or extracorporeally. The sutures are tied with the aid of the assistant, who lifts the vagina upward and forward. In tying the sutures, there should be no excess tension in the vaginal wall even if the suture site does not meet the pubis bone or Cooper's ligament. The urethra should not be compressed against the bone. After the first and second sutures are tied, the assistant's fingers (in the vagina) will appreciate the amount of vaginal wall suspension, which lifts the vesicourethral segment. If the suspension is judged inadequate, a second or, rarely, a third set of sutures is applied. Fibrosis and scarring of the tissue in this area will provide future fixation and support of the vesical neck.

An indwelling Foley catheter remains in place for at least 3 days. The patient is discharged the day of or the day after surgery with prophylactic antibiotics. After removal of the Foley catheter, the patient is usually able to void easily. Postoperative activity is partially limited for 8–12 weeks to avoid any abnormal increase in intraabdominal pressure.

In a series of 24 patients, operative time for the MMK and Burch procedure ranged from 25 to 45 minutes, and blood loss was from 10 to 60 mL.

No intraoperative or postoperative complications were noted, except for one woman who was unable to void. She required self-catheterization for 10 days. All other women voided after removal of the Foley catheter. To date, all patients have reported subjective and objective success (Tables 1 and 2).

The preliminary results from our 3–25 month follow-up are encouraging, and our work in this area is ongoing. In a series of 9 patients, Vancaillie and Schuessler have successfully performed laparoscopic MMK in 7 women.⁵⁸

MYOMECTOMY

Patients with indications for laparoscopic myomectomy are managed with GnRH analogs (Lupron, Tapp Pharmaceuticals, North Chicago, IL, or Synarel, Syntex, Palo Alto, CA) for up to 3 months preoperatively.

TABLE 1 DURATION OF FOLLOW-UP (IN MONTHS) AFTER MMK OR BURCH PROCEDURE

	0–6	7–12	13–18	19–25
No. of patients	4	5	6	9

TABLE 2 PERCENTAGE OF IMPROVEMENT FOLLOWING MMK OR BURCH PROCEDURE

	81-100	61-80	41-60	21-40	< 20
No. of patients	17	2	2	2	1

Reducing tumor size, improving operative handling, and reducing intraoperative blood loss are theoretical advantages. Three months of amenorrhea does improve preoperative hematocrit levels. However, patients are also given the option of autologous blood donation.⁵⁹

Laparoscopic myomectomy has two stages. The first, removing the tumor from the uterus, is generally straightforward. The second, however, removing the tumor from the abdomen, can be long and tedious.

A pedunculated myoma is simply excised at the stalk using high-power CO₂ laser, scissors, or electrocoagulation, and bleeding is controlled with bipolar electrocoagulator. For intramural or subserosal myomata, 5-10 mL of dilute vasopressin (20 U in 100 mL of sterile saline) is injected under the capsule. The capsule is incised with CO₂ laser (between 60 and 100 W) and gradually dissected using a combination of suction-irrigator probe, hydrodissection, and laser. When CO₂ gas is used for pneumoperitoneum, higher powers of the CO₂ laser (except the latest Ultrapulse 5000 L, Coherent) create a larger spot size (between 2 and 3 mm), which is hemostatic for vessels with diameters of 2-3 mm. Traction on the myomas can be produced with a small hook or claw forceps. Once the myoma is removed, the base is thoroughly irrigated, and hemostasis generally requires bipolar electrocoagulator rather than low-power laser. To close the myometrial defect, 4-0 PDS endosutures (Ethicon) probably are the most appropriate, but clips (Ethicon) also might be used. Intraligamentous myoma are approached by incising the anterior or posterior leaf of the broad ligament (depending on the location of the myoma) with laser after identifying the location of large vessels, ureter and bladder. Excision is then accomplished as described for subserosal myomas.

The basic surgical principles for myomectomy are identifying and removing the tumor, permanent hemostasis, and eliminating the dead space. Laparoscopic microsurgical repair of the uterus using 6-0 or 7-0 sutures at the present time is not possible. Our experience suggests possible vascular adhesion formation following laparoscopic repair of the uterus.⁵⁹ Another problem in laparoscopic removal of myoma remains its extraction from the abdominal cavity, although this has been simplified by the availability of an 18 mm trocar (Ethicon).

Posterior colpotomy, when feasible, is the most technically acceptable route for the removal of large (>5 cm) and multiple leiomyomas. Morcellation in the posterior cul-de-sac by the assistant becomes an additional option. However, this procedure lengthens the duration of the surgery and increases the risk of morbidity, including infection and rectal or ureteral injuries, and should be performed cautiously.

The strength of the uterus after laparoscopic myomectomy is unknown and must be determined to predict the ability of the organ to withstand labor and delivery. Although uterine healing appears adequate after removal of small myomas, indentations have been noted on removal of larger lesions without suturing, which might represent structural defects. Even when endosutures are applied, the meticulous reapproximation of layers available by microsurgical laparotomy is very difficult during laparoscopy. In a series of 158 women, 6 uterine fistulas were noted postoperatively.⁶⁰ Harris reported one case of uterine rupture during pregnancy following myomectomy.⁶¹

Finally, adhesion formation is of great concern when future fertility is desired. The data obtained after second-look procedures reveal an increase in the number and density of adhesions when the suturing is undertaken.⁵⁹

OOPHORECTOMY AND ADNEXAL MASS MANAGEMENT

Although the laparoscope has proven to be a safe and effective diagnostic and therapeutic tool in the hands of experienced laparoscopists, doubts remain about the laparoscopist's ability to diagnose and properly manage early ovarian cancer if the adnexal mass is found to be malignant.⁶² One of the chief concerns is that spillage of a cancer confined to the ovary may worsen prognosis. However, when an experienced surgeon follows proper protocol (Table 3 and Fig. 6), adnexal masses may be safely evaluated, and the majority may be treated laparoscopically. In premenopausal women with ovarian cysts, factors to consider besides malignancy are avoiding the resection of normal ovarian tissue, and traumatization which may result in adhesion formation.

TABLE 3. PREMENOPAUSAL ADNEXAL MASS

Preoperative evaluation	Intraoperative evaluation
History and physical examination	Diagnostic laparoscopy
Pelvic ultrasound	Peritoneal washing
Hormonal suppressive therapy, if indicated	Cyst aspiration
Informed consent	Evaluation of the cyst
Draw blood and retain for possible tumor marker	Possible frozen section
	Cystectomy or oophorectomy

Patients should be evaluated clinically with a pelvic examination and vaginal ultrasound study, along with a review of previous intraoperative records. Simple (unilocular) cysts in premenopausal women are managed initially with hormonal suppressive therapy using oral contraceptive pills containing 50 µg of estrogen, Depo-Provera, or danazol. A blood sample for serum CA-125 level or other tumor marker, if indicated, should also be obtained and saved. CA-125 and ultrasonographic examination have more value in evaluating postmenopausal women than premenopausal women.^{62a}

Informed consent should include a statement to the patient that laparoscopic diagnosis and treatment of adnexal mass are not standard medical practice at this time. Patients are further informed that if a cancer is found, intraoperative cancer cell spillage can occur and can influence the chance of survival. In addition, the patients must understand that a second surgery, specifically a laparotomy, might be required if the findings at laparoscopy cannot be properly managed laparoscopically.

Intraoperative management of all patients with masses is carefully standardized and includes inspecting the pelvis, ovaries, upper abdomen, and diaphragmatic surfaces for any vegetation or other sign of malignancy. Peritoneal washings are obtained for cytology. If a strong suspicion of malignancy based on intraoperative

Postmenopausal Adnexal Mass Evaluation

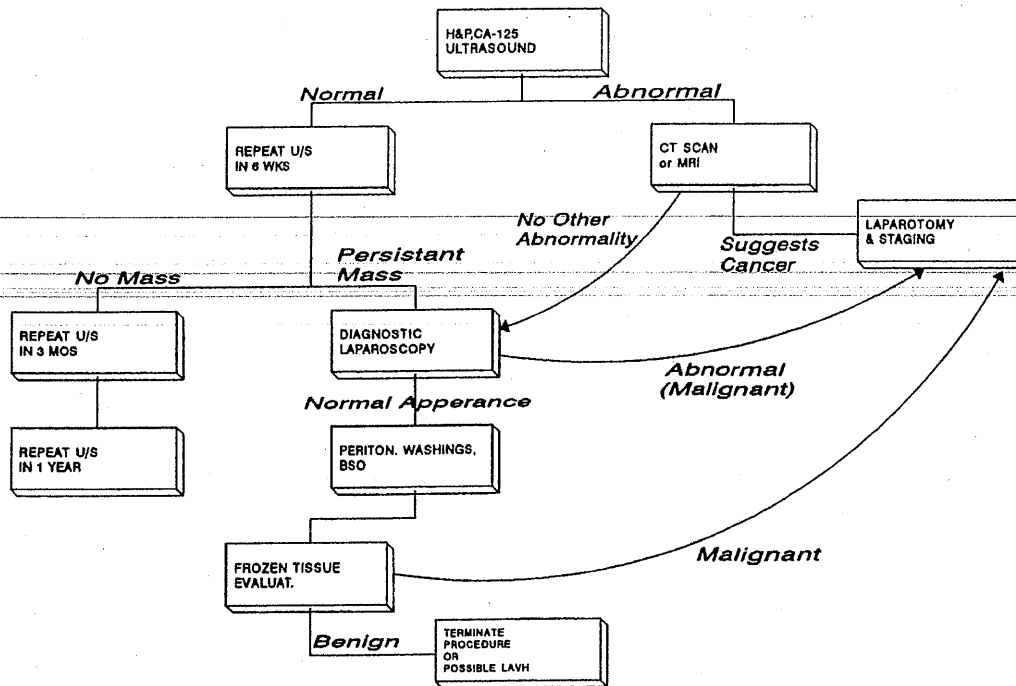


FIG. 6. Evaluation of postmenopausal adnexal mass.

findings exists, an attempt is made to obtain frozen section biopsies without rupturing the cyst. If that is not possible, the laparoscopic procedure is terminated, and the patient will undergo a laparotomy.

Management of the cystic mass itself includes aspirating the fluid and sending it for cytologic study, followed by opening the cyst and inspecting the wall for excrescences or irregular thickening. Frozen section biopsies are obtained if the surgeon thinks that any surfaces appear suspicious. Finally, depending on the patient's age and pertinent clinical history, an ovarian cystectomy or oophorectomy may be performed.²¹ Scissors, unipolar electrocoagulation, or CO₂ laser (set at 30–80 W in the ultrapulse mode) may be used to cut, and bipolar electrocoagulator may be used for coagulation and desiccation of the infundibulopelvic ligament.

After exploration of the pelvis and abdomen, oophorectomy is carried out as follows. Any existing adhesions between the ovary and adjacent organs, pelvic walls, and broad ligament are lysed with CO₂ laser. A suction-irrigator probe is introduced suprapubically and used both as a backstop and to provide constant suction, irrigation, and smoke evacuation. When the ovary is severely adherent to the lateral pelvic wall and in cases with previous hysterectomy, hydrodissection⁴⁶ is used to open the peritoneum, beginning at the pelvic brim, and the courses of the ureters and major blood vessels are identified. Using the same techniques, the descending colon and rectosigmoid colon are dissected from the left infundibulopelvic ligament and ovary. Ovarian cysts are aspirated, allowing easier handling of the deflated cyst and smaller ovary. Once the ovary is completely mobilized, it is held under tension with grasping forceps. The ovarian ligament is desiccated using bipolar electrocoagulator and transected at its junction to the uterus (Fig. 7). Using 20–25 W, bipolar electrocoagulator is applied briefly to blanch and desiccate the tissue, being careful not to overdesiccate, in order to reduce the blood flow to the pedicle to be transected. The mesovarium is then serially blanched, coagulated, and transected at 1–2 cm increments, working medial to lateral, until the ovary is removed. When the ipsilateral fallopian tube also is removed, the isthmic portion of the tube is severed and incised along with the ovarian ligament. After identification of the ureter, the infundibulopelvic ligament is coagulated and transected at 1–2 cm increments, working from lateral to medial, until the adnexa is removed as described previously (Fig. 8). Alternatives to coagulating and blanching include an automatic stapling device and

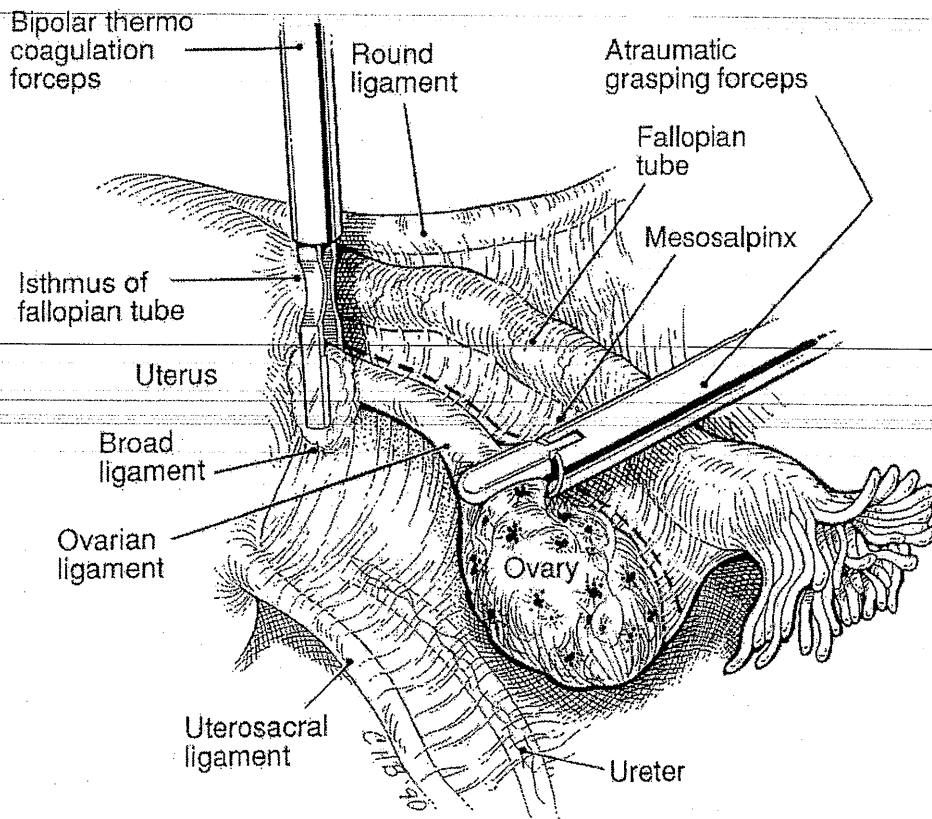


FIG. 7. Coagulation of infundibulopelvic ligament.

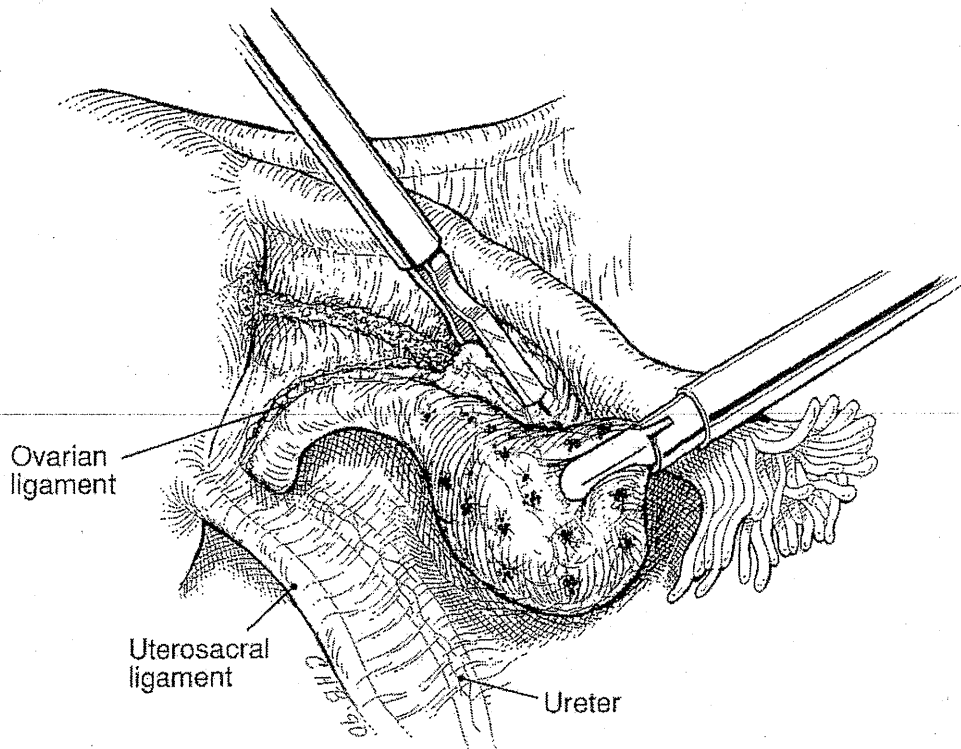


FIG. 8. Saving the tube while removing the ovary.

Endoloop (Ethicon) sutures. It is imperative that the ovary be free of any attachments, however, since the stapler has been associated with postoperative hematoma and ureteral injury,²³ and sutures may trap ovarian tissue, resulting in ovarian remnant syndrome.⁶³

In most cases, the ovary is removed from the peritoneal cavity through a 10 mm trocar sleeve placed into one of the suprapubic puncture sites. The ovary is held with forceps, and the forceps and sleeve are removed together, delivering the ovarian tissue to the abdominal wall, where it is then grasped by a Kelly clamp and removed. Alternatively, the tissue may be removed by posterior colpotomy,⁶⁴ tissue removal bag (Endopouch) or an 18 mm trocar (Ethicon). If at all possible, the tissue should be removed without coming into contact with the edges of the incisions or abdominal wall. The tissue removal bag is designed for this purpose. The tissue is submitted for permanent section histologic study.

Thorough irrigation is necessary to clean the incision. After removal of the cyst, the abdominal and pelvic cavities are washed thoroughly with copious amounts of irrigation fluid, especially in cases of endometriomas, dermoid cysts, or mucinous cystadenomas.

Before terminating the procedure, any associated pelvic pathology, such as endometriosis or other adhesions, is treated, and hemostasis is assured. Women who have undergone ovarian cystectomy for benign ovarian neoplasms (mucinous or serous cystadenomas or cystic teratomas) are followed by a biannual pelvic examination and an ultrasound examination to look for possible recurrence at both 6 weeks and 6 months postoperatively.^{64a}

An alternative technique for oophorectomy is used by Semm and Mettler.⁶⁵ After freeing the ovary from adhesions, three Roeder loops (Ethicon) are placed, and the pedicle is cut. No bleeding complications have been reported with this method.

We believe that laparoscopic evaluation and management of a benign adnexal mass performed by experienced operative laparoscopists is safe. However, no substitute exists for sound clinical judgment. A surgeon should perform the techniques he or she is comfortable with and should conduct careful preoperative patient screenings.⁴⁹ Figure 6 and Table 1 detail our protocol for the evaluation and management of adnexal masses and ovarian cysts in postmenopausal and premenopausal women.

Laparoscopic ovarian cystectomy has been performed successfully during pregnancy.⁶⁶ Proper patient selection and operator experience are critical. The patient's consent should include acknowledgment that operative laparoscopy is not the standard treatment at this time and that spontaneous abortion or premature labor is possible with any surgery during pregnancy. The 10 mm trocar placement is adjusted to 6 cm or higher above the umbilicus, and pneumoperitoneum is established at less than 10 mm Hg. The open laparoscopic technique used by Hasson is recommended. The remaining trocars are inserted under direct visualization, and no intracervical instruments are used. Any manipulation of the uterus is accomplished gently with intraabdominal instruments.

We have performed a laparoscopically assisted hysterectomy and staging for a borderline ovarian tumor, without compromising the patient's prognosis.⁴⁴ As long as the metastasis and spread of the tumor are not bulky, we believe that even Stage III ovarian cancer can be treated and excised laparoscopically, and removed vaginally by an experienced surgeon. The only limit to this approach is in treating advanced stages of ovarian cancer that require extensive debulking.

During our use of operative laparoscopy to manage other gynecologic malignancies, we have noted several encouraging results that lead us to believe that this technique may be used more extensively in treating malignant conditions in the future. In our opinion, the applications of this technique extend beyond ovarian cancer, to endometrial and cervical cancer as well. For example, we believe that any stage of endometrial cancer can be managed laparoscopically, and that a longer portion of the vagina can be removed than with laparotomy. Furthermore, stage IA2 cervical cancer with lymphatic channel involvement, stage IB, and stage IIA (especially when the lesion extends into the vagina) can be effectively managed by operative laparoscopy. For stages IIB and higher, the technique is useful for node dissection, and can be used to change the FIGO staging to clinical staging. Finally, we believe that operative laparoscopy can be used to assist pelvic exenteration.

ENDOMETRIOMAS

Superficial endometriosis of the ovaries can be treated by vaporization. Because small endometriomas (<2 cm) tend to be fibrotic and difficult to remove, they can be biopsied and then vaporized. Larger endometriomas, however, must be removed completely, including the capsule, to reduce the risk of recurrence.⁶⁷ Simple aspiration or fenestration of endometriomas can lead to an unacceptably high level of recurrence, as demonstrated by Nezhad et al.⁶⁷ and by Hasson.⁶⁸ However, Faye and Vogel⁶⁹ have reported favorable results following simple drainage of endometriomas, and their approach warrants further investigation.

Management of endometriomas must be approached in the same way as all other adnexal masses, keeping in mind that endometrioid carcinoma can coexist with endometriosis and is indistinguishable at surgery until histologic results are reported. We have encountered this type of case, which appeared at laparoscopy to be typical bilateral endometriomas. The smaller cyst (3 cm diameter), however, proved to be endometrioid low malignant-potential tumor. Thus, histologic examination of the cyst wall is mandatory in even the most typical appearing case.⁴⁹

When endometriomas are suspected on the basis of ultrasound appearance or previous operative reports, hormonal suppressive therapy (danazol or GnRH analogs) given for 6–8 weeks preoperatively will reduce vascularity and suppress ovarian activity.⁷⁰ Consequently, intraoperative hemorrhage will be reduced, surgical manipulation of follicular or corpus luteum cysts will be avoided, and more of the normal ovarian tissue will be preserved. Similarly, 6 weeks of postoperative suppressive therapy in cases of endometrioma removal will, in our opinion, facilitate better healing. For patients who are not interested in achieving pregnancy, we suppress ovulation with oral contraceptives indefinitely.

The laparoscopic approach to an endometrioma is as follows. The cyst is first aspirated and drained through an 18-gauge aspiration needle inserted through one of the suprapubic portals. After copious irrigation of the cyst and pelvis, the cyst wall is opened further and inspected. The capsule is stripped from the ovarian stroma using two grasping forceps or excised using the laser and submitted for histologic examination. Hydrodissection can be used for easier removal of the ovarian cyst capsule.⁷¹ The laser can be used at low power (10–20 W, continuous) to seal blood vessels at the base of the capsule and at higher power to vaporize any small capsule remnants. The ovarian defect is left to heal without suturing. If the edges of the ovarian capsule do not approximate spontaneously, low power laser or bipolar electrocoagulator can be used to invert them by treating the inner surface of the defect, causing the surface so treated to contact and invert. In the event that the

edges still will not approximate, one or two 4-0 PDS (Ethicon) may be used. It is important to keep in mind that fewer sutures will result in fewer adhesions.⁷²

In a prospective study of 216 hemorrhagic, or chocolate, ovarian cysts, three types of cysts were identified, both clinically and pathologically.⁷³ They were classified based on gross appearance, size, content, ease of removal of the capsule, and pathologic findings. Superficial endometriomas of less than 2 cm (type I) were difficult to remove. All type I cysts contained a histologically confirmed endometrial gland and stroma. In endometriomas larger than 2 cm (types II, IIIa, and IIIb, based on the proximity of the endometrial implant to the cyst's capsule), 0, 50%, and 85% contained an endometrial lining, respectively. We have postulated that large ovarian endometriomas represent secondary involvement of functional cysts with superficial endometriosis.

When the histologic appearance was compared with the clinical classification, small superficial cysts were always endometriomas (type I), large cysts with walls that were easily removed were usually luteal cysts (type II), and large cysts that had adhesions or were associated with superficial endometriosis implants were often endometriomas, but some also had histologic characteristics of corpus luteum cysts (types IIIa and IIIb). The ability to classify endometriomas may enhance further study into the etiology and pathophysiology and provide possible methods to prevent and treat endometriosis.

OVARIAN REMNANT MANAGEMENT

With advances in the laparoscopic technique, more complicated conditions, such as ovarian remnant, which usually involves the bowel, bladder, and ureter with dense adhesions, can be treated laparoscopically. For patients who have undergone previous laparotomy, the laparoscope should be inserted following a mapping technique.³³ Intraabdominal adhesions are lysed and ovarian remnants are dissected using hydrodissection⁴⁶ and videolaseroscopy.³³ The anatomy of the retroperitoneal space is identified in all cases involving an ovarian remnant adherent to the lateral pelvic wall. Inserting ureteral catheters may, at times, be helpful in identifying the ureters. The peritoneum is injected with lactated Ringer's solution and dissected to the infundibulopelvic ligament remnant.^{21,63} Adhesions are lysed until the courses of the major pelvic blood vessels and the ureters can be traced and, if necessary, dissected. The ovarian blood supply is desiccated with bipolar electrocoagulator, and the ovarian tissue is incised, removed, and submitted for histologic evaluation.⁶³

Adhesions involving the bowel surface are injected with lactated Ringer's solution above the serosa, creating a plane of cleavage and safe zone for laser incision.⁴⁶ Ovarian tissue embedded in the muscularis of the bowel is removed. In cases of enterotomy, the bowel is repaired with one to three interrupted 4-0 PDS in one layer.^{36,74} All patients have reported excellent results. Depending on concomitant procedures, patients may be discharged within 24 hours of surgery. Excellent results with few complications have been reported with this technique.⁶³

PERITONEAL ENDOMETRIOSIS

Since the CO₂ laser does not penetrate water, a fluid backstop (hydrodissection) allows the surgeon to work on selected tissue with a more comfortable margin than would otherwise be available.⁴⁶

To treat endometriosis of the bladder, for example, an aspiration needle is used to inject 20–30 mL of lactated Ringer's solution subperitoneally in an avascular area approximately 2 cm from the endometrial lesion. This elevates the peritoneum and backs it with a fluid bed. A 0.5 cm incision is made with the laser on this elevation, through which 100–200 mL of lactated Ringer's solution are injected subperitoneally (Fig. 9).

The lesion may then be vaporized or excised using the CO₂ laser in the ultrapulse mode. For excision, a circular line is made with a radius of 0.5 cm from the lesion. The peritoneum is grasped and pulled away with the help of the CO₂ laser and the tip of a suction-irrigator probe.

When endometriosis forms scarring to the subperitoneal connective tissue, creating openings as described and injecting fluid on the lesion's lateral sides allows water to tunnel under the lesion. This often separates scarring, and the implant can then be vaporized or removed. Irrigation and washing should follow to remove all by-products and ensure complete treatment of the disease. More extensive endometriosis may be treated after removing the peritoneum, again followed by irrigation and washing.

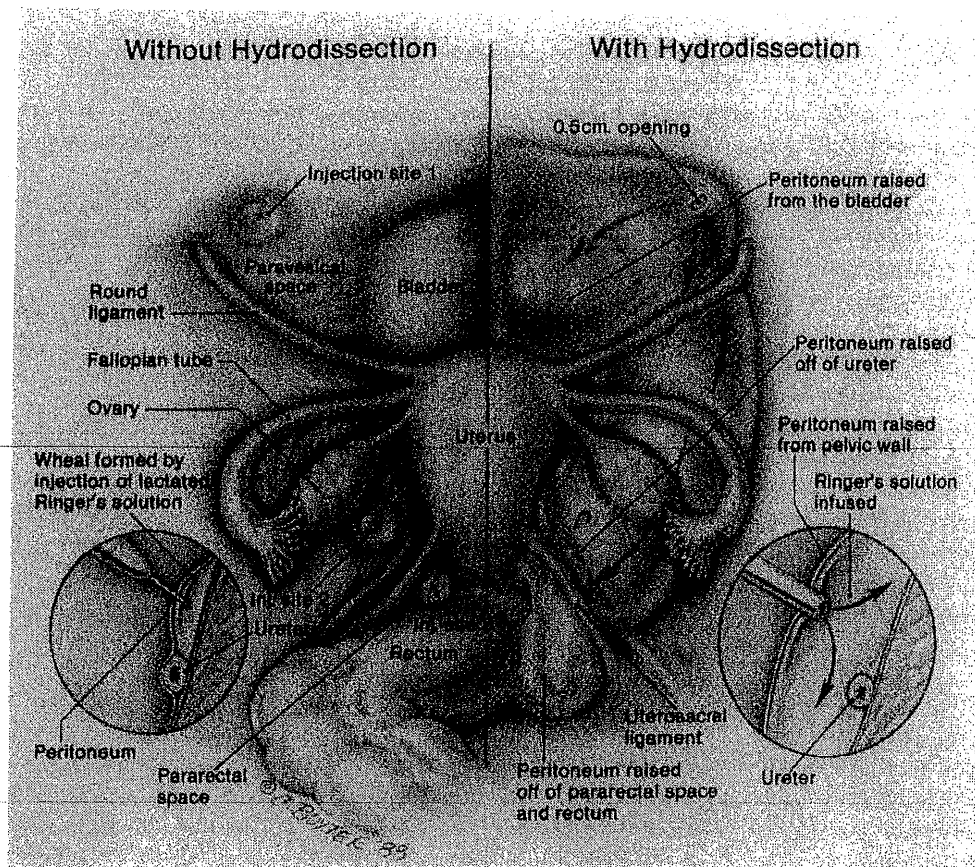


FIG. 9. Technique of hydrodissection.

Proper use of hydrodissection allows experienced laparoscopic surgeons to treat mild to extensive endometriosis with the CO₂ laser not only more thoroughly but also more safely than was previously possible.⁷⁵

Manipulation of and trauma to the pelvic organs should be kept to a minimum. Any excessive resection, vaporization, coagulation, or manipulation in this area may predispose the patient to adhesion formation.

Rock has reported good results using electrocoagulation to treat endometriosis.⁷⁶

PRESACRAL NEURECTOMY

Presacral neurectomy offers a surgical alternative for the amelioration of intractable dysmenorrhea.⁷⁷ Originally introduced in 1899, it fell into disfavor as a result of poor patient selection and with the introduction of nonsteroidal anti-inflammatory drugs, oral contraceptives, danazol, and GnRH analogs. Despite the overall success of medical therapy, approximately 30% of patients fail to obtain relief.⁷⁸ Until recently, presacral neurectomy was performed by laparotomy, limiting its application to women who had incapacitating dysmenorrhea and central pain unresponsive to medical therapy or who were undergoing laparotomy for other pelvic pathologic conditions. However, recent advances in endoscopic surgery now permit a laparoscopic approach to the classic presacral neurectomy in women with primary and secondary dysmenorrhea and in endometriosis-associated dysmenorrhea and central pelvic pain, where medical therapy has failed to provide adequate relief.

This procedure uses a single umbilical laser laparoscope and two or three suprapubic accessory trocars, as in videolaseroscopy with the CO₂ laser.^{20,33} A power setting of 30–40 W in the ultrapulse mode is used for all procedures. Steep Trendelenburg positioning is required to keep the bowel out of the operative field. The sacral promontory, ureters, and iliac vessels are identified. The peritoneum overlying the sacral promontory is elevated by smooth grasping forceps, and a small opening is made in the peritoneum using the CO₂ laser. A

suction-irrigator probe is inserted into the incision, and the peritoneum is elevated from the underlying tissue using hydrodissection (Fig. 10).⁴⁶ The peritoneum is incised vertically and horizontally and extended cephalad to just below the aortic bifurcation. Bleeding points are controlled with the CO₂ laser or bipolar electrocoagulator. The following landmarks are identified beneath the peritoneum: common iliac arteries, ureter, inferior mesenteric, superior hemorrhoidal, and midsacral arteries. The loose areolar tissue is excised as necessary using the CO₂ laser to gain access to the presacral nerves. Care should be exercised in clearing the areolar tissue. Bleeding in this area is difficult to control even at laparotomy. The hypogastric nerve bundle is identified, grasped, and skeletonized as necessary to isolate the superior hypogastric plexus. A 3–4 cm segment of nerve tissue is excised using the CO₂ laser (Fig. 11). It is important to remove a wide portion of nerve between the two ureters and under the descending colon on the left side. Suturing of the ends of the nerve bundle is not necessary. The retroperitoneal space is copiously irrigated, and bleeding points are controlled with the laser or bipolar electrocoagulator. The edges of the peritoneum are not sutured.

We have performed presacral neurectomy in over 150 patients with severe dysmenorrhea and central pain associated with different stages of endometriosis. These patients all had failed previous medical or surgical treatment. There have not been any intraoperative or postoperative complications, except for one case of active bleeding. The source was a branch of the inferior mesenteric artery, and the bleeding was controlled laparoscopically. Blood loss was minimal, and no patient required a laparotomy. Most patients were discharged on the same day, but some stayed overnight for convenience. All patients left the hospital within 24 hours of surgery.⁷⁷

TREATMENT OF BOWEL ENDOMETRIOSIS AND BOWEL RESECTION

Patients with severe endometriosis frequently have uterosacral ligament, rectovaginal septum, and deep rectosigmoid involvement, with partial or complete obliteration of the posterior cul-de-sac. The usual surgical treatment consists of correction and dissection by laparotomy. Good pain relief and adequate pregnancy rates have been reported.⁷⁹

Women with endometriosis of the lower colon, rectum, uterosacral ligaments, or rectovaginal septum generally undergo videolaseroscopy after previous surgical or hormonal therapy management fails to relieve their discomfort. Presenting symptoms commonly include chronic pelvic pain with dysmenorrhea, dyspare-

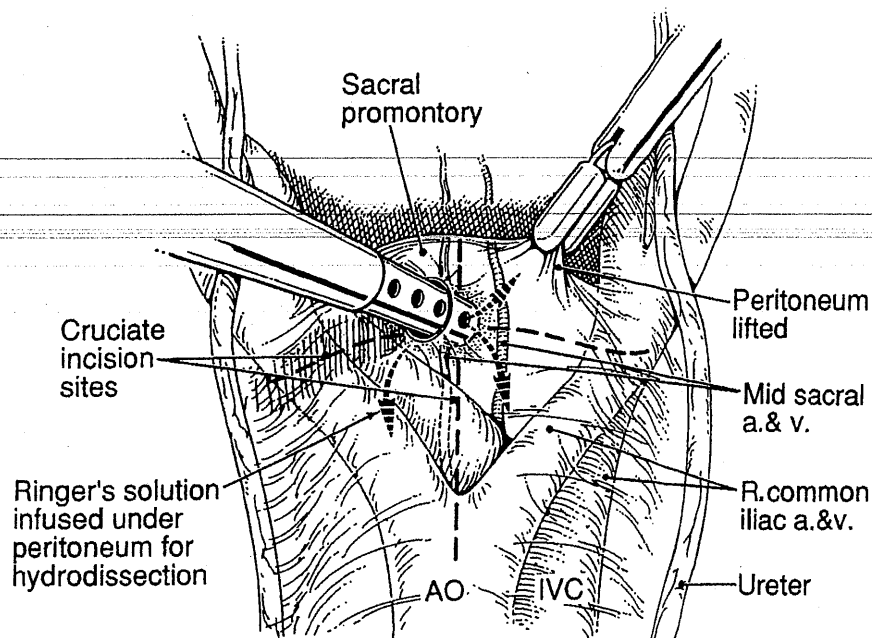


FIG. 10. Peritoneum being lifted and incision sites.

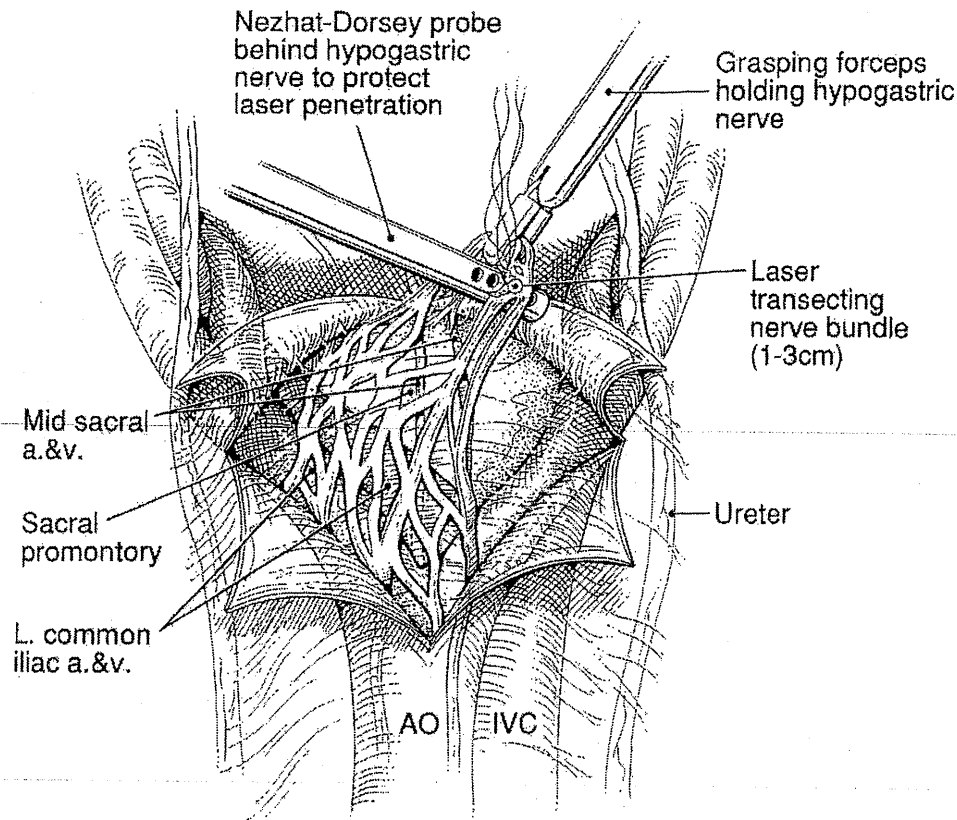


FIG. 11. Laser transecting nerve bundle.

unia, back pain, dyschezia, constipation or diarrhea, and infertility with pelvic pain. Patients with histories of rectal bleeding should be evaluated by sigmoidoscopy, and a barium enema may be necessary before laparoscopy.

The patient is prepared as an outpatient. In addition to the bowel preparation, at approximately 11:00 PM the night before surgery, she takes 1 g of metronidazole orally. One gram of cefoxitin sodium is administered one half-hour before the scheduled procedure.

Between 40 and 80 W of CO₂ laser are used to vaporize or excise the endometriosis. An assistant stands between the patient's legs, performing rectovaginal examination with one hand. The other hand holds the uterus up with a curette, a dilator, or the Humi rigid uterine elevator while both the assistant and surgeon observe the monitor. For rectovaginal septum and uterosacral ligament endometriosis, 5–8 mL of diluted vasopressin (10 units in 100–200 mL of lactated Ringer's solution) is injected in an uninvolved area with a 16-gauge laparoscopic needle. Using the CO₂ laser, the peritoneum is opened and hydrodissection⁴⁶ is used, as described previously.

An assistant examines the rectum as the involved area is completely excised or vaporized until the loose areolar tissue of the rectovaginal space or normal muscularis layers of the rectum are reached. In patients whose rectum is pulled up and attached behind the cervix between the uterosacral ligaments, the uterus is first anteflexed sharply, and an incision is made at the right or left pararectal area and extended to the junction of the cervix and the rectum. If the rectal involvement is more extensive and the assistant's finger is not long enough, a sigmoidoscope, a sponge on forceps, or a rectal probe is used. The sigmoidoscope not only helps the surgeon identify the rectum but also aids in detecting bowel perforation by visualizing air bubbles as they pass from the air-inflated rectum into the posterior cul-de-sac, which has been filled with irrigation fluid. With the assistant guiding the surgeon by rectovaginal examination, the rectum is freed completely from the back of the cervix. Any generalized oozing and bleeding may be controlled with an injection of 3–5 mL diluted vasopressin solution (1 ampule in 100 mL), laser, or bipolar electrocoagulator. Occasional bleeding from the stalk vessels caused by dissection or vaporization of the fibrotic uterosacral ligaments and pararectal areas is controlled with bipolar electrocoagulator.

Because ureters are lateral to uterosacral ligaments, one should try to stay between the ligaments as much as possible. Using hydrodissection and making a relaxing incision lateral to the uterosacral ligament allow the ureters to retract laterally, helping to protect them. Different degrees of ureterolysis may be necessary to free the ureters from the surrounding fibrotic, endometriotic tissue and large or small endometriomas. Endometriomas and ovaries may be severely attached to the bowel and ureter. Hydrodissection⁴⁶ along with the CO₂ laser and blunt dissection are used for ureterolysis, enterolysis, and ovarian cystectomy.

For cases in which nodularity in the posterior cul-de-sac and infiltration of the endometriosis toward the vagina are present, vaporization and dissection of the nodularity are continued as an assistant evaluates the nodule by palpation until it is gone.²⁵ This may require a small, partial vaginectomy. Should a small vaginal perforation occur, it can be left alone as long as the perforation is less than 1.0 cm. Endometriosis rarely penetrates the mucosa of the colon. However, endometriosis of the lower colorectal area commonly involves the serosa, subserosa, and muscularis of the bowel. This disease can be excised or vaporized very thoroughly by an experienced videolaseroscopist. The procedure is very demanding and requires maximal cooperation between the assistant and surgeon.

To detect possible rectal perforations, we use the sigmoidoscope, as described before, or inject indigo carmine into the rectum with a Foley catheter. Small perforations can be repaired laparoscopically with three to four interrupted 3-0 silk, 4-0 polydioxanone (Ethicon) sutures, or an Endoloop (Ethicon).^{36,80}

Patients may be discharged within 24 hours, except those who had bowel perforations or underwent bowel resection. Patients are instructed to have nothing by mouth for 24 hours, except for sips of water, and if no complications are noted, the diet is gradually increased. Patients with bowel perforation or resection are allowed nothing by mouth until they pass flatus and then are instructed to avoid constipation by eating a high fiber diet. The patients should be examined at 1 and 6 weeks postoperatively.⁸⁰

Bowel resection

In an effort to avoid laparotomy for patients requiring bowel resection, we have developed techniques for laparoscopic mobilization of the lower colon, transanal prolapse, resection, and reanastomosis.^{25,26} The patient has the preoperative mechanical bowel preparation described previously. He or she is placed in the modified lithotomy position, pneumoperitoneum is induced, and the laparoscope is inserted infraumbilically. Three 5.0 mm suprapubic trocars, one each in the midline and right and left lower quadrants, are used to place grasping forceps, Endoloop suture applicators, a suction-irrigator probe, and a bipolar electrocoagulator.

Following insertion of the laparoscope, the entire abdomen and pelvis are inspected visually. All major lesions should be laparoscopically biopsied. Endometrial lesions are systematically vaporized or excised with the CO₂ laser.

Endometriosis, which may invade deep into or through the muscularis propria of the rectum, often results in rectal stricture. With operative laparoscopic techniques described before, mobilize the entire rectum, and vaporize or excise lesions in the rectovaginal septum. The lateral rectal pedicles should be coagulated and the presacral space entered to the level of the levator ani muscles. In patients with anterior rectal lesions, the rectum is prolapsed via the anal canal and transected using two applications of an RL30 or RL60 stapler (Ethicon). Interrupted 2-0 vicryl sutures are used for reinforcement. In patients with circumferential lesions, the rectum is transected distal to the lesion, and the proximal limb is prolapsed into the distal limb, using Babcock clamps. (Figs. 12, 13). The rectal segment prolapsed through the anal canal is transected proximal to the lesion. The resected segment is sent for pathologic diagnosis, and a 2-0 polypropylene pursestring suture is placed around the circumference of the proximal limb of the bowel. The anvil of a 33 ILS stapler (Ethicon) is placed through the pursestring into the proximal bowel, and the proximal limb of bowel is replaced into the pelvis. Using Babcock clamps, the distal rectal segment is prolapsed through the anal canal and closed with an RL60, and the rectal stump is replaced through the anal canal into the pelvis. The ILS stapler is placed into the rectum, and the anvil trocar within the proximal bowel is inserted into the stapling device using the laparoscope. The device is fired, creating an end-to-end anastomosis (Fig. 14).

A proctoscope is used to inspect anastomosis for structural integrity and bleeding. Lactated Ringer's solution is inserted in the pelvis and visualized with the laparoscope as air is insufflated into the rectum to check for leakage. Air leaks may be corrected using transanally placed 2-0 vicryl sutures.

The laparoscopic bowel resection is identical to a laparotomy except that bipolar electrocoagulator and laser replace sutures and scissors. No unusual short-term or long-term ill effects are evident with this approach.^{25,26}

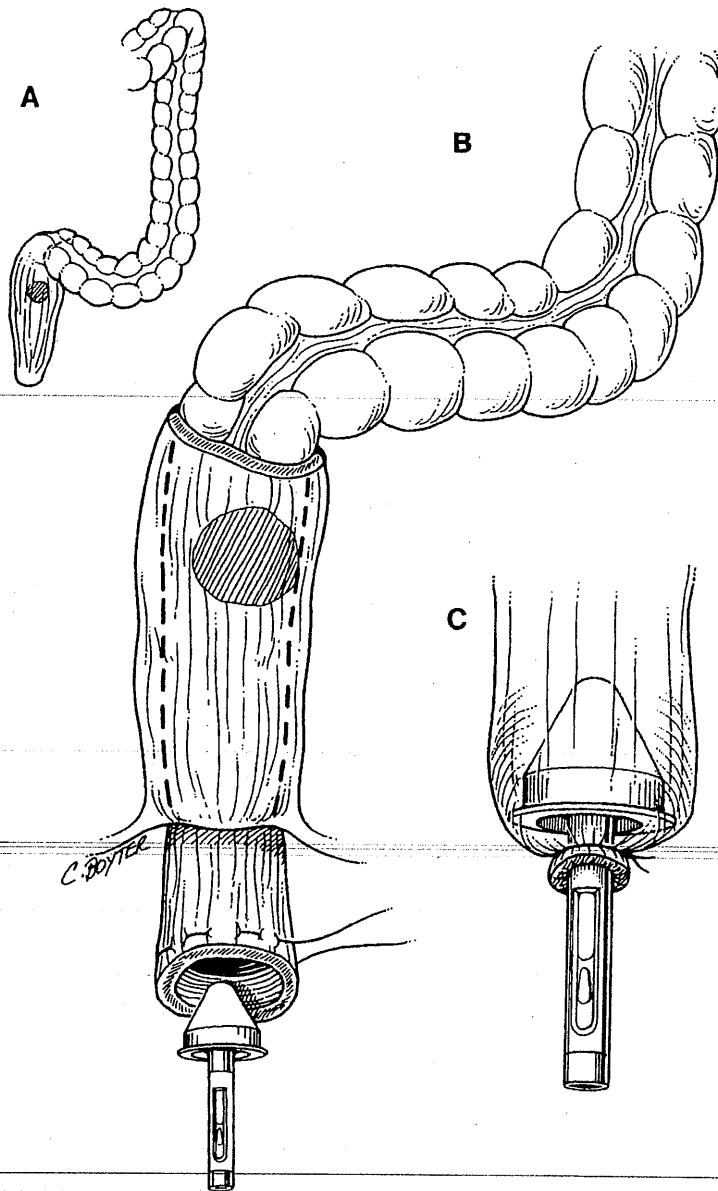


FIG. 12. — A. Fibrosis, narrowing and endometriosis of lower colon. B. Proximal colon has been prolapsed anally via the distal colon. Pursestring suture has been placed. C. Anvil of stapler is ready to be inserted.

TUBAL ADHESIOLYSIS AND HYDROSALPINGES

Using videolaseroscopy to lyse and remove peritubal adhesions has proven effective in preserving fertility, providing the anatomy of the lumen, including major and minor folds of the mucosa and cilia, has not been destroyed by disease.^{36,43} Fimbriostomy⁸¹ can be used to further evaluate the tubes intraoperatively. This is done by suspending the fimbria in fluid. The posterior cul-de-sac is filled with lactated Ringer's solution, and the 3 mm salpingoscope with video camera, to be used for evaluation, is introduced through one of the suprapubic portals or the operative channel of the laparoscope. The smaller scope magnifies folds of the fimbria, and agglutination or adhesions can be readily identified and incised with laser.

When tubal anatomy has been destroyed, the probability of conception is poor.^{43,82} Although an attempt should be made to repair even these tubes during operative laparoscopy, these patients eventually may become candidates for IVF-ET.

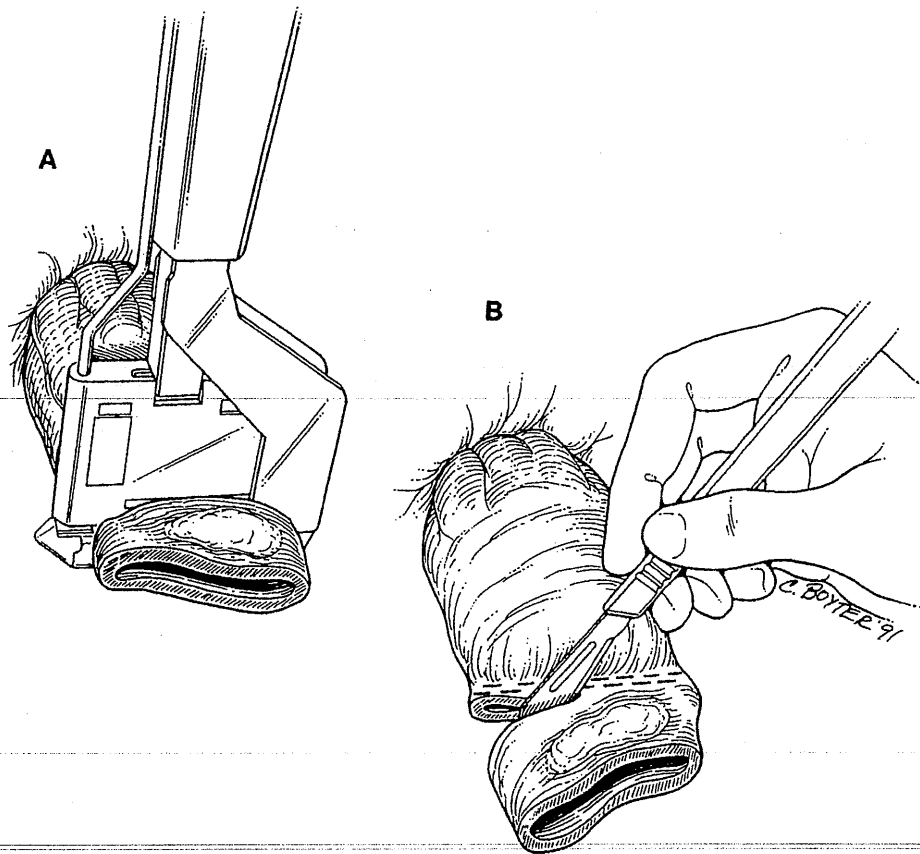


FIG. 13. A. RL60 (Ethicon, Somerville, NJ) is used to resect the lesion off the distal colon. B. A portion of colon is being removed.

If a hydrosalpinx is encountered, results of repair by operative laparoscopy are comparable to microsurgical laparotomy repair.⁸³ The distal end of the tube is distended with indigo carmine chromotubation and stabilized with two grasping forceps. Stellate incisions are made in the end of the tube using focused, high-power laser while carefully preserving all remaining fimbria. The edges of the neosalpingostomy must be everted to preserve tubal patency. Low-power laser applied circumferentially to the distal serosal surface causes serosal contraction and eversion of the mucosa. Sutures should be avoided unless absolutely necessary to keep the tube open, since they may increase adhesion formation.

In a study at our center of 62 women who underwent laparoscopic treatment for unilateral or bilateral hydrosalpinges (Group 1) and 69 who were treated for peritubal or periovarian adhesions or both (Group 2), the pregnancy rates were evaluated. The rates for Group 1 were highly affected by the condition of the tubal lumen. Of the 42 women in Group 1 who were followed for at least 12 months, 15 achieved pregnancy (13 intrauterine [30%] and 2 ectopic [5%]). In Group 2, 34 of the 45 patients followed for 12 months achieved intrauterine pregnancy.⁸⁴

When compared to reported pregnancy rates following laparotomy²⁰, the results by laparoscopy are more encouraging.

VAGINAL VAULT SUSPENSION (SACRAL COLPOPEXY)

The transabdominal approach of the presacral space is accomplished by means of instrumentation reviewed previously.^{25,26} In summary, the patient is placed into a deep Trendelenburg position and tilted to the left to move the bowel away from the operating field. The presacral space is entered using hydrodissection combined with the CO₂ laser set at 40–80 W through a peritoneal incision at the right pararectal area. The anatomic

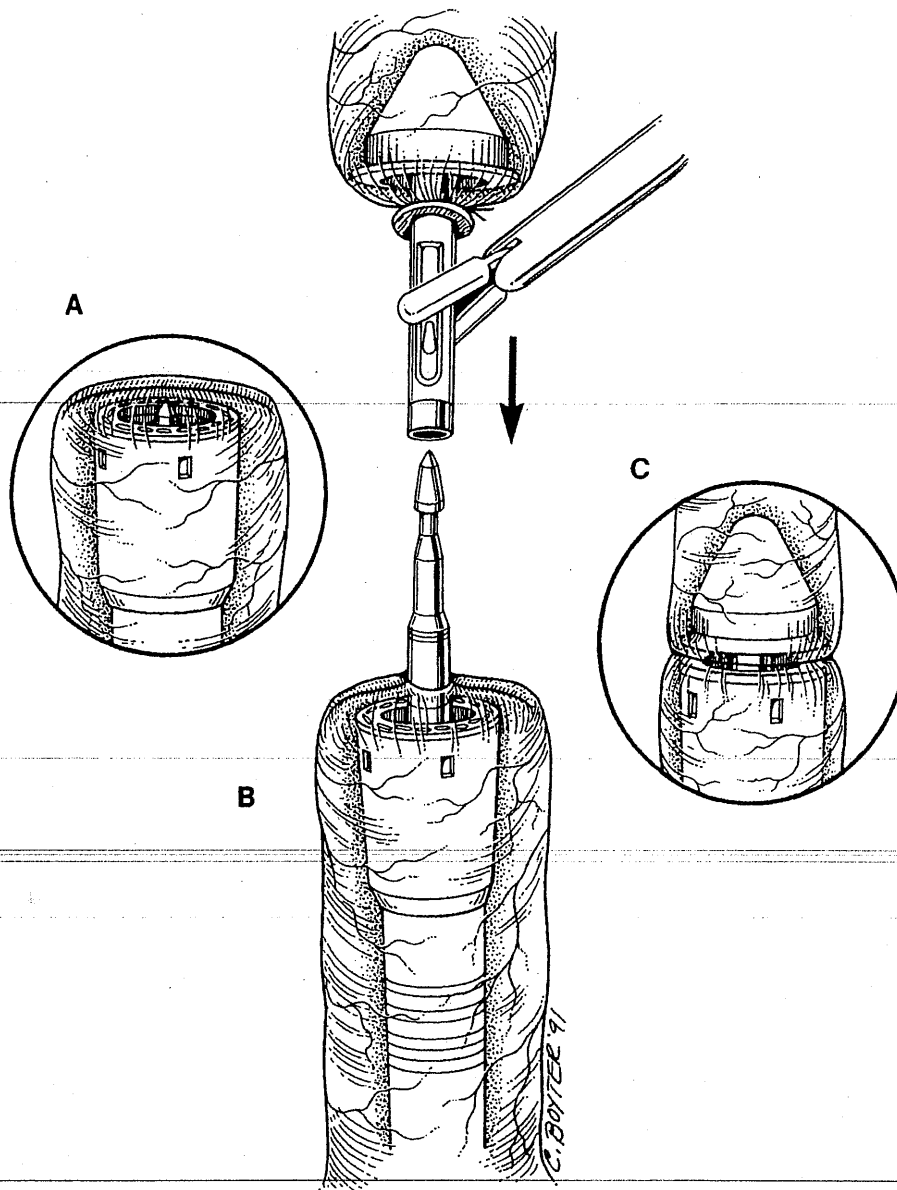


FIG. 14. A. Distal portion of colon is being placed into the pelvis. B. Distal and proximal portions of the bowel are being attached. C. Reanastomosis is complete.

landmarks that will aid in avoiding bowel, ureter, and vessel injury when identified are the right ureter, iliac artery and vein, descending colon, and presacral vessels.

The vaginal apex is held with grasping forceps. The vesical peritoneum over the vaginal apex is incised using the CO₂ laser and hydrodissection. The bladder is dissected from the anterior vaginal wall, and the rectum is dissected from the posterior vaginal wall. A 4 cm area of the vaginal wall is exposed.

If an enterocele is present in the upper posterior vaginal wall, the peritoneum lining of this defect can be excised and further obliterated by Moschowitz culdoplasty.²³ This procedure can be performed after completing sacral colpopexy, as the right pararectal space is freed and the vaginal wall is pulled toward the sacrum without placing undue pressure on the sigmoid colon. The central 5 mm trocar above the pubis bone is changed to a 10 mm trocar. The polypropylene mesh is rolled and introduced into the abdomen through the 10 mm suprapubic port.

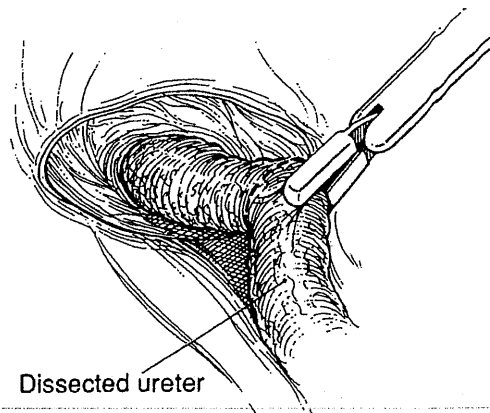


FIG. 15. Ureteral obstruction with nephrostomy tube placed. Ureterolysis has been performed.

Three to five 2-0 polypropylene sutures are placed in the thickness of the vaginal wall (not including the vaginal mucosa) at the apex in a single row from one lateral fornix to the other. Each suture is placed through one end of the polypropylene mesh and tied very loosely using extracorporeal tying. If it becomes necessary to remove a portion of the vaginal wall, the lower end of the mesh (Ethicon) can be attached vaginally. The vagina should be thoroughly cleansed prior to the procedure.

To enter the anterior sacrum, the posterior parietal peritoneum is lifted with grasping forceps, and the anterior sacral fascia is exposed. Extreme care should be taken to avoid injuring the presacral vessels. Two permanent sutures or staples (Laptack, Surgin Surgical, Placentia, CA) are placed in the periosteum of the sacrum approximately 1 cm apart in the midline over S3 and S4. The mesh should have enough tension to hold the vaginal apex in a normal position but should not be tight. The culdoplasty peritoneum is beneath or, at times, above the mesh strip, and the sigmoid colon should pass beneath the mesh strip without unnecessary compression.

To date, we have performed 5 vaginosacral colpopexies. Three patients also underwent Moschowitz culdoplasty, and 1 had bladder neck suspension. The results from our short-term follow-up are promising.

URETEROURETEROSTOMY

In patients with partial or complete ureteral obstruction that is unresponsive to medical therapy, ureteroureterostomy is necessary. We use the following technique for laparoscopic ureteroureterostomy.²⁷

A combination of hydrodissection⁴⁶ and the CO₂ is used to treat any associated lesions, such as endometriosis, fibrosis, or adhesions. Then, the ureter is dissected from surrounding tissues (Fig. 15). The proximal ureter is transected, and indigo carmine is injected into the patient's IV to confirm its patency. A 7F ureteral catheter is introduced cystoscopically into the distal ureter. The distal ureter is transected over the stent, and the obstructed portion of ureter is removed (Fig. 16). When this is complete, the ureteral stent is introduced into the proximal ureter and advanced into the renal pelvis (Figs. 17, 18). To perform anastomosis, four 4-0 PDS are placed in an interrupted fashion at 6, 12, 9, and 3 o'clock to approximate the proximal and distal ureteral edges (Fig. 19).

An external ureteral stent should be left in the ureter for a minimum of 4 weeks, at which time it is exchanged cystoscopically for an internal stent. This stent remains in place for approximately 2 months postoperatively. The patient's follow-up should include intravenous pyelogram, ultrasound, or excretion scans.

This technique also may be used to repair ureteral injuries.^{85,86}

COMPLICATIONS

We reviewed the files of 6012 patients who were evaluated between July 1982 and June 1992. The complications have been divided into intraoperative and postoperative categories (Tables 4 and 5). Rare postoperative complications included pulmonary edema (2 women), subcutaneous emphysema (6 women),

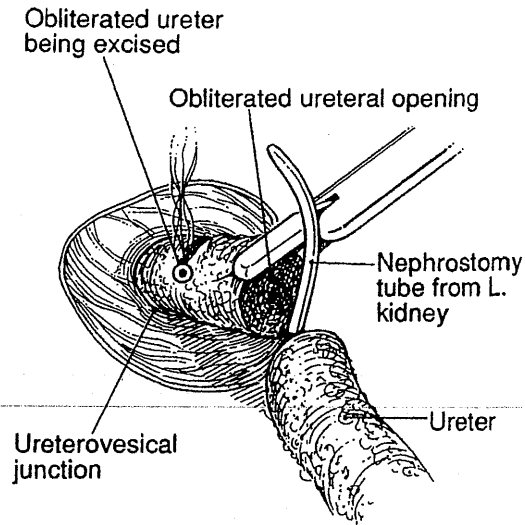


FIG. 16. Obstructed ureter is being resected. Nephrostomy tube can be seen.

small bowel ileus (2 women), pelvic infection (3 women) and deep vein thrombophlebitis (2 women). Minor postoperative complications were shoulder pain, subcutaneous ecchymosis, urinary tract infection, urine retention, and superficial wound infection. Intraoperative bleeding most commonly originated from the inferior epigastric vessels. Postoperative bleeding was noted primarily at trocar sites. In the last 4000 surgeries, laparotomy has not been necessary to control intraabdominal bleeding. Patients who had undergone previous laparotomies were at the highest risk for visceral injury. Injuries of the bowel, bladder, and ureter most often occurred in patients with severe endometriosis. It is imperative to remember that operative laparoscopy is associated with certain unavoidable complications, which necessitates a thorough knowledge of proper management for a patient's condition.

LIMITATIONS

Limitations to laparoscopy include the difficulty in manipulating solid masses > 20 cm, such as myomas, the possible dissemination of advanced intraperitoneal cancer resulting from laparoscopic manipulation, and the current limited availability of proper instrumentation, surgical teams, and skilled surgeons.

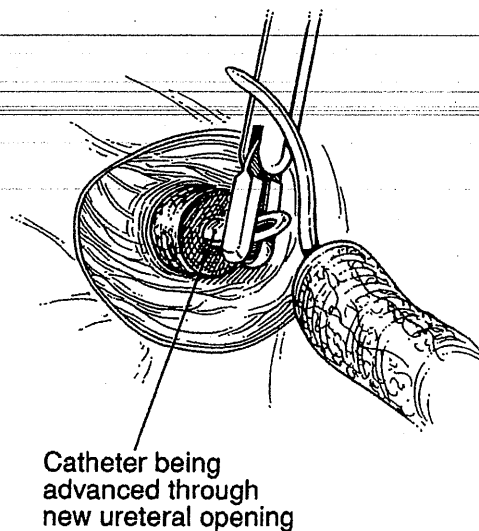


FIG. 17. Catheter being advanced through new ureteral opening via cystoscopy and passed to the proximal portion of the ureter.

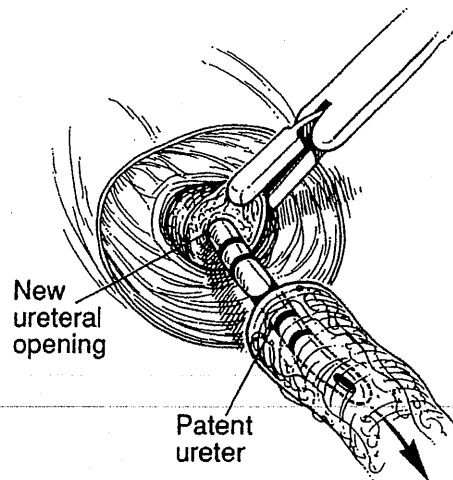


FIG. 18. New ureteral opening and patent ureter.

TABLE 4. INTRAOPERATIVE INJURIES/COMPLICATIONS

	Vascular injuries		Small bowel		Large bowel ^b		Bladder		Ureter	
	Anterior abdominal ^a	Intra-abdominal	Trocar	Intra-abdominal	Injuries	Entry	Injuries	Entry	Injuries	Entry
Laparotomy not required	109	1	2	10 ^c	3	22	1	2	2	4
Laparotomy required	0	3	4	0	0	1	1	0	0	0

^aIncludes inferior epigastric vessels.

^bIncludes colotomies (7) and rectotomies (8); the injury repaired by laparotomy was early in our experience.

^cOpen laparoscopy incision (2) and adhesiolysis (8).

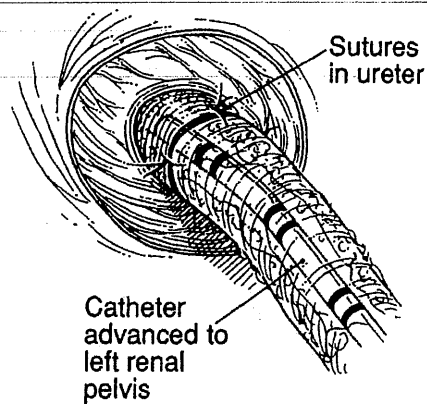


FIG. 19. Reanastomosis has been accomplished.

TABLE 5. POSTOPERATIVE INJURIES/COMPLICATIONS

	<i>Anterior abdominal wall bleeding</i>	<i>Intraabdominal bleeding</i>	<i>Small bowel injury</i>
Laparotomy not required	6 ^a	2 ^b	0
Laparotomy required	1	2	1 ^c

^aFive were managed laparoscopically; 1 was managed medically (transfusion, observation).

^bBleeding was due to mild Von Willebrand disease (1); at repeat laparoscopy, etiology was unknown (1).

^cBowel strangulation was due to congenital malrotation of the small bowel.

DISCUSSION

The minimal invasiveness of operative laparoscopy remains its most prominent benefit, playing the central role in its popularization. Operative videolaparoscopy offers several other benefits over an open procedure. The video magnification of anatomy allows the most tedious procedures to be performed microsurgically. The superior visualization of the posterior cul-de-sac, posterior broad ligament and upper abdomen using this technique cannot be disputed. Further, the surgeon's eyes are within millimeters to centimeters from the tissue (via the videoscope).

The hemostasis achieved with the pressure from the pneumoperitoneum significantly adds to intraoperative exposure. In addition, *de novo* adhesion formation is at least markedly decreased, if not eliminated, with the use of laparoscopy.^{31,32}

While operative laparoscopy has been shown to be an excellent alternative to laparotomy for many procedures, some have called for randomized studies of the two methods.⁸⁷ Studies of this nature would provide useful statistics. However, in order for the results to be valid, the surgeon must be proficient with both laparotomy and operative laparoscopy, and must actively use both on his or her patients. We suggest that in a number of instances this is unethical. For procedures that require delicate dissection, laparoscopy is a better approach.⁸⁸ Once a surgeon is competent in operative laparoscopy, why perform laparotomy for the sake of statistical analysis, subjecting the patient to longer hospitalization, recuperation, more pain, and more expense?

The lightning-fast development of laparoscopy and its increasing popularity have created new dilemmas. At the same time, the old obstacles have not been overcome. Responding to popular demand, an increasing number of physicians are actively acquiring laparoscopic skills. Public pressure frequently results in inadequately trained surgeons attempting difficult laparoscopic procedures. In turn, this leads to an unacceptable increase in operative laparoscopic complications.⁸⁸ Video endoscopic procedures lack the three-dimensional perspective present with laparotomy. Successful utilization of videolaparoscopy requires that the previously trained surgeon relearn his or her operating skills. The time necessary to acquire the ability to perform advanced operative laparoscopy is typically at least as long as that for laparotomy.

Cost effectiveness was a significant presumed benefit. At the present time, however, hospital costs associated with most operative laparoscopies, despite decreased postoperative hospitalization, continue to be higher than the costs associated with laparotomy. To compensate for the drop in revenue from a decrease in inpatient room utilization, many hospitals have increased the fees for their outpatient facilities. Also, the hospitals have increased their profit margins on the already expensive instrumentation and technology.

Specifically, the use of disposable instruments adds significantly to the total cost of a procedure.⁸⁹ As an example, automatic stapling devices have emerged as a convenient time-saver, but as they are disposable, they increase cost. The expense associated with disposable stapling devices may not be justifiable, when the same results can be accomplished with bipolar electrocoagulation, or with sutures combined with widely available cutting instruments. Reusable instruments should be included in the procedure whenever possible.⁹⁰

Another reason for unrealized cost savings is the increased operative time associated with laparoscopy. The problem of prolonged operative time is exacerbated by the frequently inadequate skills of the surgeons.

Although some extension in operative time is to be expected, it may be reduced by the development of new instrumentation and by the surgeon's acquisition of advanced operative skills.

The future of operative laparoscopy rests on its widespread acceptance by the academic centers responsible for resident education. The upcoming generation of surgeons can be taught endoscopic techniques earlier in their training, allowing better assimilation of the difficult hand-eye coordination necessary for videolaparoscopy. Likewise, the laparoscopic frontier will be extended with the development of instrumentation that is easier to manipulate, improving the outcome and shortening operative time. New procedures may be extended to areas previously off-limits to endoscopy; for example, we have recently performed a coronary bypass on a porcine model. It is becoming apparent that the predominate limitation to operative laparoscopy is the surgeon's imagination.

ACKNOWLEDGMENT

We gratefully acknowledge the advice, support, and editorial assistance of Clayton S. White, M.D., of Albuquerque, New Mexico and the editorial assistance of Oleg Bess, M.D., Atlanta, GA.

REFERENCES

1. Gomel V. Operative laparoscopy: Time for acceptance. *Fertil Steril* 1989;52:1.
2. Gomel V. Salpingostomy by laparoscopy. *J Reprod Med* 1977;18:265.
3. Mettler L, Giesel H, Semm K. Treatment of female infertility due to tubal obstruction by operative laparoscopy. *Fertil Steril* 1979;32:384.
4. Leventhal JM, Simon LR, Shapiro SS. Laparoscopic removal of intrauterine contraceptive devices following perforation. *Am J Obstet Gynecol* 1971;111:102.
5. Bruhat MA, Mage G, Manhes H, Pouly JL. Treatment of ectopic pregnancy by means of laparoscopy. *Fertil Steril* 1980;33:411.
6. Bruhat M, Mage G, Manhes M. Use of the CO₂ laser via laparoscopy. In: Kaplan I, ed. *Laser surgery III, Proceeding of the 3rd International Society for Laser Surgery*. Tel Aviv: International Society for Laser Surgery, 1979:175.
7. Tadir Y, Kaplan I, Zuckerman Z, Edelstein T, Ovadia J. New instrumentation and technique for laparoscopic carbon dioxide laser operations: A preliminary report. *Obstet Gynecol* 1984;63:582.
8. Baggish MS, ElBakry MM. A flexible CO₂ laser fiber for operative laparoscopy. *Fertil Steril* 1986;46:16.
9. Baggish MS, Baltoyannis P, Badawy S, Laurey D. Carbon dioxide laser laparoscopy performed with a flexible fiber in humans. *Am J Obstet Gynecol* 1987;157:1129.
10. Lomano JM. Laparoscopic ablation of endometriosis with the YAG laser. *Lasers Surg Med* 1983;3:179.
11. Nezhat C, Winer WK, Nezhat F. A comparison of the CO₂, argon, and KTP-532 lasers in the videolaseroscopic treatment of endometriosis. *Colposc Gynecol Laser Surg* 1988;4:41.
12. Keye WR Jr., Hansen LW, Astin M, Poulson AM Jr. Argon laser therapy of endometriosis: A review of 92 consecutive patients. *Fertil Steril* 1987;47:208.
13. Daniell JF, Miller W, Tosh R. Initial evaluation of the use of the potassium-titanyl-phosphate (KTP-532) laser in gynecologic laparoscopy. *Fertil Steril* 1986;46:373.
14. Nezhat C. Videolaseroscopy: A new modality for the treatment of endometriosis and other diseases of reproductive organs. *Colposc Gynecol Laser Surg* 1986;2:221.
15. Kott DF. Photography, cinematography and television in endoscopy. In: Phillips JM, ed. *Endoscopy in gynecology*. Downey, CA: American Association of Gynecologic Laparoscopists 1978:487.
16. Yuzpe AA. Television in laparoscopy. In: Phillips JM, Corson SL, Keith L, et al., eds. *Laparoscopy*. Baltimore: Williams & Wilkins, 1977:306.
17. Anonymous. Videolaseroscopy for endometriosis care. *Obstet Gynecol News* 1986; November 15-30:41.
18. Nezhat C, Crowgey SR, Garrison CP. Surgical treatment of endometriosis via laser laparoscopy. *Fertil Steril* 1986;45:778.

19. Nezhat C, Crowgey S, Nezhat F. Videolaserectomy for the treatment of endometriosis associated with infertility. *Fertil Steril* 1989;51:237.
20. Nezhat C, Nezhat F. Incidental appendectomy during videolaserectomy. *Am J Obstet Gynecol* 1991;165:559.
21. Nezhat F, Nezhat C, Silfen SL. Videolaserectomy for oophorectomy. *Am J Obstet Gynecol* 1991;165:1323.
22. Nezhat C, Nezhat F, Winer W. Salpingectomy via laparoscopy: A new surgical approach. *J Laparosc Surg* 1991;1:91.
23. Nezhat C, Nezhat F, Gordon S, Wilkins E. Laparoscopic versus abdominal hysterectomy. *J Reprod Med* 1992;37:247.
24. Nezhat C, Burrell MO, Nezhat FR, Benigno BB, Welander CE. Laparoscopic radical hysterectomy with para-aortic and pelvic node dissection. *Am J Obstet Gynecol* 1992;166:864.
25. Nezhat C, Pennington E, Nezhat F, Silfen SL. Laparoscopically assisted anterior rectal wall resection and reanastomosis for deeply infiltrating endometriosis. *Surg Laparosc Endosc* 1991;1:106.
26. Nezhat F, Nezhat C, Pennington E. Laparoscopic proctectomy for infiltrating endometriosis of the rectum. *Fertil Steril* 1992;57:1129.
27. Nezhat C, Green B, Welander C, Nezhat F. Laparoscopic treatment of obstructed ureter due to endometriosis by resection and ureteroureterostomy. A case report. *J Urol* 1992;148:865.
28. Wallis C. The career woman's disease? *Time* 1986; April 28:62.
29. Clark M, Carroll G. Conquering endometriosis. *Newsweek* 1986; October 13:95.
30. Cowley G. Hanging up the knife. *Newsweek*; 1990; February 12:58.
31. Nezhat C, Nezhat F, Metzger DA, Luciano AA. Adhesion reformation after reproductive surgery by videolaserectomy. *Fertil Steril* 1990;53:6:1008.
32. Operative Laparoscopy Study Group. Postoperative adhesion development after operative laparoscopy: Evaluation at early second-look procedures. *Fertil Steril* 1991;55:700.
33. Nezhat C, Nezhat F, Silfen SL. Videolaserectomy: The CO₂ laser for advanced operative laparoscopy. *Obstet Gynecol Clin North Am* 1991;18:3:585.
34. Nezhat FR, Silfen SL, Evans D, Nezhat C. Comparison of direct insertion of disposable and standard reusable laparoscopic trocars and previous pneumoperitoneum with veress needle. *Obstet Gynecol* 1991;78:148.
35. Semm K. Operative manual for endoscopic abdominal surgery. Chicago: Year Book Medical Publishers, 1987.
36. Nezhat C, Nezhat SL, Nezhat F, Martin D. Surgery for endometriosis. *Curr Op Obstet Gynecol* 1991;3:385.
37. Smith MS. Cystostomy and vesicostomy. In: Glenn JF, ed. *Urologic surgery*, 4th ed. Philadelphia: Lippincott, 1991.
38. Nezhat F, Nezhat C. Laparoscopic segmental bladder resection for endometriosis: A report of two cases. *Obstet Gynecol* (in press).
39. DeCherney A, Diamond MP. Laparoscopic salpingostomy for ectopic pregnancy. *Obstet Gynecol* 1987;70:948.
40. Stangel JJ, Gomel V. Techniques in conservative surgery for tubal gestation. *Clin Obstet Gynecol* 1980;23:1221.
41. Nezhat C, Nezhat F. Conservative management of ectopic gestation (Letter to the Editor). *Fertil Steril* 1990;53:382.
42. Nezhat C, Nezhat F, Silfen SL. Laparoscopic hysterectomy and bilateral salpingo-oophorectomy using multifire GIA surgical stapler. *J Gynecol Surg* 1990;6:287.
43. Nezhat C, Winer WK, Nezhat F, Nezhat CH. Videolaparoscopy and videolaserectomy: Alternatives to major surgery? *Female Patient* 1988;13:46.
44. Nezhat C, Nezhat F, Burrell M. Laparoscopically assisted hysterectomy for the management of a borderline ovarian tumor: A case report. *J Laparoendosc Surg* 1992;2:167.
45. Summit RL, Stovall TG, Ling FW, Lipscomb GH. Laparoscopic-assisted vaginal hysterectomy using endoscopic staples. American College of Obstetricians and Gynecologists, 40th Annual Clinical Meeting, April 25-30, 1992, Las Vegas, Nevada.
46. Nezhat C, Nezhat F. Safe laser excision or vaporization of peritoneal endometriosis. *Fertil Steril* 1989;52:1:149.
47. Canis M, Mage G, Wattiez A, Pouly JL, Chapron C, Bruhat MA. Vaginally assisted laparoscopic radical hysterectomy. *J Gynecol Surg* 1992;8:103.

48. Photopoulos GJ, Stovall TG, Summitt RL. Laparoscopic-assisted hysterectomy, bilateral salpingo-oophorectomy, and pelvic lymph node sampling for endometrial cancer. *J Gynecol Surg* 1992;8:91.
49. Nezhat C, Nezhat F, Welander CE, Benigno B. Four ovarian cancers diagnosed during laparoscopic management of 1,011 adnexal masses. *Am J Obstet Gynecol* 1992;167:790.
50. D'argent D, Salvat J. L'envahissement ganglionnaire pelvien. Paris: MEDSI, 1989.
51. Querleu D, Leblanc E, Castelain B. Laparoscopic pelvic lymphadenectomy in staging of early carcinoma of the cervix. *Am J Obstet Gynecol* 1991;164:579.
52. Nezhat C. Tenth Annual Baltimore-Washington Seminar & Tutorial, December 13-15, 1989.
53. Nezhat C. Gynecologic laser surgery: State of the art for the '90s, University of Connecticut, October 5-6, 1990.
54. Nezhat C. New developments in operative hysterectomy. Second Workshop on Operative and Videolaserlaparoscopy, Vrije Universiteit, October 25-26, 1990, Brussels, Belgium.
55. Nezhat C. Advanced laparoscopic and laser surgery. Second Workshop on Operative and Videolaserlaparoscopy, Vrije Universiteit, October 25-26, 1990, Brussels, Belgium.
56. Nezhat F, Nezhat C. Setup for operative laparoscopy and videolaseroscopy. *Contemp Obstet Gynecol* 1992;36:50.
57. Burch JC. Cooper's ligament urethrovesical suspension for stress incontinence—Nine years' experience: Results, complications, technique. *Am J Obstet Gynecol* 1968;100:764.
58. Vancaillie TG, Schuessler W. Laparoscopic bladder neck suspension. *J Laparoendosc Surg* 1991;1:169.
59. Nezhat C, Nezhat F, Silfen SL, Schaffer N, Evans D. Laparoscopic myomectomy. *Int J Fertil* 1991;36:275.
60. Nezhat C. Laparoscopic myomectomy (Letter to the Editor). *Int J Fertil* 1992;37:64.
61. Harris WJ. Uterine dehiscence following laparoscopic myomectomy. *Obstet Gynecol* 1992;80:545.
62. Maimon M, Seltzer V, Boyce J. Laparoscopic excision of ovarian neoplasms subsequently found to be malignant. *Obstet Gynecol* 1991;77:563.
- 62a. Parker WH, Berek JS. Management of selected cystic adnexal masses in postmenopausal women by operative laparoscopy: a pilot study. *Am J Obstet Gynecol* 1990;163:1574.
63. Nezhat C, Nezhat F. Operative laparoscopy for the management of ovarian remnant syndrome. *Fertil Steril* 1992;57:1003.
64. Davis GD, Hruby PH. Transabdominal laser colpotomy. *J Reprod Med* 1989;34:438.
- 64a. Nezhat C, Winer W, Nezhat F. Laparoscopic removal of dermoid cysts. *Obstet Gynecol* 1989;73:278.
65. Semm K, Mettler L. Technical progress in pelvic surgery via operative laparoscopy. *Am J Obstet Gynecol* 1980;138:121.
66. Nezhat F, Nezhat C, Silfen S, Fehnel S. Laparoscopic ovarian cystectomy during pregnancy. *J Laparoendosc Surg* 1991;1:161.
67. Nezhat C, Winer WK, Nezhat F. Is endoscopic treatment of endometriosis and endometrioma associated with better results than laparotomy? *Am J Gynecol Health* 1988;2:3:10.
68. Hasson HM. Laparoscopic management of ovarian cysts. *J Reprod Med* 1990;25:863.
69. Fayed JA, Vogel MP. Comparison of different treatment methods of endometriomas by laparoscopy. *Obstet Gynecol* 1991;78:660.
70. Buttram VC. Use of danazol in conservative surgery. *J Reprod Med* 1990;35:82.
71. Nezhat C, Winer WK, Cooper JD, Nezhat F, Nezhat C. Endoscopic infertility surgery. *J Reprod Med* 1989;34:2:127.
72. Nezhat C, Nezhat F. Postoperative adhesion formation after ovarian cystectomy with and without ovarian reconstruction. Presented at the 75th Annual Meeting of the American Fertility Society, Orlando, FL, October 19-24, 1991.
73. Nezhat F, Nezhat C, Allan CJ, Metzger DA, Sears DL. A clinical and histologic classification of endometriomas: implications for a mechanism of pathogenesis. *J Reprod Med* 1992;37:771.
74. Nezhat C, Nezhat F, Ambroze W, Pennington E. Laparoscopic repair of small bowel, colon, and rectal endometriosis: a report of twenty-six cases. *Surg Endosc*, in press.
75. Nezhat C. Videolaseroscopy for the treatment of endometriosis. In: Studd J, ed. *Progress in obstetrics and gynaecology*, 7th ed. Edinburgh: Churchill Livingstone, 1989:293.

76. Rock JA. Laparoscopic cautery in the treatment of endometriosis-related infertility. *Fertil Steril* 1991;55:246.
77. Nezhat C, Nezhat F. A simplified method of laparoscopic presacral neurectomy for the treatment of central pelvic pain due to endometriosis. *Br J Obstet Gynecol* 1992;99:659.
78. Tjaden B, Schlaff WD, Kimball A, Rock JA. The efficacy of presacral neurectomy for the relief of midline dysmenorrhea. *Obstet Gynecol* 1990;76:89.
79. Coronado C, Franklin RR, Lotze EC, Bailey HR, Valdes CT. Surgical treatment of symptomatic colorectal endometriosis. *Fertil Steril* 1990;53:411.
80. Nezhat C, Nezhat F, Pennington E. Laparoscopic treatment of lower colorectal and infiltrative rectovaginal septum endometriosis by the technique of videolaseroscopy. *Br J Obstet Gynaecol* 1992;99:664.
81. Nezhat F, Winer WK, Nezhat C. Fimbriectomy and salpingoscopy in patients with minimal to moderate pelvic endometriosis. *Obstet Gynecol* 1990;75:15.
82. De Bruyne F, Putteman P, Boecks W, Brosens I. The clinical value of salpingoscopy in tubal infertility. *Fertil Steril* 1989;51:339.
83. Leventhal JM. Tubal reconstructive surgery. In: Salfilippo JS, Levine RL, eds. *Operative gynecologic endoscopy*. New York: Springer-Verlag, 1989;148.
84. Nezhat C, Nezhat F. Advanced videolaparoscopy and videolaseroscopy. In: Templeton AA, Drife JO, eds. *Infertility*. London: Springer-Verlag 1992, 203-204.
85. Gomel V, James C. Intraoperative management of ureteral injury during operative laparoscopy. *Fertil Steril* 1991;55:416.
86. Nezhat C, Nezhat F. Laparoscopic repair of resected ureter during operative laparoscopy to treat endometriosis. A case report. *Obstet Gynecol* 1992;80:543.
87. Gant NF. Infertility and endometriosis: Comparison of pregnancy outcomes with laparotomy versus laparoscopic techniques. *Am J Obstet Gynecol* 1992;166:1072.
88. Garry R. Laparoscopic alternatives to laparotomy: A new approach to gynaecological surgery. *Br J Obstet Gynaecol* 1992;99:629.
89. Baggish M. The most expensive hysterectomy. *J Gynecol Surg* 1992;8:57.
90. Baggish M, Nezhat C. The medical industrial complex. *J Gynecol Surg* 1992;8:111.

Address reprint requests to:

Camran Nezhat, M.D.
555 Peachtree Dunwoody Road, N.E.
Suite 276
Atlanta, GA 30342

This article has been cited by:

1. K. ZAKASHANSKY, L. CHUANG, H. GRETZ, N.P. NAGARSHETH, J. RAHAMAN, F.R. NEZHAT. 2007. A case-controlled study of total laparoscopic radical hysterectomy with pelvic lymphadenectomy versus radical abdominal hysterectomy in a fellowship training program. *International Journal of Gynecological Cancer* 17:5, 1075-1082. [CrossRef]
2. Ceana H. Nezhat, Farr Nezhat, Daniel S. Seidman, Fariba Nasserbakht, Camran Nezhat, Michael Roemisch. 1996. A New Method for Laparoscopic Access to the Space of Retzius During Retropubic Cystourethropexy. *The Journal of Urology* 1916-1918. [CrossRef]
3. BRENT W. BOST. 1995. Assessing the Impact of Introducing Laparoscopically Assisted Vaginal Hysterectomy into a Community-Based Gynecology PracticeAssessing the Impact of Introducing Laparoscopically Assisted Vaginal Hysterectomy into a Community-Based Gynecology Practice. *Journal of Gynecologic Surgery* 11:2, 71-78. [Abstract] [PDF] [PDF Plus]
4. Camran Nezhat, Farr Nezhat, Nelson N. H. Teng, Babak Edraki, Ceana H. Nezhat, Matthew O. Burrell, Benedict B. Benigno, Carlos E. Ramirez. 1994. The role of laparoscopy in the management of gynecologic malignancy. *Seminars in Surgical Oncology* 10:6, 431-439. [CrossRef]
5. CAMRAN NEZHAT, FARR NEZHAT, CEANA NEZHAT. 1994. Operative Laparoscopy. *Annals of the New York Academy of Sciences* 734:1 The Human End, 433-444. [CrossRef]
6. MURRAY JOSEPH CASEY, JORGE GARCIA-PADIAL, CELESTE JOHNSON, NEWTON G. OSBORNE, JORGE SOTOLONGO, PATRICE WATSON. 1994. A Critical Analysis of Laparoscopic Assisted Vaginal Hysterectomies Compared with Vaginal Hysterectomies Unassisted by Laparoscopy and Transabdominal Hysterectomies*A Critical Analysis of Laparoscopic Assisted Vaginal Hysterectomies Compared with Vaginal Hysterectomies Unassisted by Laparoscopy and Transabdominal Hysterectomies*. *Journal of Gynecologic Surgery* 10:1, 7-14. [Abstract] [PDF] [PDF Plus]
7. CAMRAN R. NEZHAT, FARR R. NEZHAT, MATTHEW O. BURRELL, CARLOS E. RAMIREZ, CHARLES WELANDER, JESUS CARRODEGUAS, CEANA H. NEZHAT. 1993. Laparoscopic Radical Hysterectomy and Laparoscopically Assisted Vaginal Radical Hysterectomy with Pelvic and Paraaortic Node DissectionLaparoscopic Radical Hysterectomy and Laparoscopically Assisted Vaginal Radical Hysterectomy with Pelvic and Paraaortic Node Dissection. *Journal of Gynecologic Surgery* 9:2, 105-120. [Abstract] [PDF] [PDF Plus]
8. CAMRAN NEZHAT, FARR NEZHAT, OLEG BESS, CEANA H. NEZHAT. 1993. Injuries Associated with the Use of a Linear Stapler During Operative Laparoscopy: Review of Diagnosis, Management, and PreventionInjuries Associated with the Use of a Linear Stapler During Operative Laparoscopy: Review of Diagnosis, Management, and Prevention. *Journal of Gynecologic Surgery* 9:3, 145-150. [Abstract] [PDF] [PDF Plus]
9. FRED M. HOWARD, REINALDO SANCHEZ. 1993. A Comparison of Laparoscopically Assisted Vaginal Hysterectomy and Abdominal HysterectomyA Comparison of Laparoscopically Assisted Vaginal Hysterectomy and Abdominal Hysterectomy. *Journal of Gynecologic Surgery* 9:2, 83-90. [Abstract] [PDF] [PDF Plus]
10. CAMRAN NEZHAT, FARR NEZHAT, CEANA NEZHAT. 1992. Operative Laparoscopy (Minimally Invasive Surgery): State of the ArtOperative Laparoscopy (Minimally Invasive Surgery): State of the Art. *Journal of Gynecologic Surgery* 8:3, 111-141. [Abstract] [PDF] [PDF Plus]
11. CAMRAN NEZHAT, FARR NEZHAT. 1992. Laparoscopic Surgery with a New Tuned High-Energy Pulsed CO2 LaserLaparoscopic Surgery with a New Tuned High-Energy Pulsed CO2 Laser. *Journal of Gynecologic Surgery* 8:4, 251-255. [Abstract] [PDF] [PDF Plus]