

LAPAROSCOPIC TREATMENT OF OBSTRUCTED URETER DUE TO ENDOMETRIOSIS BY RESECTION AND URETEROURETEROSTOMY: A CASE REPORT

CAMRAN NEZHAT,* FARR NEZHAT AND BRUCE GREEN

From the Department of Obstetrics and Gynecology, Mercer University School of Medicine, Macon and Center for Special Pelvic Surgery, Atlanta, Georgia

ABSTRACT

Partial ureteral resection and ureteroureterostomy were accomplished using operative laparoscopy in a 36-year-old woman with a long-standing history of endometriosis, left ureteral obstruction and nephrostomy.

KEY WORDS: ureteral obstruction; ureterostomy; peritoneoscopy; nephrostomy, percutaneous; endometriosis

An exciting and rapidly developing new area of pelvic surgery involves using operative video laparoscopy to accomplish complex pelvic dissection.¹⁻⁷ One of the common diagnoses detected and treated with operative laparoscopy is endometriosis. As endometriosis becomes more advanced, the ureter is vulnerable to involvement by endometriotic implants. Stanley et al reported variable ureteral and bladder involvement in 1 to 11% of women diagnosed with endometriosis.⁸ Rivlin et al reported their experience using preoperative leuprolide in 3 patients with ureteral obstruction due to endometriosis.⁹ They noted improvement in 2 patients who had extrinsic involvement at operation but treatment failed in 1 with intrinsic ureteral endometriosis. They caution that if preoperative medical therapy is contemplated in cases of ureteral obstruction, close surveillance of renal function is mandatory.

A patient with an established diagnosis of endometriosis that was causing ureteral obstruction presented to our clinic. She had refused previous recommendations for conventional surgical correction of the ureteral obstruction. The question was raised as to whether new operative laparoscopic techniques would be applicable to correction of the ureteral obstruction. We report on laparoscopic ureteral resection and ureteroureterostomy for the treatment of an obstructed ureter due to intrinsic and extrinsic ureteral endometriosis.

CASE REPORT

A 36-year-old woman, gravida 0, presented with left ureteral obstruction more than 4 years in duration. The patient had a history of pelvic pain and underwent diagnostic laparoscopy elsewhere 4 years before admission to our hospital. Findings at that time apparently revealed stage 2 (acid-fast smear) endometriosis and partial obstruction of the left ureter. An excretory urogram (IVP) confirmed partial ureteral obstruction and hydronephrosis, and a left nephrostomy tube was placed (fig. 1). Later, complete obstruction of the ureter developed. Since that time the patient took no medication and emphatically refused any surgical therapy for the endometriosis. After consulting numerous physicians during the last 4 years, she elected to attempt surgical management of the endometriosis and ureteral obstruction by operative laparoscopy.

Physical examination revealed a normotensive woman, with a left nephrostomy tube apparent. Pelvic examination was normal except for marked left posterior cul-de-sac nodularity. The day before hospitalization an attempt to place an antegrade ureteral stent was unsuccessful. Antegrade injection through the nephrostomy tube revealed no contrast material in the

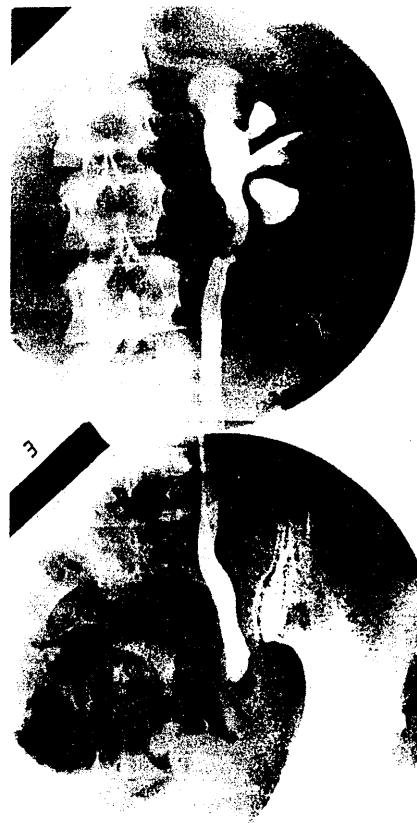

FIG. 1. Ureteral obstruction with nephrostomy tube placed

ureter below the pelvic brim. An antegrade stent was inserted down to the level of the obstruction and left in place during the laparoscopic procedure. Laparoscopy was done by experienced operative laparoscopists (C. N. and F. N.).

After induction of general endotracheal anesthesia, a laparoscope with video camera and 3 suprapubic portals was placed. Inspection of the pelvis revealed a normal uterus, tubes and ovaries. A 3 to 4 cm. fibrotic nodule on the left ureter, approximately 4 cm. above the bladder, distorted the ureteral course and corresponded to the level of obstruction. A cystoscopic attempt to place a retrograde catheter revealed the obstruction to be just above the ureterovesical junction. Because the ne-

Accepted for publication February 7, 1992.

* Requests for reprints: 5555 Peachtree Dunwoody Rd., N.E., Suite 276, Atlanta, Georgia 30342.

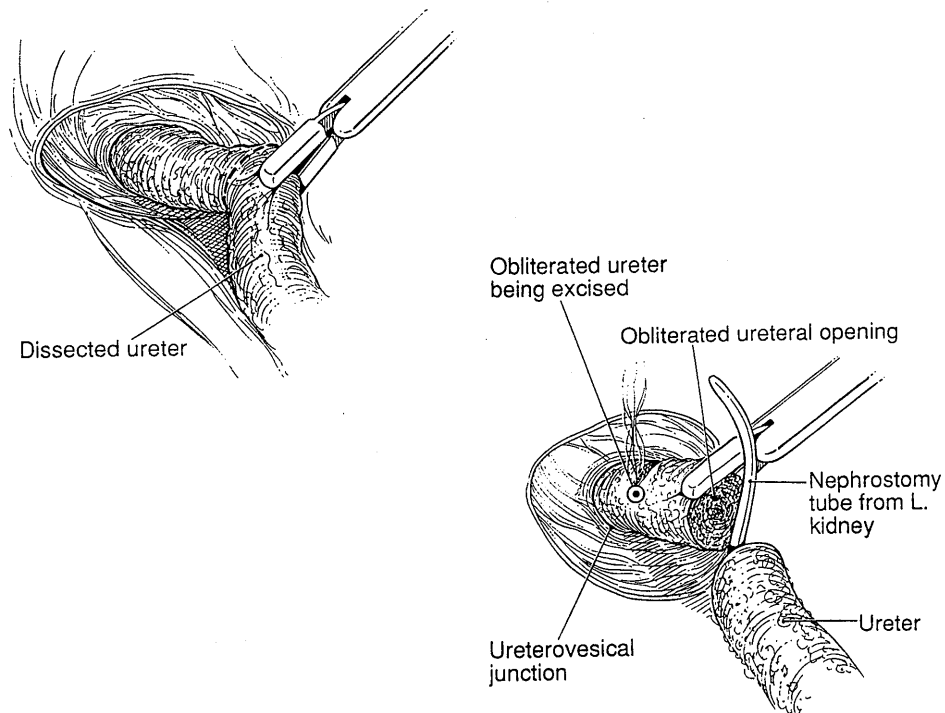


FIG. 2. Ureterolysis has been performed and obstructed ureter is being resected. Nephrostomy tube can be seen

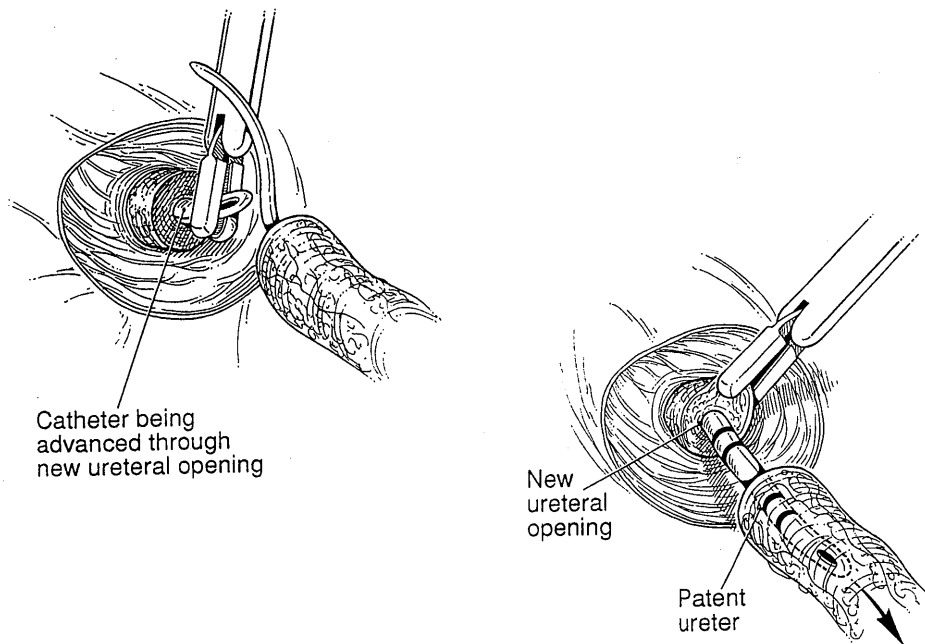


FIG. 3. Catheter is advanced through new ureteral opening via cystoscopy and passed to proximal portion of ureter

phrostomy tube was already present, it was decided that the ureteral nodule should be excised.

With the technique of hydrodissection,¹⁰ the left retroperitoneal space was entered at the pelvic brim and the ureter was dissected free. A carbon dioxide laser at 40 to 100 watts power was used for cutting tissue, and a carbon dioxide laser and bipolar cautery were used for coagulation.^{2,5-7} During dissection the nodule proved to involve the entire thickness of the ureter. The ureter was entered and antegrade indigo carmine injection confirmed a patent proximal ureter. Cystoscopy was performed, and while the left ureteral orifice could be visualized the catheter could not be passed to the point at which the ureter had

been incised. A total occlusion above the intramural section of the ureter was suspected. A 7F catheter was passed through the ureterovesical junction to the site of the obstruction under cystoscopic and laparoscopic guidance (fig. 2). The impression of the ureteral catheter could be visualized through the laparoscope. The carbon dioxide laser was then used to enter the distal segment of the ureter, exposing the ureteral catheter. The catheter was pulled through the proximal portion of the ureter up to the left renal pelvis (fig. 3). Finally, the edges of the ureter were approximated over the ureteral catheter using 4 through-and-through interrupted 4-zero polydioxanone sutures at the 6, 3, 9 and 12 o'clock positions. These sutures were

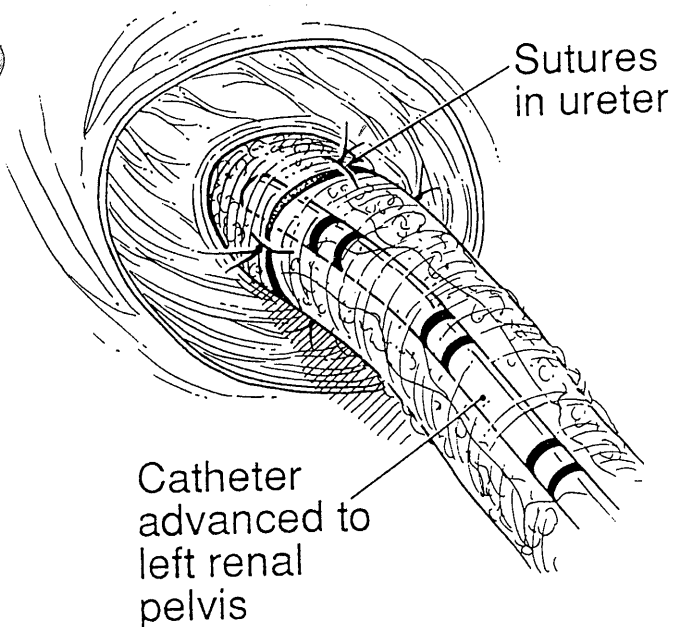


FIG. 4. New ureteral opening and patent ureter. Reanastomosis has been accomplished.

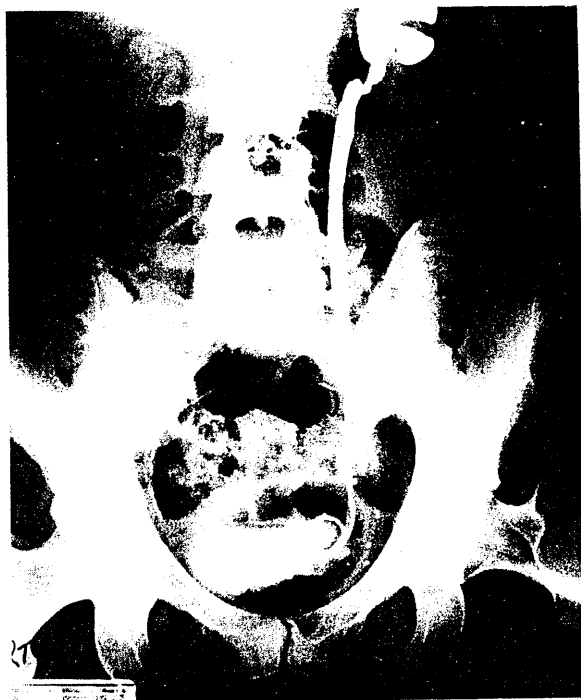

FIG. 5. Normal IVP 15 months postoperatively

tied intracorporeally (fig. 4).¹¹ Estimated blood loss was less than 100 cc and the duration of the procedure was 117 minutes. Pathology report confirmed severe endometriosis and fibrosis of the resected ureter. The total length of the removed or vaporized segment was 3 to 4 cm.

No postoperative complications were noted and the patient was discharged from the hospital 1 day postoperatively. At cystoscopy 4 weeks after the procedure the ureteral catheter was exchanged for a No. 7 internal ureteral stent. A nephrostogram revealed the ureteral anastomosis to be patent with no leakage. The stent was removed 2 months postoperatively, an IVP was normal and the patient was asymptomatic (fig. 5).

The patient was well and was asymptomatic 21 months postoperatively. Due to a negative past experience with an IVP, she refuses to undergo any further IVPs or a furosemide washout. However, ultrasound was completely normal and clearly indicated absence of hydronephrosis.

DISCUSSION

The difference between this laparoscopic procedure and a laparotomy is that bipolar electrocoagulation and laser replaced conventional dissection techniques and sharp instruments.^{2,3,5-7} Pressure from the pneumoperitoneum usually prevents small vessel bleeding and oozing. The carbon dioxide laser seals small blood vessels while cutting. The magnification obtained by the laparoscope and the video screen helps to identify pelvic anatomy better.²⁻⁷ In addition, the possibility of de novo adhesion formation is substantially lower than with laparotomy.^{12,13}

The incidence of ureteral obstruction by endometriosis is low, although estimated ureteral injury during pelvic surgery is 0.5 to 1.0% and most often occurs during gynecological procedures.¹⁴ Gomel and James reported successful laparoscopic management of ureteral injury intraoperatively.¹¹ During the laparoscopic excision of pelvic endometriosis, the ureter was lacerated but no portion of the ureter was removed. A catheter introduced via the cystoscope was found to pass through the injury. After this catheter was advanced into the left renal pelvis, it was tied to a urethral catheter and both were placed on continuous drainage. The lacerated edges were then sutured with a single 4-zero plain catgut suture and intracorporeal knotting. Subsequent examinations confirmed ureteral integrity.

Our procedure was performed safely in this initial patient, with no apparent compromise in the result. Our impression is that many new types of pelvic surgery can be done successfully with operative laparoscopy. However, it cannot be overemphasized that a thorough knowledge of pelvic anatomy must be combined with expertise in operative laparoscopy to perform such procedures. An entire surgical team is necessary to make such a case possible.

ADDENDUM

Since reporting this case, we have performed another ureteroureterostomy to repair a ureter that was resected during operative laparoscopy.¹⁵ No complications were associated with this procedure and the patient is well 8 months postoperatively.

REFERENCES

1. Nezhat, C. and Nezhat, F.: Operative laparoscopy for the management of ovarian remnant syndrome. *Fertil. Steril.*, **57**: 1003, 1992.
2. Nezhat, C. R., Nezhat, F. R. and Silfen, S. L.: Videolaseroscopy—the CO2 laser for advanced operative laparoscopy. *Obst. Gynec. Clin. N. Amer.*, **18**: 585, 1991.
3. Nezhat, C., Burrell, M. O., Nezhat, F. R., Benigno, B. B. and Welander, C. E.: Laparoscopic radical hysterectomy with para-aortic and pelvic node dissection. *Amer. J. Obst. Gynec.*, **166**: 864, 1992.
4. Nezhat, F., Nezhat, C. and Pennington, E.: Laparoscopic proctectomy for infiltrating endometriosis of the rectum. *Fertil. Steril.*, **57**: 1129, 1992.
5. Nezhat, C. and Nezhat, F.: Incidental appendectomy during videolaseroscopy. *Amer. J. Obst. Gynec.*, **165**: 559, 1991.
6. Nezhat, F., Nezhat, C. and Silfen, S. L.: Videolaseroscopy for oophorectomy. *Amer. J. Obst. Gynec.*, **165**: 1323, 1991.
7. Nezhat, C., Nezhat, F., Silfen, S. L., Schaffer, N. and Evans, D.: Laparoscopic myomectomy. *Int. J. Fertil.*, **36**: 275, 1991.
8. Stanley, K. E., Jr., Utz, D. C. and Dockerty, M. B.: Clinically significant endometriosis of the urinary tract. *Surg., Gynec. & Obst.*, **120**: 491, 1965.
9. Rivlin, M. E., Miller, J. D., Krueger, R. P., Patel, R. B. and Bower, J. D.: Leuprolide acetate in the management of ureteral obstruction caused by endometriosis. *Obst. Gynec.*, **75**: 532, 1990.

10. Nezhat, C. and Nezhat, F. R.: Safe laser endoscopic excision or vaporization of peritoneal endometriosis. *Fertil. Steril.*, **52**: 149, 1989.
11. Gomel, V. and James, C.: Intraoperative management of ureteral injury during operative laparoscopy. *Fertil. Steril.*, **55**: 416, 1991.
12. Nezhat, C. R., Nezhat, F. R., Metzger, D. A. and Luciano, A. A.: Adhesion reformation after reproductive surgery by videolaparoscopy. *Fertil. Steril.*, **53**: 1008, 1990.
13. Diamond, M. P. and Operative Laparoscopy Study Group: Post-operative adhesion development after operative laparoscopy: evaluation at early second-look procedures. *Fertil. Steril.*, **55**: 700, 1991.
14. Dowling, R. A., Corriere, J. N., Jr. and Sandler, C. M.: Iatrogenic ureteral injury. *J. Urol.*, **135**: 912, 1986.
15. Nezhat, C. and Nezhat, F.: Laparoscopic repair of ureter resected during operative laparoscopy. *Obst. Gynec.*, in press.