

Laparoscopic management of ovarian remnant

Ceana Nezhat, M.D.,^a Susan Kearney, M.H.S.E.,^a Shazia Malik, M.D.,^a Camran Nezhat, M.D.,^b and Farr Nezhat, M.D.^c

^aCenter for Special Pelvic Surgery, Atlanta, Georgia; ^bCenter for Special Minimally Invasive Surgery, Department of Obstetrics and Gynecology, and Department of Surgery, Stanford University Medical Center, Palo Alto, California; and ^cMount Sinai School of Medicine, Department of Gynecologic Oncology, New York, New York

Objective: To report outcomes of laparoscopic management of patients with ovarian remnant (OR).

Design: Retrospective chart review.

Setting: Referral practice and tertiary medical center.

Patient(s): Sixty-four patients with confirmed OR who underwent laparoscopic treatment between July 1989 and September 2003.

Intervention(s): Laparoscopic excision of OR.

Main Outcome Measure(s): Technical feasibility and recurrence.

Result(s): Sixty-nine laparoscopies were performed to remove ovarian remnants, with five patients requiring two laparoscopies. Two cases were converted to laparotomy and one to mini-laparotomy for bowel resection. In 64% (41 out of 64), pelvic mass was diagnosed by imaging (35 by ultrasound, 5 by computerized tomography [CT], and 1 by both). The majority of ovarian remnants were found attached to one or more of the following: ureter, bowel, pelvic sidewall, bladder, rectum, and uterosacral ligament. Intraoperative complications occurred in four cases: three enterotomy and repair; one cystotomy and repair. Twelve minor postoperative complications occurred including urinary tract infection, hematuria, umbilical incision infection, and transient tachycardia. Three major postoperative complications occurred: one umbilical omental hernia, one wound-abscess requiring operation, and one vesicovaginal fistula. Adhesions were present in all cases, endometriosis in 55% (35 out of 64), and fibrosis in 30% (19 out of 64).

Conclusion(s): In experienced hands, laparoscopic treatment of OR results in acceptable outcomes with its associated advantages over laparotomy. (Fertil Steril® 2005;83:973–8. ©2005 by American Society for Reproductive Medicine.)

Key Words: Ovarian remnant syndrome, laparoscopy, pain, endometriosis, cyst, complications

Ovarian remnant syndrome (ORS) is a well-known but rare complication of salpingo-oophorectomy. It occurs when ovarian tissue is inadvertently left in the pelvic cavity after intended complete extirpation of the ovary. The syndrome was first described in 1970 by Shemwell and Weed (1), although the first case was presented in the literature in 1962 by Kaufmann (2). We believe this is the largest series of patients with ORS managed surgically.

MATERIAL AND METHODS

Between July 1989 and September 2003, 64 women underwent laparoscopic treatment of histologically confirmed OR in Atlanta, Georgia and Palo Alto, California. We previously reported our earlier experience in 13 patients (3).

Inclusion criteria were history of previous oophorectomy, pelvic pain or cystic mass, and histologic evidence of remnant ovarian tissue. Institutional Review Board approval was not required because the study entailed the collection of existing data and patient confidentiality was maintained at all times.

Indications for surgery were pelvic pain and/or pelvic mass. Some patients were referred for known ORS. The mean number of previous surgeries was 4 (range, 1–11), with a mean of 2 laparoscopies (range, 0–7) and 2 laparotomies (range, 0–6) per patient. Forty-two patients had oophorectomies via laparotomy and 22 via laparoscopy, resulting in ORS. The mean time interval between oophorectomy and laparoscopy for ORS was 50 months (range, 3–372 months).

All patients underwent a preoperative outpatient bowel preparation. Multipuncture operative laparoscopy under general, endotracheal anesthesia was performed as previously described (4).

Received July 15, 2004; revised and accepted November 22, 2004.
Reprint requests: Ceana Nezhat, M.D., Center for Special Pelvic Surgery,
5555 Peachtree Dunwoody Road, Suite 276, Atlanta, Georgia 30342
(FAX: 404-255-5627; E-mail: info@Nezhat.com).

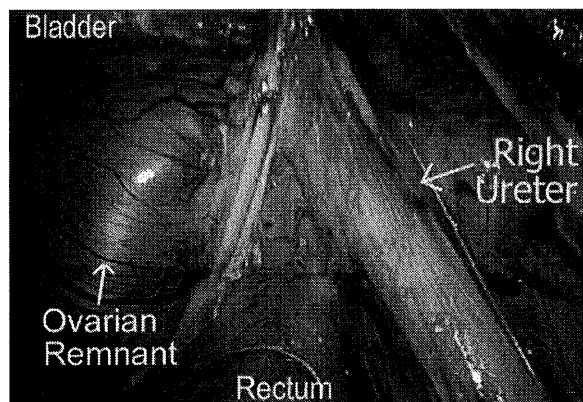
Intraabdominal adhesions were lysed and normal anatomy restored. The remnant tissue was identified and dissected. In all cases where the remnant was attached to the pelvic sidewall, operative excision in an extraperitoneal fashion was used, as has been described by Pettit and Lee (5). The anatomy of the retroperitoneal space was identified, and the space beneath the peritoneum was injected with lactated Ringer's solution. By using adjustable pressure pumps for hydrodissection, we were able to use different pressures to assist in injecting physiological solution, such as lactated Ringer's, retroperitoneally to create a plane of dissection, even in cases with retroperitoneal fibrosis that benefit from a combination of hydrodissection and sharp dissection with CO₂ laser.

The peritoneum was opened to the infundibulopelvic ligament or its remnant. Adhesiolysis was performed until the course of the major pelvic blood vessels and the ureter could be traced and dissected (Fig. 1). At times, the ovarian remnant was adhered to the vaginal cuff and bladder area. In this case, although identification of the anatomy and plane of dissection was essential, deep dissection and extensive ureterolysis were not necessary. Bipolar forceps were used to desiccate the ovarian blood supply and the OR, and the contiguous peritoneum and surrounding tissue was excised and submitted for histologic examination.

When the remnant was attached to the bowel (Fig. 2), enterolysis was performed. If the tissue was adhered superficially to the muscularis of the bowel, it was excised off the bowel using a shaving technique. The serosa and muscularis were reinforced with 1–3 interrupted 4-0 polydioxanone or 0 polyglactin 910 sutures in 1 layer. When the remnant was deeply embedded in the bowel or bladder muscularis or when the ureter was involved or obstructed (Fig. 3A and B), partial removal of the involved organ and repair were performed (4).

FIGURE 1

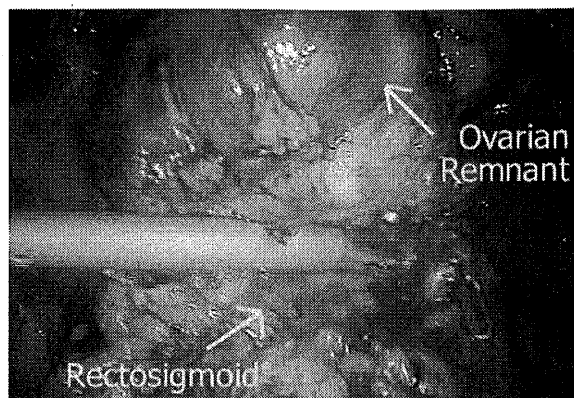
Ovarian remnant adherent to the dissected right ureter.



Nezhat. *Laparoscopy for ORS. Fertil Steril* 2005.

FIGURE 2

Ovarian remnant adherent to the rectosigmoid.



Nezhat. *Laparoscopy for ORS. Fertil Steril* 2005.

The most common associated procedures were enterolysis (58 procedures), ureterolysis (47 procedures), and treatment of endometriosis and fibrosis (54 procedures). Follow-up results were determined by return examination, telephone interview, or contact with the referring physician.

RESULTS

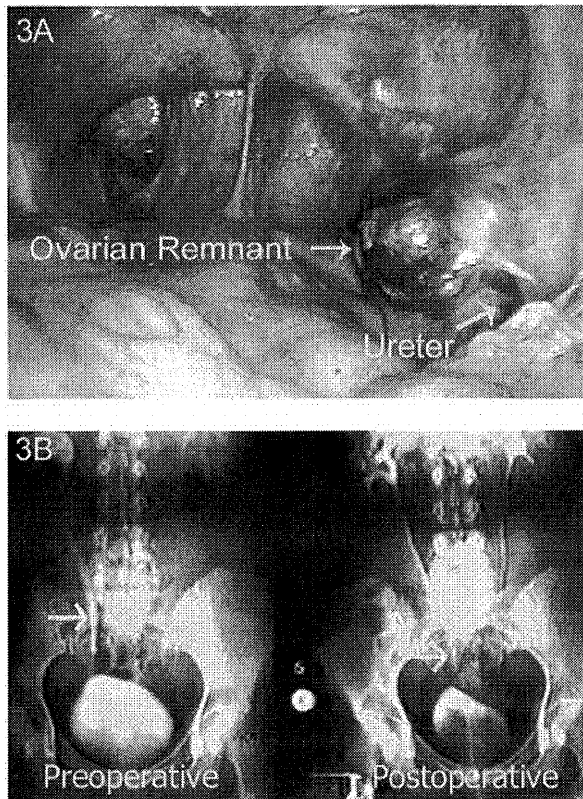
The mean age was 38.7 years (range, 22–57 years). A total of 69 laparoscopies for the excision of ORs were performed, with 5 patients undergoing 2 laparoscopies. The ORs were most commonly adhered to the small and large bowel, ureter, pelvic sidewall, bladder, and uterosacral ligament.

Two cases were converted to laparotomy and one to a mini-laparotomy for bowel resection. The first two laparotomies for bowel resection were in early cases (3). Since that time, we have modified the procedure to perform either shaving of the OR from the muscular layer or laparoscopically assisted bowel resection, which consists of mobilization of the bowel laparoscopically and reanastomosis via mini-laparotomy (4). A total of five patients had bowel resections, one had a ureteroneocystostomy for complete resection of the remnant ovarian tissue, and one had a partial urinary bladder wall resection in addition to a partial vaginectomy.

Intraoperative complications included enterotomy (three) and cystotomy (one). Postoperatively, there were 12 minor complications, including urinary tract infection, hematuria, umbilical incision infection, and transient tachycardia, and 3 major complications, including 1 umbilical omental hernia, 1 wound abscess, and 1 vesicovaginal fistula. The umbilical omental hernia occurred on postoperative day 3 in a thin patient (5'2", 102 lbs) who had a history of postoperative respiratory dysfunction and had been admitted for observation. Her coughing caused the umbilical sutures to break. The omental hernia was reduced, and the incision was closed

FIGURE 3

(A) Ovarian remnant overlying the right ureter. (B) IVP showing preoperative right hydroureter with postoperative resolution.



Nezhat. Laparoscopy for ORS. *Fertil Steril* 2005.

with nylon sutures under local anesthesia; her recovery was uneventful. Another patient had an umbilical wound abscess 4 weeks postoperative, which required incision and drainage.

The patient with the vesicovaginal fistula had ovarian tissue adherent to the ureter, vagina, bladder, and rectum. At laparoscopy, a colpotomy was performed, and a portion of the posterior bladder wall and anterior rectosigmoid had to be dissected. Extensive ureterolysis was performed to assure complete resection of the ovarian remnant. Postoperatively, the patient complained of a watery discharge and her work-up confirmed a vesicovaginal fistula. The fistula was repaired laparoscopically 2 months after the OR surgery without recurrence, and the patient remains symptom-free (6).

Ten patients had previous surgical attempts to remove the remnant ovarian tissue. Two of these patients had undergone two previous surgeries, each having one by laparotomy and one by laparoscopy. Of the other 8 patients, 4 had prior attempts by laparotomy and 4 by laparoscopy, all at other centers. Two of these 10 patients required two laparoscopies at our center for complete

treatment. Both patients had bilateral pelvic sidewall dissection and evaluation for potential remnant ovarian tissue at their initial surgery. However, postoperatively (1 patient at 10 weeks and 1 patient at 12 months), they had pain and work-up suggestive of recurrence.

A total of five patients underwent two surgeries at our center for OR. After their first surgery, each patient experienced recurrent pain, and ultrasound confirmed the possibility of remnant ovarian tissue. Their average length of follow-up was 5.4 years (Table 1).

Three patients may continue to have OR. The first patient had undergone two prior surgeries for OR; she had her third surgery at our center. Postoperatively, her laboratory values were indicative of continued OR, but the patient chose not to have any further surgical intervention because she was nearly pain-free. Two patients were diagnosed with continued OR based on laboratory values and continued, but manageable, pelvic pain. Both patients chose to pursue medical management without surgical intervention (Table 2).

DISCUSSION

Although the true incidence of ORS is unknown, reporting ORS has increased over the past several years. This is most likely due to increased awareness of the condition and more readily available imaging studies (5). As our study demonstrated, symptoms of OR generally occur within 5 years of oophorectomy (7, 8). The most frequent symptom is pelvic pain. However, the complaints may vary, with the pain presenting as cyclic or chronic; the pain may be described as pressure or dull aching to severe, sharp, and stabbing (7). Patients may also experience low back pain, variable bowel symptoms, dyspareunia, pelvic mass, or ureteral compression (8).

A predisposing factor for ORS is increased vascularity, which causes difficult hemostasis, endometriosis, pelvic inflammatory disease (PID), pelvic adhesions, and altered anatomy, similar to the problems observed with neoplasm and endometriosis (7, 9). The most common preexisting conditions include endometriosis, PID, and prior abdominal surgery (10, 11). All our patients had pelvic adhesions and about half were treated for endometriosis. Ovarian remnant syndrome is more likely to occur when the ovary is densely adherent to adjacent structures. Because of preexisting conditions and prior surgeries, the ORs are usually encased in adhesions. The remnant can undergo functional changes resulting in increased ovarian volume within a fixed space, causing pain and compression of adjacent structures (12).

Histologic examination of OR tissue has shown a variety of findings, including follicular cysts, endometriosis, corpus luteum, and ovarian cancer. Five cases of ovarian cancer developing in an ovarian remnant after total abdominal hysterectomy and bilateral salpingo-oophorectomy have been documented (13).

TABLE 1**Patients who underwent two operative laparoscopies for ORS during study period.**

Case	Length of time between surgeries	Location of ORS	Surgical notes	Final outcomes and length of follow-up
1	12 mo	1st surgery: bowel 2nd surgery: bowel	2nd surgery converted to laparotomy for bowel resection	No recurrence; 130 mo
2	5 mo	1st surgery: right perivesical area, obturator fossa 2nd surgery: between bowel and bladder	—	No recurrence; 21 mo
3	8 mo	1st surgery: left ureter 2nd surgery: bowel	Patient had prior surgery for ORS	No recurrence; 57 mo
4	10 wk	1st surgery: bowel 2nd surgery: bowel	2nd surgery converted to laparotomy for bowel resection. Patient had prior surgery for ORS.	No recurrence; 114 mo
5	32 mo	1st surgery: back of vagina 2nd surgery: over vaginal cuff, beneath bladder	—	Patient lost to follow-up

Note: ORS = ovarian remnant syndrome.

Nezhat. *Laparoscopy for ORS. Fertil Steril* 2005.

Diagnosing OR can be difficult, but it should be considered in the differential diagnosis in patients who have pelvic pain after oophorectomy. Although this can entail a very broad spectrum of pathologies, ORS must be considered as a possible cause in these cases. Imaging studies, including pelvic ultrasound, computed tomography (CT), and magnetic resonance imaging (MRI), are useful but do not always indicate OR. This is illustrated in the present series where 51 imaging studies, either ultrasound or CT, were performed before surgery, but only 41 indicated ORS.

Preoperative follicle-stimulating hormone (FSH) levels are helpful in confirming the diagnosis, especially when the levels are in the premenopausal range (<40) in patients who have undergone bilateral oophorectomy. However, because the functioning ovarian tissue that remains can produce estradiol levels that are incapable of suppressing gonadotropin, an FSH >40 does not exclude the diagnosis (5, 14).

In cases of unilateral oophorectomy or hormone therapy, FSH levels are of no value. Some physicians do not consider ORS in patients who have undergone unilateral oophorectomy. Such an omission can lead to misdiagnosis, causing continued pain and undo stress for the patient. In the current series, 19 women had a history of unilateral oophorectomy that resulted in unintentional, incomplete removal of the ovary. Although current medical terminology excludes these patients by limiting the definition of ORS to those women who have undergone bilateral salpingo-oophorectomy, we

must stress the importance of considering this diagnosis even in women with a remaining ovary.

Treatments that have been utilized for patients with ORS include medical management, radiation therapy, cyst aspiration, and surgical resection. Medical management can be used for patients in whom surgery is not an option or if surgery fails to completely eradicate the ovarian tissue. Oral contraceptives, gonadotropin-releasing hormone analogue (GnRH-a), medroxy-progesterone acetate, and estrogens have all been used, but none appears to be better than the other (15). Although these therapies are not known to be curative, Koch et al. (12) reported a case of ureteral obstruction that was successfully treated with GnRH-a.

Medical management can also be used in patients before surgery to assist with pain relief. However, this can reduce the size of the remnant, making it more difficult to remove at surgery. Conversely, ovarian stimulation has been used before surgery to facilitate the location of the remnant tissue. Kaminski et al. (16) reported a case in which clomiphene citrate was administered for 10 days (100 mg/d) before laparotomy. A preoperative ultrasound identified a 6-cm mass that was previously unseen.

Radiation therapy is another form of management that has been proposed, but this therapy has significant side effects and potential consequences, including increased pelvic adhesion formation, enteritis, and colitis (1). Fleischer et al.

TABLE 2

Patients with suspected continuation of ORS.

Case	Prior surgical treatment	Location of ORS	Final outcomes
1	Laparotomy Laparoscopy	Pelvic sidewall and bowel	Continued ORS as indicated by serum FSH level; patient chose no further intervention due to lack of symptoms.
2	None	Left ureter and bowel	Continued ORS as indicated by serum FSH level and continued pelvic pain; patient chose to pursue medical management.
3	None	Bilateral remnants: both attached to bowel, bladder, and ureters	Continued ORS as indicated by serum FSH level and continued pelvic pain; patient chose to pursue medical management.

Note: ORS = ovarian remnant syndrome; FSH = follicle-stimulating hormone.

Nezhat. *Laparoscopy for ORS. Fertil Steril* 2005.

(17) recently advocated the use of ultrasonic guided cyst aspiration in cases where medical management has failed. They reported that the cyst aspiration provided symptomatic relief and offers an alternative to repeat surgery in some cases.

Despite the variety of treatment options, surgical excision of the OR appears to be the best choice in the majority of cases. Several early studies stated that laparoscopy is not useful in treating OR because of extensive adhesions (5, 7, 10). Since the publication of those studies, great advancement has occurred in the field of operative laparoscopy, including improved instrumentation and training.

In addition to the known general advantages of laparoscopy over laparotomy, the use of laparoscopy to treat OR has further benefits:

1. The magnification provided by the laparoscope allows for easier identification of the anatomy and the remnant tissue.
2. Increased intraabdominal pressure helps to reduce blood loss, and the distention causes the retroperitoneal space to unfold allowing for better visualization (18).
3. Laparoscopy is less traumatic, which is an important benefit for patients who have likely undergone multiple prior surgeries (3).

The current series demonstrates that with technical advancements and increased experience, the number of recurrences decreased, along with the number of conversions to laparotomy and postoperative complications.

We compared the first 32 cases with the second 32 cases and found that 4 of the 5 patients who underwent 2 surgeries at our center were in the first half, along with both conver-

sions to laparotomy. This comparison also demonstrates that the incidence of ORS after laparoscopic oophorectomy has increased. In the first 32 cases, 22% (7 out of 32) resulted from laparoscopic oophorectomy and 78% (25 out of 32) occurred after oophorectomy by laparotomy. In the second half, 47% (15 out of 32) occurred after laparoscopic oophorectomy and 53% (17 out of 32) occurred after laparotomy. This increase may be due to rising numbers of laparoscopic oophorectomies being performed. This is a cause for concern, however, because it may illustrate that laparoscopic oophorectomy results in a higher incidence of ORS.

To date, no clear evidence exists in which an oophorectomy performed by laparotomy or by laparoscopy is associated with less risk of OR. In the current series, approximately two-thirds of the patients had undergone oophorectomy by laparotomy, which resulted in OR. Although these are substantial numbers, we cannot state with any certainty that they are indicative of one method being superior to the other. Factors that may have contributed to these numbers include surgical skill, associated procedures or pathologies, or facility constraints.

The reported incidence of injury to the bladder, ureter, and bowel at laparotomy for ORS is 3%–33%, with injuries to the ureter significantly greater with laparotomy than with laparoscopy (18). The rate of intraoperative complications in the current study is 5.8%, with 4 intraoperative complications in 69 laparoscopies and no injury to the ureter. This does not include either intentional ureteroneocystostomy as occurred with one patient, nor bowel resection, which was performed on five patients (two by laparoscopy, one by minilaparotomy, and two by laparotomy). Due to the presence of dense pelvic adhesions and severity of the remnant, as with laparotomy, the surgeon must begin the procedure

with an awareness that resection of the bowel, bladder, or ureter may be necessary for complete removal of the OR. Our series and others have demonstrated that the rate of complications with laparoscopic treatment of OR is comparable or superior when compared with the reports of laparotomy (18, 19).

Regardless of the surgical approach, key steps must be taken during removal of an ovarian remnant:

1. The anatomy should be restored as completely as possible with bilateral sidewall and cul-de-sac dissection in patients with bilateral oophorectomy, and any other pelvic pathology, such as endometriosis, should be treated.
2. The ureter should be identified and dissected all the way down from the pelvic brim if necessary. Ureteral stents may be useful in identification of the ureter, although some investigators believe that these stents contribute to injury of the ureter because their rigidity (5). In the current series, ureteral stents were used in 11 cases, with the majority of these in early cases, and there were no ureteral injuries.
3. Complete excision of the ovarian remnant with a good margin of healthy tissue must be executed. Resection of the adherent structures may be necessary to remove the tissue, but this is preferable to subsequent surgery for incomplete removal.
4. A complete and thorough examination of the abdominopelvic cavity should be performed before terminating the procedure to check for any other possible sites of OR.

Despite these guidelines, recurrence of OR is possible, whether from incomplete removal or recurrence from another remnant. In the current series, five patients (8%) required two surgeries during their treatment (Table 1). Three (5%) other patients had suspected recurrence of OR (Table 2). This data is consistent with previous findings that estimate the recurrence of ORS to be between 8% and 25% (11, 19). It also demonstrates the potential difficulty of treating ORS.

Surgical treatment of OR is a difficult task, whether performed by laparoscopy or by laparotomy. Our experience and previous studies (18, 19) indicate that laparoscopic man-

agement of ORS produces acceptable outcomes with the known advantages of laparoscopy.

REFERENCES

1. Shemwell RE, Weed JC. Ovarian remnant syndrome. *Obstet Gynecol* 1970;36:299-303.
2. Kaufmann JJ. Unusual causes of extrinsic ureteral obstruction. Part 1. *J Urol* 1962;97:319-27.
3. Nezhat F, Nezhat C. Operative laparoscopy for the treatment of ovarian remnant syndrome. *Fertil Steril* 1992;57:1003-7.
4. Nezhat C, Siegler A, Nezhat F, Nezhat CH, Seidman D, Luciano A. *Operative gynecologic laparoscopy: principles and techniques*. 2nd ed. New York: McGraw Hill, 2000:165.
5. Pettit PD, Lee RA. Ovarian remnant syndrome: diagnostic dilemma and surgical challenge. *Obstet Gynecol* 1988;71:580-3.
6. Nezhat CH, Nezhat F, Nezhat C, Rottenberg H. Laparoscopic repair of a vesicovaginal fistula. A case report. *Obstet Gynecol* 1994;83:899-901.
7. Symmonds RE, Pettit P. Ovarian remnant syndrome. *Obstet Gynecol* 1979;54:174-7.
8. Johns DA, Diamond MP. Adequacy of laparoscopic oophorectomy. *J Am Assoc Gynecol Laparosc* 1993;1:20-3.
9. Lafferty HW, Angioli R, Rudolph J, Penalver MA. Ovarian remnant syndrome: experience at Jackson Memorial Hospital, University of Miami, 1985 through 1993. *Am J Obstet Gynecol* 1996;174:641-5.
10. Webb MJ. Ovarian remnant syndrome. *Aust N Z J Obstet Gynaecol* 1989;29:433-5.
11. Steege JF. Ovarian remnant syndrome. *Obstet Gynecol* 1987;70:64-7.
12. Koch MO, Coussens D, Burnett L. The ovarian remnant syndrome and ureteral obstruction: medical management. *J Urol* 1994;152:158-60.
13. Narayansingh G, Cumming G, Parkin D, Miller I. Ovarian cancer developing in the ovarian remnant syndrome. A case report and literature review. *Aust NZ J Obstet Gynaecol* 2000;40:221-3.
14. Scott RT, Beatse SN, Illions EH, Snyder RR. Use of GnRH agonist stimulation test in the diagnosis of ovarian remnant syndrome: a report of three cases. *J Reprod Med* 1995;40:143-6.
15. Orford V, Kuhn R. Management of ovarian remnant syndrome. *Aust NZ J Obstet Gynaecol* 1996;36:468-71.
16. Kaminski PF, Sorosky JI, Mandell MJ, Broadstreet RP, Zaino RJ. Clomiphene citrate stimulation as an adjunct in locating ovarian tissue in ovarian remnant syndrome. *Obstet Gynecol* 1990;76:924-6.
17. Fleischer AC, Tait D, Mayo J, Burnett L, Simpson J. Sonographic features of ovarian remnants. *J Ultrasound Med* 1998;17:551-5.
18. Kamprath S, Possover M, Schneider A. Description of a laparoscopic technique for treating patients with ovarian remnant syndrome. *Fertil Steril* 1997;68:663-7.
19. Abu-Rafah B, Vilos GA, Misra M. Frequency and laparoscopic management of ovarian remnant syndrome. *J Am Assoc Gynecol Laparosc* 2003;10:33-7.