

1992

Laparoscopic Ureteroureterostomy

CAMRAN NEZHAT, M.D.,* FARR NEZHAT, M.D.,* BRUCE GREEN, M.D.,†,‡ and
GILBERT GONZALEZ, M.D.†

ABSTRACT

With the advances in operative laparoscopy, it is now possible to perform ureteroureterostomy laparoscopically. We have developed a technique that has proven successful for treating ureteral obstruction and injury. Other clinical situations, including excision of an isolated ureteral stricture, laparoscopic ureterolithotomy, and excision of a low-grade ureteral tumor may be managed by this technique.

INTRODUCTION

SINCE THE INTRODUCTION of videoendoscopy development, laparoscopic surgery has undergone rapid advancement over the past 8 years. The introduction of improved instruments and superior video systems,¹ and the concurrent increased skill of the laparoscopic surgeon has led to an explosion in the number of procedures performed. The degree of complexity has also advanced, from the laparoscope's early diagnostic functions to its present use for appendectomy,² cholecystectomy, lymph node dissections,³ and nephrectomy.

In this article, we describe our technique in detail. Using this method as a foundation, we have performed the first laparoscopic ureteroureterostomy to treat complete ureteral obstruction and the first repair of a completely transected ureter successfully.^{4,5} Possible additional uses of the technique are discussed.

OPERATIVE TECHNIQUE

Ureteroureterostomy is indicated in cases involving a partial or complete ureteral obstruction that is unresponsive to medical therapy. Traditionally, this procedure has been performed by laparotomy. However, we have recently developed a technique using the CO₂ laser (Coherent, Palo Alto, CA) through the

operative channel of the laparoscope, affording patients requiring ureteroureterostomy the numerous benefits of laparoscopy.^{1,6}

As with any procedure, proper patient selection cannot be overemphasized. It is imperative that the risks as well as the benefits be thoroughly explained to the patient and that proper consent be obtained prior to surgery. In addition, the skills necessary to perform more complex laparoscopic procedures must be developed gradually.

Ureteroureterostomy

Patients are given 1 g of cefoxitin (Mefoxin, Merck, Sharp and Dohme, West Point, PA) one-half hour before surgery. The procedure is performed under general endotracheal anesthesia with the patient in a modified supine position (Fig. 1). The video laparoscope and three suprapubic portals are placed as previously described.¹

For cases of ureteral obstruction, use a combination of hydrodissection⁷ and the CO₂ laser to treat any associated lesions, such as endometriosis, fibrosis, or adhesions. Then, dissect the ureter from surrounding tissues. Transect the proximal ureter and inject indigo carmine into the patient's IV to confirm its patency. Next, introduce a 7F ureteral catheter cystoscopically into the distal ureter. Transect the distal ureter over the stent and remove the obstructed portion of ureter. When this is complete,

*Center for Special Pelvic Surgery, Atlanta, GA, and Department of Obstetrics and Gynecology, Mercer University School of Medicine, Macon, GA

†Department of Urology, Emory University, Atlanta, GA

‡Director of Urology, Sheperd Spinal Center, Atlanta, GA

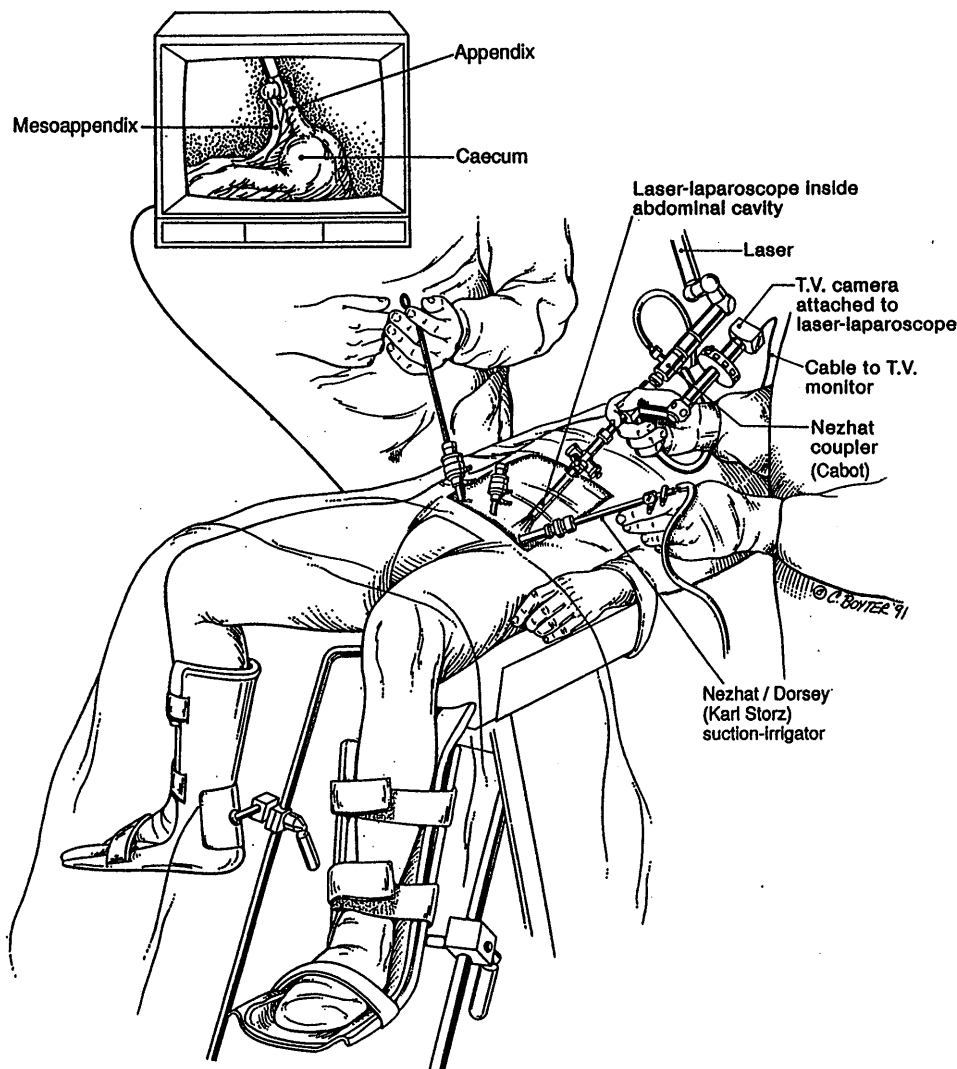


FIG. 1. Room setup showing patient position and instrument placement.

introduce the ureteral stent into the proximal ureter and advance it into the renal pelvis. To perform anastomosis, use four 4-0 polydioxanone sutures (Ethicon, Somerville, NJ) in an interrupted fashion, placing them at 6, 12, 9, and 3 o'clock to approximate the proximal and distal ureteral edges.

An external ureteral stent should be left in the ureter for a minimum of 4 weeks, at which time it is exchanged cystoscopically for an internal stent. This stent remains in place for approximately 2 months post operatively. The patient's follow-up should include intravenous urogram, ultrasound, or excretion scans.

Ureter repair

To help prevent ureteral injury, we recommend identifying the course of both ureters from their entrance to the pelvic cavity until they disappear in the ureteric tunnel before working near the ureters or bladder. At the conclusion of a procedure, the pelvic cavity should be inspected as thoroughly as possible.

Injection of indigo carmine may aid in detecting a laceration of the ureter. When injury is noted, the surgeon should attempt repair via the technique(s) with which he or she is most familiar. Before undertaking laparoscopic repair, consent should be obtained.

To repair a resected ureter, identify both ends at the pelvic brim and hold them with the grasping forceps. The proximal end may be detected by injecting indigo carmine and observing the blue efflux. To identify the distal edge, introduce a stay ureteral stent cystoscopically. Gradually free the edges from the surrounding tissue until there is adequate length and feed the ureteral stent into the proximal ureter; then pass a Benson wire into the renal pelvis. After this step is complete, place one 4-0 polydioxanone suture (Ethicon) to hold the proximal and distal ends together.

To complete the repair, four 4-0 polydioxanone sutures (Ethicon) should be placed at 12, 6, 9, and 3 o'clock. We use two laparoscopic needle holders (Karl Storz, Culver City, CA) and extracorporeal knotting. After insuring that the lacerated

edges are well approximated, insert a Jackson-Pratt Drain by first passing the tubing into the peritoneum and pulling the tubing out through a contralateral portal; then use the grasping forceps to place the drain precisely. Remove the straight ureteral stent, place a double J ureteral stent over the Benson wire, and introduce an indwelling Foley catheter to the bladder.

Postoperatively, 1 g of cefoxitin (Mefoxin, Merck, Sharp and Dohme) may be given every 6 hours, until the patient is discharged from the hospital. Analyze any drainage from the Jackson-Pratt drain, and if blood, urea, nitrogen, and creatinine levels are compatible with peritoneal fluid (indicating integrity of the repair), the drain may be removed. The Foley catheter may be removed on the first or second postoperative day, but leave the ureteral stent in place.

Upon discharge, we prescribe prophylactic antibiotics (Septra DS, Burroughs Wellcome, Research Triangle Park, NC), 1 tablet, two times each day for 7 days. Approximately 6 weeks postoperatively, perform an intravenous urogram and if no extravasation is noted and the kidney and ureter appear normal, the ureteral stent may be removed with a flexible cystoscope.

DISCUSSION

In the past, the treatment of both ureteral obstruction secondary to endometriosis and iatrogenic ureteral injuries has required open surgical procedures. It is feasible to perform uretero-ureterostomy via the laparoscopic approach.

Certain principles must be adhered to have a successful outcome. Foremost, the surgeon must have acquired expertise in laparoscopic surgery and must have a thorough knowledge of pelvic wall anatomy. Second, ureteral length must be obtained to ensure a tension-free anastomosis. Mastering extracorporeal

and intracorporeal knotting for anastomosis is another prerequisite. Placement of a Jackson-Pratt drain is advisable.

We can envision other clinical situations that may be managed by this technique, such as the excision of an isolated ureteral stricture, laparoscopic ureterolithotomy, and possibly the excision of a low-grade ureteral tumor in a frail and elderly patient. As the laparoscopic technique is improved and refined, its applications will continue to increase in urology decreasing the need for laparotomy.

REFERENCES

1. Nezhat C, Nezhat F, Silfen S: Videolaseroscopy: the CO₂ laser for advanced laparoscopy. *Obstet Gynecol Clin North Am* 1991; 18: 585-604
2. Nezhat C, Nezhat F: Incidental appendectomy during videolaseroscopy. *Am J Obstet Gynecol* 1991; 165:559-564
3. Nezhat C, Burrell MO, Nezhat FR, Benigno BB, Welander CE: Laparoscopic radical hysterectomy with para-aortic and pelvic node dissection. *Am J Obstet Gynecol* 1992, 166:864-865
4. Nezhat C, Green B, Welander C, Nezhat F: Laparoscopic treatment of obstructed ureter due to endometriosis by resection and uretero-ureterostomy. A case report. *J Urol* 1992; (in press)
5. Nezhat C, Nezhat F: Laparoscopic repair of resected ureter during operative laparoscopy to treat endometriosis. A case report. *Obstet Gynecol* 1992; (in press)
6. Nezhat C, Silfen SL, Nezhat F, Martin D: Surgery for endometriosis. *Curr Opin Obstet Gynecol* 1991; 3:385-393
7. Nezhat C, Nezhat F: Safe laser excision or vaporization of peritoneal endometriosis. *Fertil Steril* 1989; 52:149-151

Address reprint requests to:

Camran Nezhat, M.D.

*5555 Peachtree-Dunwoody Road, Suite 276
Atlanta, GA 30324*