

Aug. 1998

Laparoscopic Treatment of Type IV Rectovaginal Fistula

Ceana H. Nezhat, M.D., J. Augusto Bastidas, M.D., Earl Pennington, M.D., Farr R. Nezhat, M.D., Francisco Raga, M.D., and Camran R. Nezhat, M.D.

Abstract

Fistulas between the anorectum and vagina may arise from several causes. Treatment depends on their etiology and location, as well as the surgeon's experience. Operative laparoscopy was successful in two women with type IV (mid)rectovaginal fistula in whom previous surgical attempts failed. Our experience suggests that mid and high rectovaginal fistulas can be effectively treated by laparoscopy in the hands of experienced endoscopic surgeons.

(J Am Assoc Gynecol Laparosc 5(3):297-299, 1998)

Fistulas between the anorectal canal and vagina are relatively uncommon, accounting for less than 5% of all anorectal fistulas. Causes of rectovaginal fistulas include obstetric trauma, congenital anomalies, endometriosis, carcinoma, irradiation damage, inflammatory bowel disease, and complications of gynecologic and colorectal surgery.¹ Appropriate treatment requires consideration of the etiology, location, and condition of involved tissue.

Rectovaginal fistulas are associated with inflammatory bowel disease in 10% of patients.² These have little chance of healing in the presence of severe proctitis, and therefore intensive medical treatment of inflammatory disease is indicated before surgical methods are employed.

Rectovaginal septal defects are classified with respect to condition of the perineal body and rectovaginal

septum. The three types are classified as loss of perineal body without evidence of a fistulous tract (I); loss of perineal body with a fistulous tract in the lowest third of the vagina (II); and intact perineal body with a fistulous tract in the lowest third of the vagina (III). Types IV and V involve the middle and upper thirds of the vagina, respectively.¹ A vaginal approach is commonly used to repair rectovaginal fistulas. If this fails, a trans-abdominal approach may be required for type IV and V lesions.^{1,2}

Case Reports

Patient No. 1

A 47-year-old, gravida 1, para 1 woman had a history of severe pelvic endometriosis (American Fertility Society classification stage IV). Her surgical

From the Stanford Endoscopy Center for Training and Technology, and Departments of Gynecology and Obstetrics (Drs. C. H. Nezhat, C. R. Nezhat, Raga, and F. R. Nezhat) and Surgery (Dr. Bastidas), Stanford University School of Medicine, Stanford, California; and Center for Pelvic Surgery Endometriosis Clinic (Drs. C. H. Nezhat, C. R. Nezhat, and F. R. Nezhat), and Atlanta Colorectal Surgery (Dr. Pennington), Atlanta, Georgia.

Dr. Raga is supported by Ministerio de Sanidad y Consumo grant from the Spanish government, Madrid, Spain.

Address reprint requests to Camran R. Nezhat, M.D., 900 Welch Road, Suite 403, Palo Alto, CA 94304; fax 650 327 2794.

Accepted for publication May 4, 1998.

Reprinted from THE JOURNAL OF THE AMERICAN ASSOCIATION OF GYNECOLOGIC LAPAROSCOPISTS, August 1998, Vol. 5 No. 3
© 1998 The American Association of Gynecologic Laparoscopists.
All rights reserved. ISSN 1074-3804

history was significant for abdominal hysterectomy and unilateral salpingo-oophorectomy for uterine fibroids and endometriosis. Two years later she underwent laparotomy for a pelvic mass in the posterior cul-de-sac; pathology revealed an endometrioma. Immediately after this procedure she developed a midrectovaginal fistula type IV.³ One month later she underwent laparotomy with repair of the fistula and simultaneous diverting colostomy. Despite diverting colostomy, rectovaginal examination revealed that the fistula did not heal over 9 months.

Given recurrence of the fistula after abdominal repair, the patient was offered laparoscopic management. We discussed with her our experience with laparoscopic treatment of infiltrative endometriosis involving the rectovaginal septum.^{4,5} She was made aware that laparoscopic repair is an emerging procedure.

Bowel preparation included metronidazole 1g the night before and cefoxitin 1g, 1.5 hours before surgery.^{4,5} Laparoscopic inspection of the abdomen revealed dense adhesions of bowel and omentum to the vaginal apex and adjacent structures. Extensive adhesiolysis and bilateral ureterolysis were necessary to restore normal anatomy.⁴⁻⁶ Rectovaginal examination and a rigid sigmoidoscope were used to identify correct planes.

Once the rectovaginal space was entered (Figure 1), rectovaginal examination easily identified a large, 2- to 3-cm fistulous tract that was excised with carbon dioxide laser. Rectal and vaginal defects were then closed with several interrupted 1-0 polyglactin sutures. A piece of omentum was interposed between vaginal and rectal repairs.

Operating time was 75 minutes and total blood loss was less than 50 ml. The patient was discharged 48 hours postoperatively. Contrast enema 6 weeks later revealed successful closure of the fistula. Colostomy closure was performed 3 months later. The patient remained asymptomatic at 12-month follow-up.

Patient No. 2

A 34-year-old nulligravida had a long history of severe Crohn disease and recurrent midrectovaginal fistula type IV.³ Her surgical history was significant for emergency appendectomy, after which she developed numerous anovaginal fistulas and a midrectovaginal fistula. She underwent three surgical repairs of the midrectovaginal fistula, all by a transvaginal approach.

The woman was offered laparoscopic management to afford better visualization of the fistula and minimal handling of fragile tissue. As with the first patient,

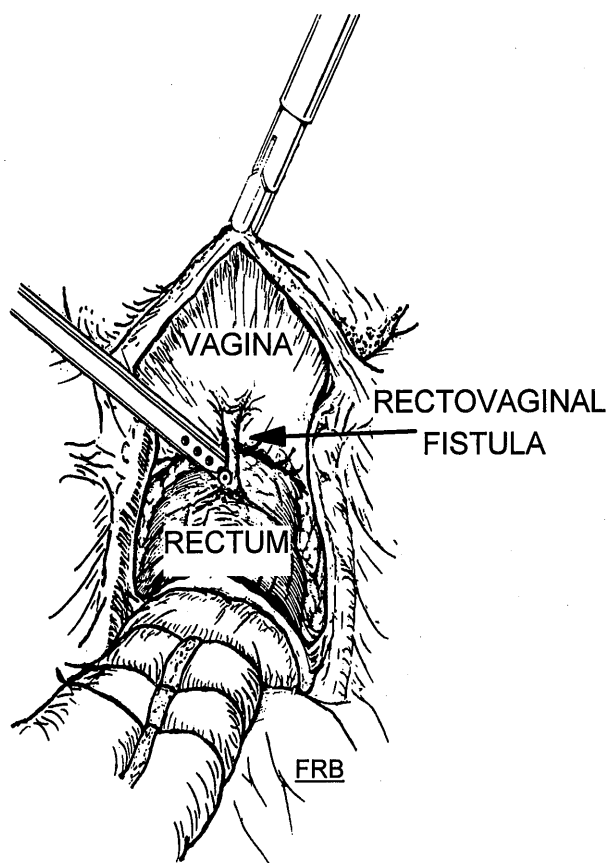


FIGURE 1. Development of the rectovaginal space. While an assistant conducts rectovaginal examination, an incision is made and hydrodissection is performed. After complete development of the rectovaginal space, the fistulous tract is identified and dissection is performed with carbon dioxide laser and hydrodissection.

she understood the emerging nature of this procedure. High dosages of prednisone and chemotherapeutic agents were required to bring inflammation under control, and surgical repair was timed during remission.

Bowel preparation was similar to that for patient 1. Abdominal and pelvic examinations revealed normal uterus, spots of endometriosis on the ovaries and posterior cul-de-sac (American Society of Reproductive Medicine stage II), and posterior cul-de-sac adhesions.

Similar dissection was performed as in patient 1. The rectovaginal space was entered after lysis of adhesions and identification of the ureters. Dissection was continued to right and left pararectal areas and down to the level of levator ani muscles. Repeat examination of peritoneum, rectum, and vagina was performed. As dilute indigo carmine dye was injected into the

perineal end of the fistula, the surgeon visualized through the flexible sigmoidoscope dye at the rectal side of the fistula. Simultaneous laparoscopic examination revealed a sinuous, 2-mm tract along the anterior rectal wall. This portion was carefully desiccated. Omentum was interposed in the rectovaginal space.

The hollow of the sacrum was then entered and rectosigmoid colon was mobilized.^{4,5} At this stage the rectosigmoid colon was transected approximately 25 cm from the anal verge with a 60-mm stapling gun (Endopath; Endosurgery Inc., Cincinnati, OH). The proximal end of the colon was transfixed to the skin of the 30-mm cannula site, thus performing a diverting colostomy.

Total operating time was 95 minutes and total blood loss was less than 100 ml. The woman's postoperative course was uneventful and she was discharged 48 hours later.

Three months later and before consideration of colostomy reversal, examination under anesthesia was performed. Careful vaginal examination failed to reveal evidence of fistula. Rigid proctosigmoidoscopy revealed normal rectal mucosa and flexible sigmoidoscopy also failed to reveal evidence of mucosal abnormality in the diverted rectum. Having identified no persistent anovaginal fistula visually, a tampon test was performed by filling the rectum with diluted methylene blue dye, with no evidence of leakage into the vagina. The colostomy was reversed by minilaparotomy 3 months postoperatively, and the patient has been asymptomatic for the past 23 months.

Discussion

Operative laparoscopy has revolutionized abdominal surgery and is a reasonable alternative to laparotomy for increasing numbers of indications.⁵⁻⁷ These advances extend to treatment of rectosigmoid colon and rectovaginal septum pathology.^{4,5}

Advantages of the laparoscopic approach to rectovaginal septum are better visualization in this deep

and small space, given Trendelenburg position, magnification, and lighting. With the patient in lithotomy position, one can use the sigmoidoscope simultaneously. This allows the surgeon to view the rectum from its mucosal and internal surfaces for identification, precise dissection, and resection of the fistula.

Recently, laparoscopic resection of type V (high) rectovaginal fistula was reported.⁸ That case and our two illustrate that the technique provides good results in managing type IV and V rectovaginal fistulas.

References

1. Fry RD, Kodner IJ: Rectovaginal fistula. *Surg Annu* 27:113-131, 1995
2. Radcliffe AG, Ritchie JK, Hawley RP: Anovaginal and rectovaginal fistulas in Crohn's disease. *Dis Colon Rectum* 31:94-97, 1988
3. Rosenshein NB, Genadry RR, Woodruff JF: An anatomic classification of rectovaginal septal defects. *Am J Obstet Gynecol* 137:439-443, 1980
4. Nezhat C, Gary SB, Nezhat FR, et al: *Endometriosis: Advanced Management and Surgical Techniques*. New York, Springer-Verlag, 1995
5. Nezhat C, Nezhat FR, Pennington E: Laparoscopic treatment of infiltrative rectosigmoid colon and rectovaginal septum endometriosis by the technique of videolaparoscopy and the CO₂ laser. *Br J Obstet Gynaecol* 99:664-667, 1992
6. Nezhat C, Nezhat FR, Luciano AA, et al, eds: *Operative Gynecologic Laparoscopy: Principles and Techniques*. New York, McGraw-Hill, 1995
7. Ludwig KA, Milson JW, Church JM, et al: Preliminary experience with laparoscopic intestinal surgery for Crohn's disease. *Am J Surg* 67:817-821, 1996
8. Schwenk W, Bohm B, Grundel K, et al: Laparoscopic resection of high rectovaginal fistula with intracorporeal colorectal anastomosis and omentoplasty. *Surg Endosc* 11:147-149, 1997

