

2. Nezhat CH; Nezhat F; Nezhat CR; Rottenberg H.

Laparoscopic retropubic cystourethropexy.

Journal of the American Association of Gynecologic Laparoscopists, 1994 Aug,
1(4 Pt 1):339-49.

(UI: 97203342)

Aug. 1994

Abstract: STUDY OBJECTIVE: To evaluate the efficacy of laparoscopic retropubic urethrovesical suspension. DESIGN: Retrospective review of charts of 62 women over a follow-up period ranging from 8 to 30 months. SETTING: A suburban hospital in a major metropolitan area. PATIENTS: Sixty-two women, age 34 to 69 years, gravidity 0 to 8, and parity 0 to 7, with gynecologic abnormalities requiring surgical intervention and with pure genuine urinary stress incontinence. INTERVENTIONS: Each patient underwent a Burch or Marshall-Marchetti-Krantz procedure, modified to be performed at laparoscopy. MEASUREMENTS AND MAIN RESULTS: Success was measured subjectively and objectively. Subjective success, determined by the lack of need to wear pads, was 100%. Objective success was assessed using several criteria: comparison of preoperative and postoperative symptom diaries; questionnaires; urine characteristics by straight catheter (office dipstick for nitrate, leukocyte esterase, bacteria, and white cell blood count, if suspicious urine culture and sensitivity); postvoid residual volume (<100 ml was considered complete); urethrovesical junction angle as determined by catheter or Q-Tip placement (upward, downward, or straight); bladder support; and negative standing stress test. All women reported satisfactory relief of symptoms, with subjective and objective improvement. None have noted urinary leakage during activities similar to those preoperatively associated with this condition. CONCLUSION: To date, the outcomes have been acceptable, although the limited numbers and relatively short follow-up prohibit any definitive conclusions.

Laparoscopic Retropubic Cystourethropexy

Ceana H. Nezhad, M.D., Farr Nezhad, M.D., Camran R. Nezhad, M.D., and Howard Rottenberg, M.D.

Abstract

Study Objective. To evaluate the efficacy of laparoscopic retropubic urethrovesical suspension.

Design. Retrospective review of charts of 62 women over a follow-up period ranging from 8 to 30 months.

Setting. A suburban hospital in a major metropolitan area.

Patients. Sixty-two women, age 34 to 69 years, gravidity 0 to 8, and parity 0 to 7, with gynecologic abnormalities requiring surgical intervention and with pure genuine urinary stress incontinence.

Interventions. Each patient underwent a Burch or Marshall-Marchetti-Krantz procedure, modified to be performed at laparoscopy.

Measurements and Main Results. Success was measured subjectively and objectively. Subjective success, determined by the lack of need to wear pads, was 100%. Objective success was assessed using several criteria: comparison of preoperative and postoperative symptom diaries; questionnaires; urine characteristics by straight catheter (office dipstick for nitrate, leukocyte esterase, bacteria, and white cell blood count, if suspicious urine culture and sensitivity); postvoid residual volume (≤ 100 ml was considered complete); urethrovesical junction angle as determined by catheter or Q-Tip placement (upward, downward, or straight); bladder support; and negative standing stress test. All women reported satisfactory relief of symptoms, with subjective and objective improvement. None have noted urinary leakage during activities similar to those preoperatively associated with this condition.

Conclusion. To date, the outcomes have been acceptable, although the limited numbers and relatively short follow-up prohibit any definitive conclusions.

Urinary incontinence is becoming more prevalent as the population ages,^{1,2} with up to 20% to 40% of women reporting urine loss.¹⁻⁴ This disorder has a

profound effect on the individual woman and on society. The psychologic status of these patients improves significantly after the successful surgical cure of gen-

From the Center for Special Pelvic Surgery, Atlanta, Georgia; Department of Obstetrics and Gynecology, Mercer University School of Medicine, Macon, Georgia; and the Department of Obstetrics and Gynecology, Stanford University School of Medicine, Stanford, California (Dr. Nezhad). From the Department of Urology, Northside Hospital, Atlanta, Georgia (Dr. Rottenberg).

Address reprint requests to Camran R. Nezhad, M.D., 5555 Peachtree Dunwoody Road, Suite 276, Atlanta, GA 30342.

Presented at the 22nd annual meeting of the American Association of Gynecologic Laparoscopists, San Francisco.

uine stress incontinence.⁵ With over 160 corrective operations available, an optimum approach has yet to be determined, however.⁶

Among these procedures, retropubic urethropexy, both Marshall-Marchetti-Krantz⁷ and Burch,^{8,9} have the best outcomes and relatively few complications. Needle urethropexy¹⁰⁻¹⁴ is associated with shorter operating time and recovery period, and is less invasive. However, it is less effective than the abdominal approach, and is associated with more complications.¹⁵⁻¹⁸ Tanagho's modification of the Burch procedure¹⁹ is reported to have the best outcome in patients with pure genuine urinary stress incontinence with intact urethral sphincteric mechanism, poor urethral support, and a displaced urethrovesical junction.¹⁹⁻²³ Laparoscopic bladder neck suspension has been performed with good results.²⁴⁻²⁶

To provide women with the advantages of operative laparoscopy,²⁷ we applied this technique to bladder neck suspension. The advantages include improved laparoscopic visualization, which facilitates meticulous dissection of the space of Retzius, better bladder mobilization, and more prompt and precise hemostasis.²⁷

Materials and Methods

Sixty-two women, age 34 to 69 years, gravidity 0 to 8, and parity 0 to 7, with gynecologic abnormalities requiring operative laparoscopy and pure genuine stress incontinence were included in this study. Forty-eight (77.5%) were premenopausal and 14 (22.5%) were postmenopausal. Preoperatively, all postmenopausal women received at least 3 months of estrogen replacement therapy.

Preoperative evaluations were history and physical, gynecologic, and neurologic examinations. Emphasis was placed on evaluating and correcting, if possible, any factor that contributed to urinary incontinence (drugs, respiratory disease, etc.). Office tests were stress test (lithotomy and standing), Q-Tip test, urinalysis, urine culture and sensitivity, and blood chemistry.²⁸ All women had significant urine leakage during the stress test. All women underwent multi-channel urodynamic evaluation²⁹⁻³¹ in a urodynamic suite in the lithotomy and standing positions, with emphasis on voiding time, voiding volume, and postvoid residual urine volume. Tests included a waterfill cystometrogram with continuous urethral pressure monitoring and subtracted rectal and

abdominal pressures. Genuine stress incontinence was diagnosed by a positive stress test in the absence of simultaneous detrusor contractions or pressure equalization on the stress urethral closure pressure profile. All patients had normal detrusor function on cystometrogram.

Only women with pure genuine stress incontinence and intact sphincter mechanism were included; those with mixed incontinence, detrusor instability, or impaired sphincter function were excluded. Twenty-four to 48-hour symptom diaries were obtained and placed in each chart. The patients were instructed in self-catheterization, and each one completed a questionnaire regarding incontinence and its severity.

Operative Technique

After induction of general endotracheal anesthesia, the patients were placed in Allen stirrups, which permitted the assistant to perform a vaginal examination. A Foley catheter was placed in the urethra and bladder. A 10-mm operative videolaparoscope was inserted infraumbilically, and three 5-mm accessory cannulas were inserted, (Figure 1). The middle cannula was 5 to 6 cm above the symphysis pubis, and the other two were 7 to 8 cm above the symphysis pubis lateral to the umbilical ligaments, avoiding injury to the inferior epigastric vessels. The carbon dioxide (CO₂) laser was placed through the operative channel of the 10-mm laparoscope and used as a long knife. Through the accessory cannulas we introduced the suction irrigator, grasping forceps, needle holder, and bipolar electrocoagulator.²⁷

We carefully inspected the intraperitoneal cavity to detect any pelvic abnormalities requiring surgical treatment, such as adhesions or endometriosis. First, any indicated gynecologic procedures were performed: laparoscopic hysterectomy with or without removal of adnexae (38 women); removal of adnexae (16); and treatment of endometriosis or adhesions (8). In 12 patients with a deep pelvis and 4 with an enterocele, a modified Moschowitz procedure using 0 polyglactin Endoknot (Ethicon, Inc., Somerville, NJ) (3 patients) or Ethibond (Ethicon) (13 patients) was performed to obliterate the cul-de-sac. In summary, after identifying the ureters, the lateral peritoneum was elevated, and the suture was placed through the peritoneum and passed through the cul-de-sac base, the opposite side of the peritoneum, and the anterior rectosigmoid colon serosa.

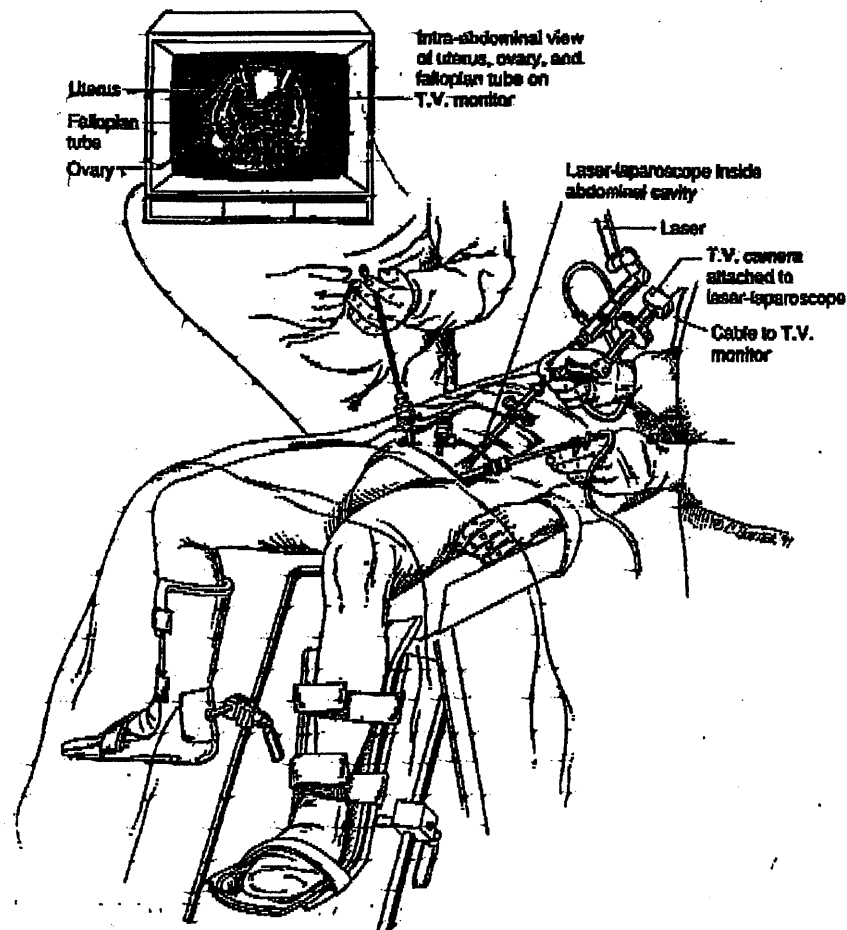


FIGURE 1. Room setup and location of the suprapubic incisions.

Two options are available for entering the space of Retzius intrabdominally, manual dissection and balloon dissection.

Manual Dissection

The anterior abdominal wall peritoneum 3 to 5 cm above the symphysis pubis was pulled down with grasping forceps placed through a lateral accessory cannula (Figure 2). A transverse incision was made with the CO₂ laser or scissors caudal to the midsuprapubic cannula above the symphysis pubis on the peritoneum between the two umbilical ligaments. The midline cannula entry and anatomic landmarks, including the round ligament from the internal ring, were used to avoid bladder entry. We used blunt dissection, hydrodissection, and the CO₂ laser for sharp dissection to expose the retropubic space (Figure 3).

We stayed close to the back of the pubic bone, dropping the anterior bladder wall, vaginal wall, and urethra downward. Dissection was limited over the urethra in the midline to approximately 2-cm lateral to the urethra to protect its delicate musculature. An assistant performed a vaginal examination with one finger on each side of the catheterized urethra, elevating the lateral vaginal fornix. The overlying fibrofatty tissue was cleared from the anterior vaginal wall under video-laparoscopic magnification. Beginning laterally, the bladder was dissected medially from the paravaginal fascia. The thin-walled venous plexus in this extremely vascular area was identified and protected from surgical trauma. Pneumoperitoneal pressure and the CO₂ laser helped control bleeding from small vessels. Hydrodissection, blunt dissection (suction-irrigator probe), and sharp dissection (CO₂ laser)

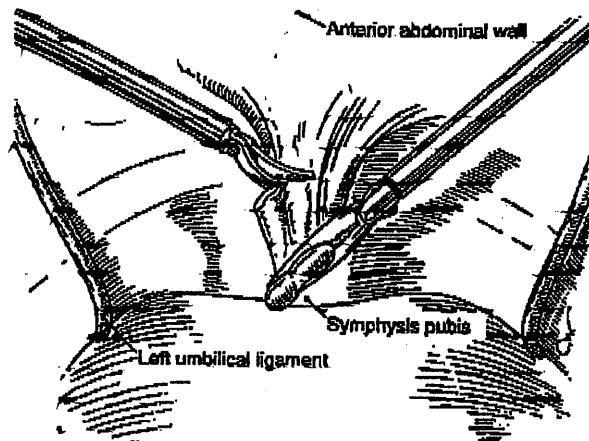


FIGURE 2. An incision is made in the peritoneum 3 to 5 cm above the symphysis pubis.

were continued until the urethrovesical junction became apparent and the white, glistening tissue of the paravaginal fascia appeared. Every effort was made to protect the muscle fibers of the urethrovesical junction from surgical dissection. Bleeding in this area was controlled with bipolar electrodesiccation.

After mobilizing the vesical urethral segment so that it could be lifted to a normal position, retropubic dissection was continued until Cooper's ligament was exposed (40 patients). Pneumoperitoneal pressure provided clear exposure of the space and its contents out to the obturator nerve. This nerve and occasionally the aberrant obturator vein were identified and protected from surgical trauma. In the other 22 patients the middle portion of the periosteum was completely cleared of fibrofatty tissue.

Balloon Dissection

The recently developed balloon dissector (General Surgical Innovations, Inc., Portola Valley, CA) consists of a cannula, a guide rod, and a balloon system (Figure 4). The dissector is inserted through a 1-cm infraumbilical incision (Figure 5). It is advanced between the rectus muscle and the anterior surface of the posterior rectus sheath to the symphysis pubis. The dissector's external sheath is removed, and the balloon is inflated with approximately 750 ml of saline solution. During inflation, the balloon unrolls sideways and exerts a perpendicular force that separates tissue layers (Figure 6). Blunt dissection of the connective tissues is propagated as the balloon

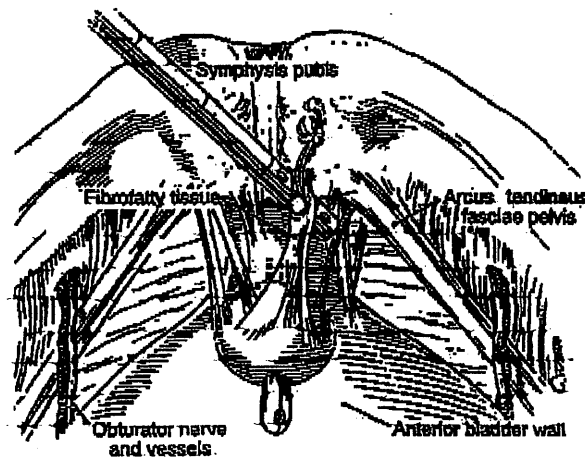


FIGURE 3. The space of Retzius is developed using blunt and CO₂ dissection of fibrofatty tissue. Care is taken to avoid injuring the obturator nerve and vessels.

expands. Full dissection takes about 1 minute. When maximum volume is reached, the balloon is deflated and removed through the incision. The dissected space is insufflated with CO₂ at a pressure of 8 to 10 mm Hg.

The predefined shape of the balloon, its nonelastomeric material, and the incompressible character of the saline ensure a large, relatively bloodless working space of predictable size and shape. The space is adequate for identifying pertinent landmarks, and for unencumbered manipulation of endoscopic surgical instruments.

After complete dissection, the paravaginal fascia was identified. Using an atraumatic grasping forceps,




FIGURE 4. The balloon dissector device (General Surgical Innovations, Portola Valley, CA).

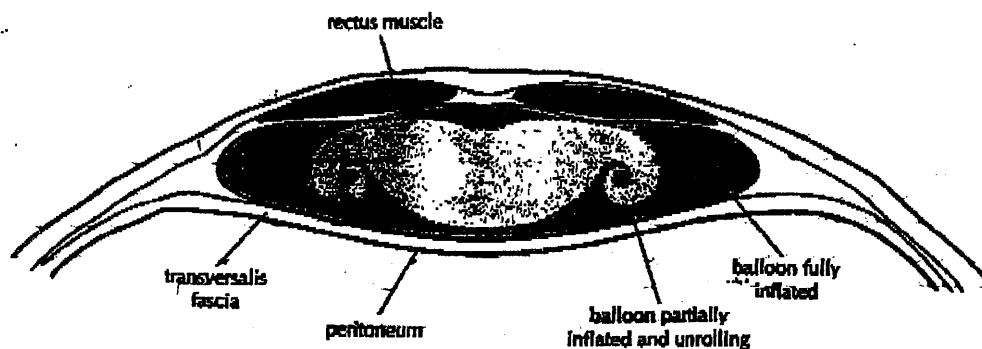


FIGURE 5. The balloon dissector is inserted infraumbilically and advanced to the symphysis pubis. The outlines delineate the balloon at various stages of expansion within the extraperitoneal space.

a bite of the paravaginal fascia was elevated and a suture (0 polyglactin in 14, 0 Ethibond in 48) was placed at the level of the urethrovesical junction, approximately 1 to 1.5 cm from the urethra (Figure 7). This was facilitated by the Foley bulb of the catheter under gentle traction. The suture was placed perpendicular to the vaginal axis to include approximately 0.5 to 1 cm of tissue (the complete vaginal fas-

cia), but not to penetrate the vaginal mucosa.

The patient was placed in deep Trendelenburg position and rotated left to facilitate left-handed suture placement, with the assistant's finger as a guide. The suture was then fixed to Cooper's ligament (Figures 8 and 9) or the midline of the symphysis pubis fibrocartilage (Figure 10) depending on the surgeon's preference and whether a cystocele was

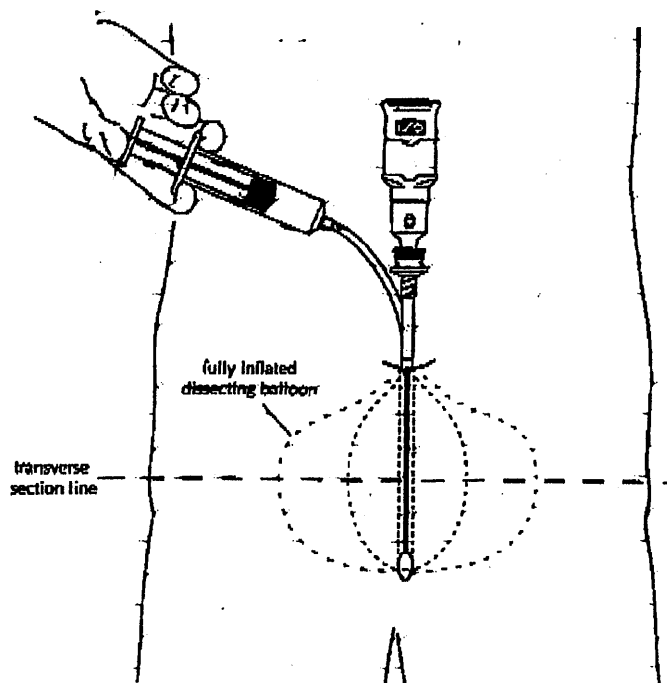


FIGURE 6. A view of the transverse plane. As the balloon is inflated with saline solution, it unrolls and dissects the tissue layers.

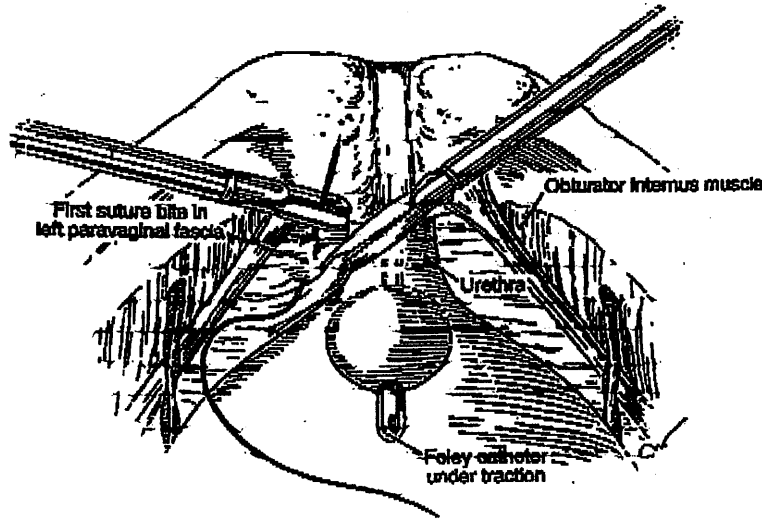


FIGURE 7. A no. 0 Ethibond suture is placed 1 to 1.5 cm from the urethra. The assistant's finger is used to elevate the paravaginal fascia and guide the surgeon.

present. If there was a low cystocele, a modified Burch technique was used. The sutures were tied either intracorporeally or extracorporeally with help from an assistant who lifted the vagina upward and forward. Direct visualization assisted in avoiding excess tension in the vaginal wall while tying the suture. The urethra was observed, which helped prevent it from being compressed against the pubic bone. This suturing was repeated on the opposite side, the goal being to create a platform on which the bladder neck could rest, while avoiding cinching. If

the suspension was judged inadequate by visual inspection, manual elevation, or cystoscopy, a second (4 cases) and, only once, a third set of sutures was placed cephalad along the base of the bladder.

Flexible cystoscopy was performed to ensure that no suture material was in the bladder, and to assess the urethrovesical junction angle and urethral patency. Pneumoperitoneal pressure was decreased and the retropubic space was thoroughly evaluated. Bleeding was controlled with bipolar electrodesiccation. The peritoneal defect was left open to heal

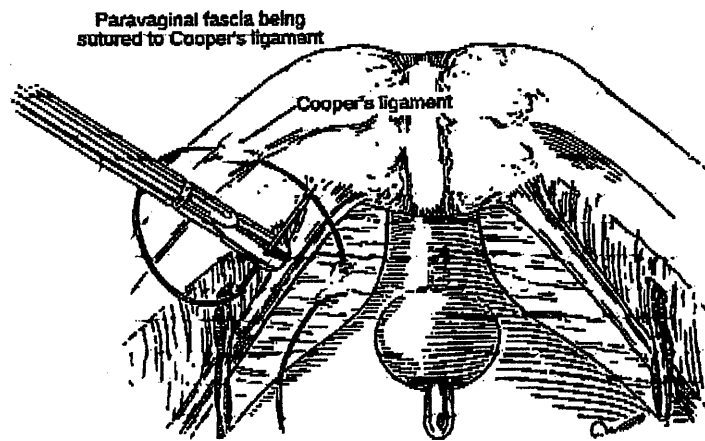


FIGURE 8. The suture is passed through Cooper's ligament in the Burch procedure.

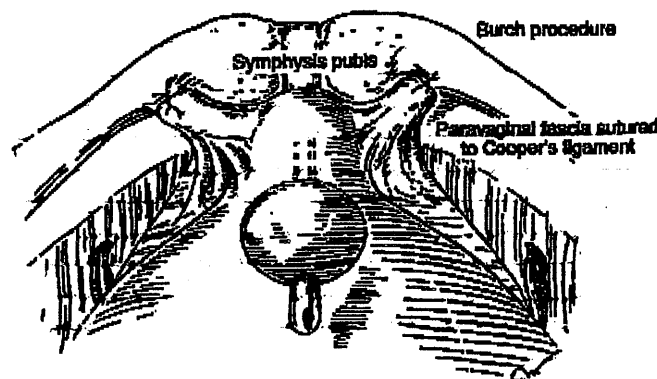


FIGURE 9. Suture is tied extracorporeally or intracorporeally, elevating the urethrovesical angle.

spontaneously in 40 cases. In the remainder, the defect had enlarged and was closed laparoscopically with 3 to 4 interrupted 4-0 polydioxanone (Ethicon) sutures. The laparoscope was then withdrawn from the abdomen and the procedure terminated. The transurethral Foley catheter remained in place for 2 to 3 days, except in one patient who had a cystostomy. Her Foley catheter was removed 1 week later, after a normal cystogram.

Pelvic rest was instructed for 6 to 8 weeks postoperatively, and the women were told to avoid heavy lifting and strenuous exercise for at least 2 months. They were also asked to keep a 24-hour symptom diary, similar to the one they kept preoperatively, before their 2- and 6-week postoperative visits.

All women received perioperative first-generation cephalosporin as prophylactic intravenous antibiotics, followed by a course of oral antibiotics for 5

days or until self-catheterization was discontinued, whichever was longer.

Results

The operative times for retropubic urethropexy procedure ranged from 30 to 45 minutes. This duration was calculated from the time we entered the space of Retzius until we repaired the peritoneal defect. The variation depended on the time necessary to dissect adipose tissue, and the number of sutures placed. Placement of a second set of sutures adds approximately 5 minutes to the operative time. Blood loss ranged from 10 to 60 ml. All procedures were begun and completed laparoscopically, with no conversions to laparotomy.

One bladder perforation occurred during bladder dissection and entry into the space of Retzius. It was

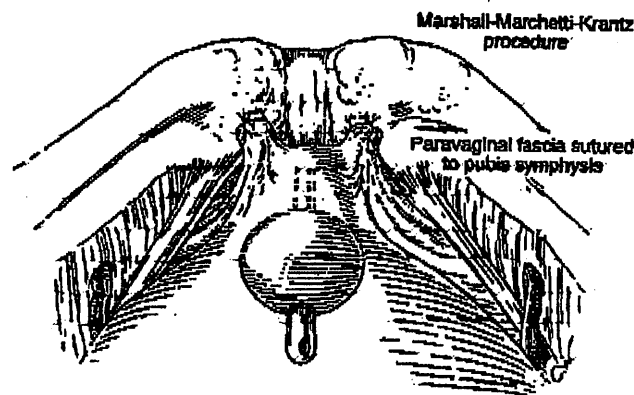


FIGURE 10. In the Marshall-Marchetti-Krantz procedure the paravaginal fascia is sutured to the symphysis pubis.

repaired laparoscopically in one layer using 0 polyglactin interrupted sutures.²¹ One patient developed an incisional hernia at the site of the midline suprapubic cannula, although the fascia had been repaired with one interrupted, absorbable suture. The 5-mm cannula was exchanged for a 10-mm one to remove the adnexa, which had been placed in a bag. The hernia was repaired on an outpatient basis, and 8 months later the patient was completely asymptomatic. Postoperatively, a 68-year-old woman was unable to void. She underwent bilateral salpingo-oophorectomy for a persistent ovarian cyst, a Moschcowitz procedure, and Burch retropubic urethropexy. She required self-catheterization for 10 days. Nine women had dysuria without infection that resolved with Pyridium (Parke-Davis, Morris Plains, NJ).

Fifty-eight women voided after removal of the Foley catheter on the second or third postoperative day. Other than the woman noted above, three required self-catheterization (one 3 times, two once) for inability to void. They kept a record of voided and residual urine volumes at home, and discontinued self-catheterization when postvoid residual was less than 100 ml. The average hospital stay, calculated from the end of the procedure until the patient was discharged, was 39 hours; this figure is slightly skewed because four women remained in the hospital longer than average (Table 1). Without those four, the average stay was 35.7 hours.

No postoperative febrile morbidity was noted, and no patients required retropubic drainage. Seventeen women were discharged 19 hours postoperatively with a Foley catheter in place and were taught how to decatheterize themselves in 3 days.

TABLE 1. Length of Hospital Stay for 62 Women After Laparoscopic Retropubic Cystourethropexy

No. of Average Patients	Length of Stay* (hrs/patient)	Total Hours/Group	Cumulative (hrs)
17	19	323	19.0
39	43	1677	35.7
4	62	248	37.5
1	77	77	38.1
1	93	93	38.1
Totals 62		2418	39.0

*Calculated from termination of operation to discharge.

Thirty-nine were discharged 43 hours postoperatively because of associated surgical procedures (hysterectomy with or without vaginal repair 22, anterior and posterior repair 2, or patient preference 15). Their catheters were removed before they were discharged. Seven of the 39 had limited postoperative activity for 24 hours due to extensive genital prolapse repair (4) or patient preference (3). The remaining 32 were ambulatory 6 to 12 hours postoperatively based on the time of day their procedure was concluded. Six women remained in the hospital for 62 to 93 hours for several reasons, including concomitant extensive pelvic pathology (5) or patient preference (1 had a very low pain threshold).

Five patients had symptomatic leakage with some or no relief postoperatively. Repeat urodynamic testing confirmed suspected detrusor instability in four women that responded to oxybutynin and bladder retraining. One patient reported no change in preoperative and postoperative incontinence. Complete work-up including videocourodynamics did not reveal an abnormality. She was prescribed flavoxate 100 mg, 2 tablets 3 to 4 times/day, which resolved her symptoms completely. Eleven months later she was continent. Eighteen patients had symptoms of urgency and dysuria; these were relieved with phenazopyridine hydrochloride (Parke-Davis).

Postoperative outcomes were calculated as percentages and the total percentage of subjective and objective improvement (Table 2). In 8- to 30-month follow-up, all patients reported satisfactory relief of symptoms, and subjective and objective improvement. None experienced urinary leakage during activities similar to those preoperatively associated with this condition. Subjective success was determined by questionnaire about urine leakage, and the absence of need to wear pads; no women needed them. Permeal pad test was not performed, as its variability and high false positive rate renders its usefulness controversial.^{22,23}

Objective success was assessed by several criteria: comparison of preoperative and postoperative symptom diaries; urine characteristics by straight catheter (office dipstick for nitrate, leukocyte esterase, bacteria, and white cell blood count if urine culture and sensitivity were suspicious); postvoid residual volume (<100 ml was considered complete); urethrovaginal junction angle as determined by catheter and/or Q-Tip placement (upward, downward, or straight); bladder support; and negative standing stress test. All

TABLE 2. Postoperative Improvement

Improvement (%)	Activity	Leakage	Pad Required	No. Times Changed/Day	No. of Patients
81-100	Sneezing, coughing, laughing	None to rare	No	NA	57
61-80	Sneezing, coughing, laughing	Occasional	Rarely	NA	1 ^a
41-60	Sneezing, coughing, laughing	Predictable with activity	On occasion	1-3	0
21-40	Minimal activity (walking)	>3 x/day	Yes	<4	1 ^a
0-20	At rest	Frequently	Yes	>4	2 ^a /1 ^b

^aAll had detrusor instability with 90% to 100% relief with medical management.

^bThis patient had a normal intravenous pyelogram and videourodynamics. Her symptoms resolved with flavoxate.

women were asked to complete a questionnaire similar to the one they filled out preoperatively. Emphasis was placed on the presence or absence of urine leakage and the need to wear a pad at rest, at different activity levels, and different urine volumes in the bladder.

Discussion

This study was undertaken to determine the efficacy of a laparoscopic retropubic cystourethropey. We found this approach useful for selected women undergoing operative laparoscopy for concomitant pelvic pathology associated with primary pure genuine stress incontinence. An experienced laparoscopic surgeon may also consider it to be effective, with some advantages over more commonly performed techniques, such as abdominal retropubic urethropey and needle urethropey.

Although the principles of an abdominal approach are followed, the disadvantages of a laparotomy incision are avoided. Because the sutures are deep in the pelvis, the problems with bolsters and sutures that occur with needle procedures are unusual in laparoscopy. Elevation of the bladder neck depends on the scarring of the paravesical tissue to the symphysis pubis or pelvic sidewall, not on the two paraurethral sutures as in the needle procedure. Furthermore, this is not a blind operation, and we believe that visualization is better than at laparotomy.

Like laparotomy, laparoscopy allows diagnosis and prompt treatment of pelvic pathology including endometriosis and adhesions, and the removal of diseased organs if necessary. We believe genuine urinary stress incontinence may be corrected laparoscopically with comparable results, and we found it to be less traumatic and invasive, with decreased operative time, postoperative recovery, and morbidity.

The balloon dissector is an effective alternative to manual dissection of the space of Retzius. It achieves the necessary working space quickly, reducing the need for manual dissection instruments and lowering the risk of complication.

We believe the actual frequency of osteitis to be less than the reported 5% with Marshall-Marchetti-Krantz procedures,⁷ and none of our patients experienced such a problem. This may be attributed to the factors mentioned above. The reported frequency of enterocele after the Burch procedure ranges from 3% to 17%.^{8,9,36,37} In a recent study, up to 26.7% of women experienced genital prolapse after Burch colposuspension.³⁸ It is unclear whether the etiologic factor is the disruption of the vaginal axis or an intrinsic weakness of the pelvic floor in these women. The patients in our series did not experience these complications. Although our follow-up was short, assessing the posterior cul-de-sac and performing Moschowitz procedure (when necessary) may be contributing factors.

It is interesting to note that although 18% of

postoperative detrusor instability occurred after this procedure by laparotomy.⁹ 8% of our patients had this problem. Our series was small, and the difference may be attributed to more meticulous dissection and better hemostasis in this area. In addition, the bladder mucosa was not penetrated by sutures in any patients.

Summary

The small series and short follow-up discourage definitive conclusions, even though our preliminary results are promising, with subjective and objective success rates averaging over 90%. Our success rate was defined by the patient's satisfaction and absence of urine leakage based on the comparison of symptom diaries and questionnaires regarding similar preoperative and postoperative activities. We found that a laparoscopic approach achieved favorable results and afforded patients the benefits of a smaller incision, decreased blood loss, and shorter hospitalization and recovery period. Furthermore, the number of complications decreased overall. This technique may prove to be a good alternative to abdominal retropubic urethropey when performed by an experienced surgeon for carefully selected patients at operative laparoscopy for other pathology.

References

1. Thomas JM, Flynn DR, Blannin J, et al: Prevalence of urinary incontinence. *Br Med J* 281:1243-1245, 1980
2. Diokno AC, Brock BM, Brown MD, et al: Prevalence of urinary incontinence and other urological symptoms in the noninstitutionalized elderly. *J Urol* 136: 1022-1025, 1986
3. Yarnell JW, St. Leger AS: The prevalence, severity and factors associated with urinary incontinence in a random sample of the elderly. *Age Aging* 8:81-85, 1979
4. Holst K, Wilson PD: The prevalence of female urinary incontinence and reasons for not seeking treatment. *NZ Med J* 101:756-758, 1988
5. Rosenzweig BA, Hischke MD, Thomas S, et al: Stress incontinence in women: Psychological status before and after treatment. *J Reprod Med* 36:835-838, 1991
6. Horbach NS: Genuine SUI: Best surgical approach. *Contemp Obstet Gynecol* 37:53-61, 1992
7. Marshall VF, Marchetti AA, Krantz KE: The correction stress incontinence by simple vesicourethral suspension. *Surg Gynecol Obstet* 88:509-518, 1941
8. Burch JC: Cooper's ligament urethrovesical suspension for stress incontinence. *Am J Obstet Gynecol* 100:764-772, 1968
9. Stanton SL: Colposuspension. In *Surgery of Female Incontinence*, 2nd ed. Edited by SL Stanton, E Tanagho. New York, Springer-Verlag, 1986, pp 95-103
10. McGuire EJ, Lytton B: Pubovaginal sling procedure for stress incontinence. *J Urol* 119:82-84, 1978
11. Pereyra AJ, Leberer TB: Combined urethrovesical suspension and vaginourethroplasty for correction of urinary stress incontinence. *Obstet Gynecol* 30:537-546, 1967
12. Raz S: Modified bladder neck suspension for female stress incontinence. *Urology* 17:82-85, 1981
13. Hohnfeller R, Petrie E: Sling procedures in surgery. In *Surgery of Female Incontinence*, 2nd ed. Edited by SL Stanton, E Tanagho. Berlin, Springer-Verlag, 1986, pp 105-113
14. Gittes RF, Loughlin KR: No incision pubovaginal suspension for stress incontinence. *J Urol* 138:568-570, 1987
15. Bhatia NN, Bergman A: A modified Burch versus Pereyra retropubic urethropey for stress urinary incontinence. *Obstet Gynecol* 66:255-261, 1985
16. Mundy AR: A trial comparing the Stamey bladder neck suspension procedure with colposuspension for the treatment of stress incontinence. *Br J Urol* 33:687-690, 1983
17. Green DF, McGuire EJ, Lytton B: A comparison of endoscopic suspension of the vesical neck versus anterior urethropey for the treatment of stress urinary incontinence. *J Urol* 136:1205-1207, 1986
18. Karram MM, Bhatia NN: Transvaginal needle bladder neck suspension procedures for stress urinary incontinence: A comprehensive review. *Obstet Gynecol* 73:906-914, 1989
19. Tanagho EA: Colprocystourethropey: The way we do it. *J Urol* 116:751-753, 1976
20. Bergman A, Ballard C, Koonings P: Primary stress urinary incontinence and pelvic relaxation: Prospective randomized comparison of three different operations. *Am J Obstet Gynecol* 161:97-101, 1989

21. Bergman A, Ballard C, Koonings F: Comparison of three different surgical procedures for genuine stress incontinence: Prospective randomized study. *Am J Obstet Gynecol* 160:1102-1106, 1989
22. Penttinen J, Lindholm EL, Kaar K, et al: Successful colposuspension in stress urinary incontinence reduces bladder neck mobility and increases pressure transmission to the urethra. *Acta Gynecol Obstet* 224:233-238, 1989
23. Van Geelen JM, Theeuwes AGM, Eskes TKAB, et al: The clinical and urodynamic effects of anterior vaginal repair and Burch colposuspension. *Am J Obstet Gynecol* 159:137-144, 1989
24. Vancallie TG, Schuessler W: Laparoscopic bladderneck suspension. *J Laparosc Surg* 1:169-173, 1991
25. Liu C, Paek W: Laparoscopic retropubic colposuspension (Burch procedure). *J Am Assoc Gynecol Laparosc* 1:31-35, 1993
26. Ou C, Presthus J, Beadle E: Laparoscopic bladder neck suspension using hernia mesh and surgical staples. *J Laparosc Surg* 3:563-566, 1993
27. Nezhat C, Nezhat F, Nezhat C: Operative laparoscopy (minimally invasive surgery): State of the art. *J Gynecol Surg* 8:111-141, 1992
28. Walters M, Shields L: The diagnostic value of history, physical examination and the Q-Tip cotton swab test in women with urinary incontinence. *Am J Obstet Gynecol* 159:145-149, 1988
29. Hilton P, Stanton SL: A clinical and urodynamic assessment of the Burch colposuspension for genuine stress incontinence. *Br J Obstet Gynaecol* 90:934-939, 1983
30. Bergman A, Bhatia NN: Uroflowmetry for predicting postoperative voiding difficulties in women with SUL Br *J Obstet Gynecol* 92:833-838, 1985
31. Bhatia NN, Bergman A: Use of preoperative uroflowmetry and simultaneous urethrocytometry for predicting risk of prolonged postoperative bladder drainage. *Urology* 28:440-445, 1985
32. Nezhat F, Nezhat C: Laparoscopic segmental bladder resection for endometriosis: A report of two cases. *Obstet Gynecol* 81:882-884, 1993
33. Wall LL, Wank K, Robson J, et al: The Pyridium pad test for diagnosing urinary incontinence. A comparative study of asymptomatic and incontinent women. *J Reprod Med* 35:682-684, 1990
34. Walters MD, Dombroski RA, Prihoda TJ: Perineal pad testing in the quantitation of urinary incontinence. *Int Urogynecol J* 1:3-6, 1990
35. Griffiths DJ, McCracken PN, Harrison GM: Incontinence in the elderly: Objective demonstration and quantitative assessment. *Br J Urol* 67:467-471, 1991
36. Burch JC: Urethrovaginal fixation to Cooper's ligament for correction of stress incontinence, cystocele, and prolapse. *Am J Obstet Gynecol* 81:281-290, 1961
37. Stanton SL: The Burch colposuspension procedure. *Acta Urol Belg* 52:280-282, 1984
38. Wiskind AK, Creighton SM, Stanton SL: The incidence of genital prolapse after the Burch colposuspension. *Am J Obstet Gynecol* 176:399-405, 1992
39. Cardozo LD, Stanton SL, William JE: Detrusor instability following surgery for genuine stress urinary incontinence. *Br J Urol* 51:204-207, 1979