

Nov-1993

Laparoscopic Radical Hysterectomy and Laparoscopically Assisted Vaginal Radical Hysterectomy with Pelvic and Paraaortic Node Dissection

CAMRAN R. NEZHAT, M.D.,^{1,2} FARR R. NEZHAT, M.D.,^{1,2}
MATTHEW O. BURRELL, M.D.,³ CARLOS E. RAMIREZ, M.D.,⁴
CHARLES WELANDER, M.D.,⁵ JESUS CARRODEGUAS, M.D.,⁴ and
CEANA H. NEZHAT, M.D.¹

ABSTRACT

Nineteen women underwent laparoscopic radical hysterectomy or laparoscopically assisted vaginal radical hysterectomy, with pelvic node dissection and paraaortic node dissection when indicated. One procedure was converted to laparotomy due to equipment failure (at The University of Puerto Rico). There were two minor postoperative complications. The first, febrile morbidity resulting from a urinary tract infection, responded to medical therapy. The second was incisional bleeding, which was controlled with sutures applied using a local anesthetic. No major postoperative complications were noted, there have been no incidents of recurrence, and the follow-up results are encouraging. (J GYNECOL SURG 9:105, 1993)

INTRODUCTION

ADVANCEMENTS IN OPERATIVE LAPAROSCOPY allow precise intraabdominal and retroperitoneal surgery to treat many conditions.¹ Case reports on pelvic node dissection,² laparoscopic radical hysterectomy with paraaortic and pelvic node dissection,³ and vaginally assisted laparoscopic radical hysterectomy with pelvic node dissection⁴ have been published. A series of laparoscopic and laparoscopically assisted vaginal radical hysterectomies with paraaortic and pelvic lymphadenectomies were performed to treat stages Ia2, IB, and IIA cervical cancer.

THIS MATERIAL MAY BE PROTECTED BY
COPYRIGHT LAW TITLE 17 U.S. CODE

¹Center for Special Pelvic Surgery, Atlanta, Georgia.

²Department of Obstetrics and Gynecology, Mercer University School of Medicine, Macon, Georgia.

³Institute for Gynecologic Oncology, Atlanta, Georgia.

⁴Division of Gyn-Oncology, Puerto Rico School of Medicine, Gonzalez-Martinez-Oncologic Hospital, San Juan, Puerto Rico.

⁵University of Vermont, Department of Obstetrics & Gynecology, Burlington, Vermont.

MATERIALS AND METHODS

Between June 1989 and December 1992, 19 women, aged 24–55 years, underwent laparoscopic radical hysterectomy or laparoscopically assisted vaginal radical hysterectomy with pelvic node dissection, and paraaortic node dissection (as required) to treat stages Ia2, IB, and IIA cervical cancer. The specific indications for surgery are detailed in Table 1. All patients were staged, under anesthesia, according to FIGO classifications (Table 2).

Following thorough consultations with each patient, appropriate consent forms were obtained. These included an acknowledgment that a laparoscopic approach to managing malignancy was not the standard treatment at the present time and that laparotomy was possible if laparoscopic treatment was not adequate.

Preoperatively, each woman had a standard mechanical and antibiotic bowel preparation.¹ She received a betadine douche the night before and immediately before the surgery. In addition, one 2 g dose of cefoxitin (Mefoxin, Merck, Sharp & Dohme, West Point, PA) was administered 1 h preoperatively, and 1 g was administered at 6 h and 12 h postoperatively.

The procedures were performed under general endotracheal anesthesia, with the patients in a modified dorsal lithotomy position. As these procedures tend to be long, we use a sequential pneumatic sleeve intraoperatively to prevent venous thrombosis disease. The operating room setup has been described previously in detail.⁵ Multiple puncture operative videolaparoscopy was used (Fig. 1). The CO₂ laser was used through the operative channel of the laparoscope to cut and dissect, and bipolar electrocoagulation was used for coagulating large blood vessels (Figs. 1, 2).^{1,3}

Early in this study, one operation was converted to laparotomy because of equipment failure and was excluded from this series.

Seven patients underwent laparoscopic radical hysterectomy as follows.³ After inserting the ports, the upper abdomen and pelvis are inspected. The right common iliac and paraaortic lymphadenectomy is undertaken first. To expose the paraaortic region, the patient is tilted to the left and placed in a deep

TABLE 1. SUMMARY OF PATIENT INFORMATION

	Age	Stage of cancer	No. of pelvic nodes	No. of paraaortic nodes	Follow-up (months)
1	24	Ia2	17	NI*	4
2	33	Ia2	15	NI	3
3	37	Ia2	18	NI	3
4	40	Ia2	22	NI	6
5	41	Ia2	23	NI	4
6	34	Ia2	33	NI	3
7	31	Ia2	25	9	42
8	30	Ia2	14	5	30
9	37	Ia2	18	4	20
10	40	Ia2	21	NI	11
11	26	IB	21	3	5
12	35	IB	27	4	5
13	41	IB	19	6	2
14	43	IB	25	4	2
15	47	IB	29	5	3
16	29	IB	27	8	18
17	34	IB	26	7	15
18	55	IIA	11	5	9

*Not indicated.

TABLE 2. SUMMARY OF PATIENT STAGING

No. of patients	FIGO staging	Pathologic diagnosis
9	Ia2	Squamous cell carcinoma
1	Ia2	Adenocarcinoma
7	IB	Squamous cell carcinoma lesions between 1 and 2 cm
1	IIA	Squamous cell carcinoma

Trendelenburg position (35–40 degrees). The bowel is gently directed toward the diaphragm and occasionally held in place using the grasping forceps. The ureter is identified through the peritoneum (Fig. 2). An opening is made in the peritoneum just above the sacral promontory. Lactated Ringer's solution is injected into the retroperitoneal space. The peritoneum above this opening is grasped and incised with the CO₂ laser toward the duodenal bulb. The remaining retroperitoneum is opened in a similar fashion. The common iliac and paraaortic nodes from the surface of the veins are removed using a combination of blunt dissection.

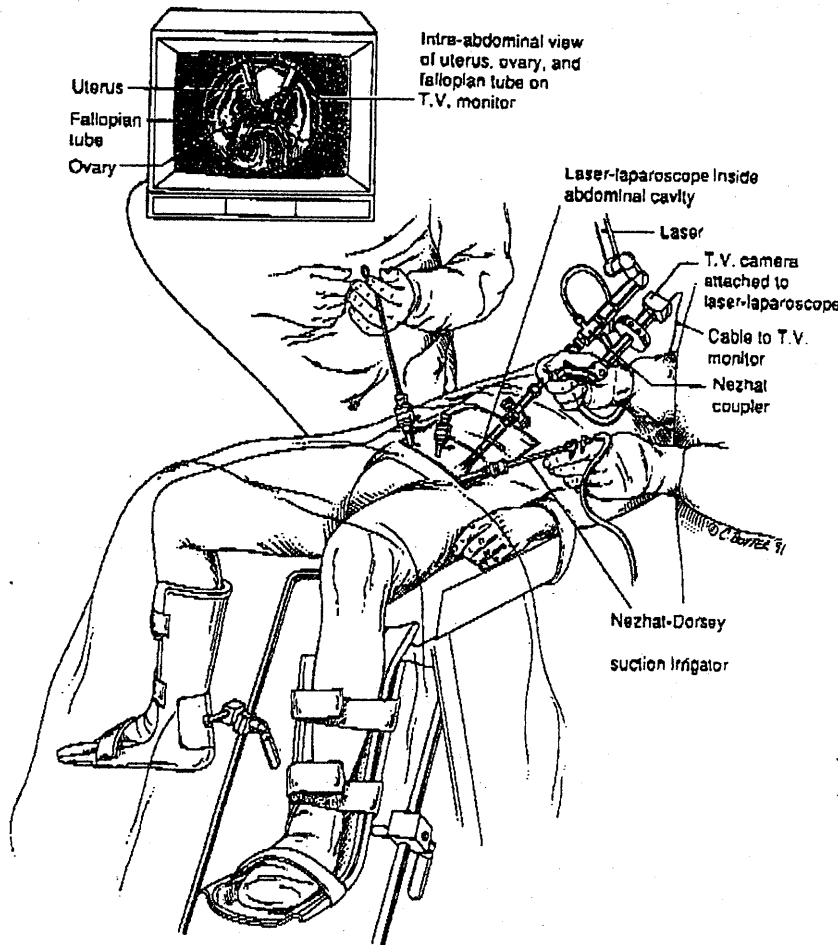


FIG. 1. Room setup.

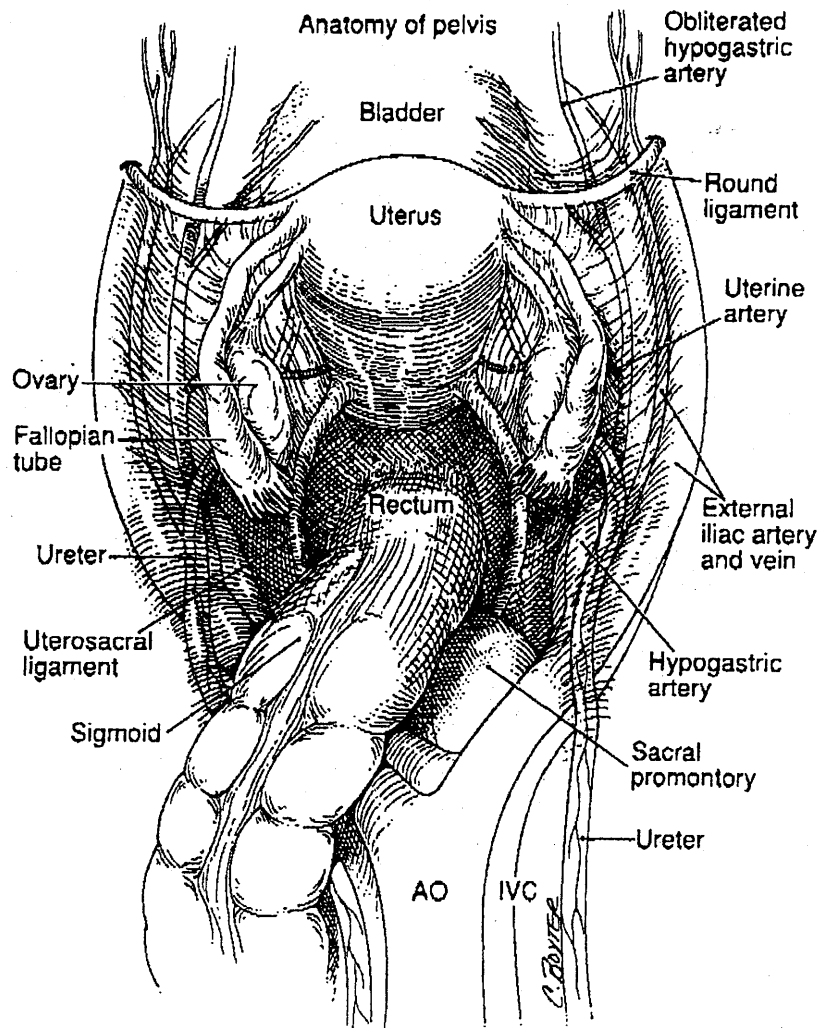


FIG. 2. Anatomy of the pelvis. AO, aorta; IVC, inferior vena cava.

hydrodissection, and CO₂ laser (Figs. 3, 4). All nodes over the distal vena cava are removed, beginning at the inferior mesenteric artery and proceeding to the right common iliac artery. Larger bleeders, such as the venous perforators of the vena cava, are coagulated with bipolar electrocoagulation. The ureter is carefully identified immediately next to the vena cava, and the dissection is taken to approximately 2–5 cm above the aortic bifurcation (Figs. 3, 4). All removed tissue is carefully passed into the trocar sleeve (5 mm accessory or 11 mm laparoscopic port), avoiding direct contact between the specimen and abdominal wall. Attention is then directed toward dissecting the rectovaginal, paravesical, and pararectal spaces (Figs. 5, 6, 7, 8, 9). An assistant performs simultaneous rectal and vaginal examination, delineating the septum.⁶ The cul-de-sac and any focal areas of endometriosis are incised, and the rectum is pushed from the posterior vaginal wall using the CO₂ laser, blunt dissection, and hydrodissection. This is taken down to 4–5 cm below the cervix (Figs. 5, 6).⁶

The round and tuboovarian ligaments are coagulated close to the pelvic side walls and transected. The peritoneum is opened, and the paravesical and pararectal spaces are dissected by blunt dissection.

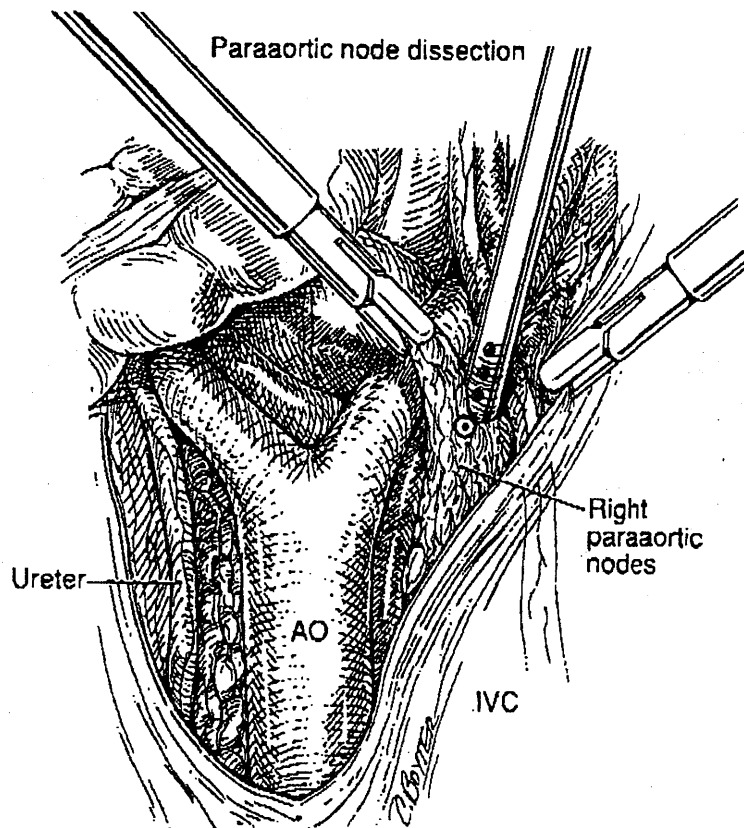


FIG. 3. Right paraaortic node dissection. AO, aorta; IVC, inferior vena cava.

hydrodissection, and the CO₂ laser. This technique allows excellent skeletonization of the obliterated hypogastric artery. The uterine vessels are identified, skeletonized, and coagulated just medial to their origin and transected (Figs. 9, 10, 11). They are grasped with the forceps and rotated anterior to the ureters.

The bladder serosa is injected with Ringer's lactate solution.⁷ The bladder is advanced using the CO₂ laser and countertraction.⁷⁻⁹ After division of any scar tissue in the vesicouterine fold, the suction-irrigator probe is used for blunt mobilization of the bladder (Figs. 12, 13, 14).

The uterine vessels are retracted medially and removed from the ureter using the CO₂ laser. The anterior parametrium is transected using the laser. The suction-irrigator probe may be used as a backstop to protect the ureter. The ureters are freed from the peritoneum and skeletonized down to the bladder using the suction-irrigator probe and the laser. The uteroovarian pedicles are coagulated with bipolar electrocoagulation and transected with the laser.^{8,9}

The left paraaortic nodes and common iliac nodes are removed in a fashion similar to that used on the right side (Fig. 4). All nodes between the left ureter and aorta from the inferior mesenteric artery to the left mid-common iliac artery were excised. The remaining pelvic nodes also are removed using the CO₂ laser, blunt dissection, and hydrodissection (Fig. 10).⁷ The removal of these nodes conforms to the guidelines established by the Gynecologic Oncology Group.¹⁰

The external iliac nodes between the external iliac vein and artery and the obliterated hypogastric artery are carefully stripped to the deep circumflex veins. The obturator nerve is exposed bluntly, and the hypogastric and obturator nodes are removed (Figs. 7, 8, 9, 10, 11).^{2,11} The obturator nerve is dissected and cleaned

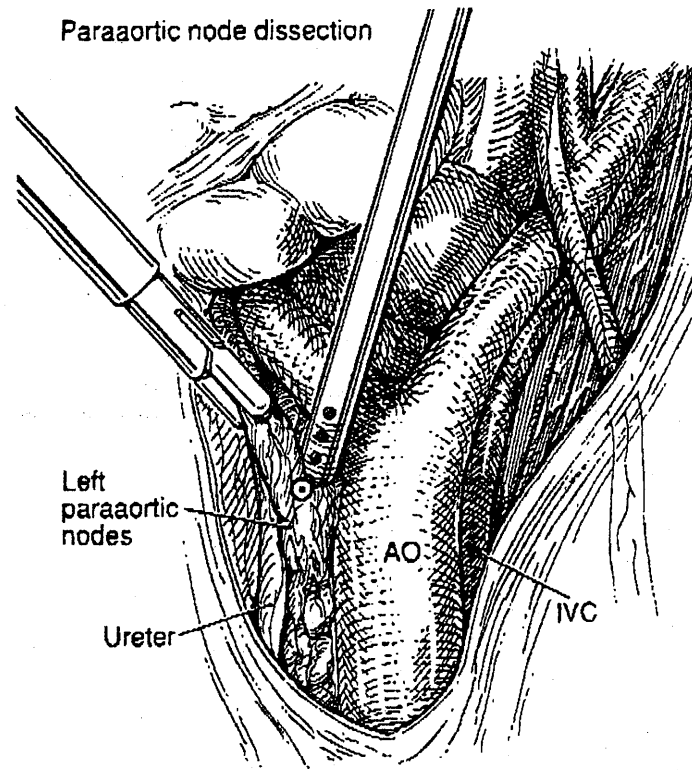


FIG. 4. Left paraortic node dissection. AO, aorta; IVC, inferior vena cava.

caudally until it leaves the pelvis. The nodal and fatty tissue between the obturator nerve and external iliac vein is identified and completely dissected (Figs. 7, 8, 9, 10, 11). The inferior aspect of the external iliac vein is separated using blunt dissection, CO₂ laser, and hydrodissection until the internal obturator muscle and pelvic bone can be seen. Venous anastomosis between the obturator and external iliac veins was visualized under magnification and saved from trauma. Bipolar electrocoagulation was used to facilitate removal when larger vessels were encountered. Lymph nodes posterior to the obturator nerve also are excised. The lymph nodes are removed en bloc, labeled with the endoloop, and placed laterally. They are removed after the vagina is opened and the hysterectomy is completed. Following the pelvic lymphadenectomy, the uterosacral ligaments and lateral parametria are coagulated with bipolar electrocoagulation and sequentially transected approximately 1.5 cm lateral to the cervix. The dissection is taken down to 2–5 cm below the cervix. The vagina is entered anteriorly and posteriorly using the CO₂ laser as follows. A sponge stick or right-angle retractor is placed into the vagina to push the vaginal walls anteriorly and posteriorly,¹² allowing the vagina to be incised by the CO₂ laser from above. The sponge in the vagina prevents the escape of pneumoperitoneum.

The radical hysterectomy is completed vaginally by incising the vagina 3–5 cm distal to the cervix. The residual cardinal ligaments are mobilized anteriorly and posteriorly, then divided from 1 to 5 cm lateral to the cervix and suture ligated. The left angle of the vagina is sutured to the left and right anterior uterosacral ligaments. The uterus is removed transvaginally, as are the right and left lymphatic bundles. The vaginal vault is closed, and a suprapubic catheter is placed.

Eleven patients had laparoscopic dissection of the uterus down to the cardinal ligament, separation and ligation of uterine vessels at their origin, and medial displacement of the ureters. The remainder of these 11 operations were completed vaginally using a Schauta procedure,¹³ including dissection of the vagina, uterosacral ligaments, and parametrium. After the vaginal portion was complete, laparoscopic evaluation was

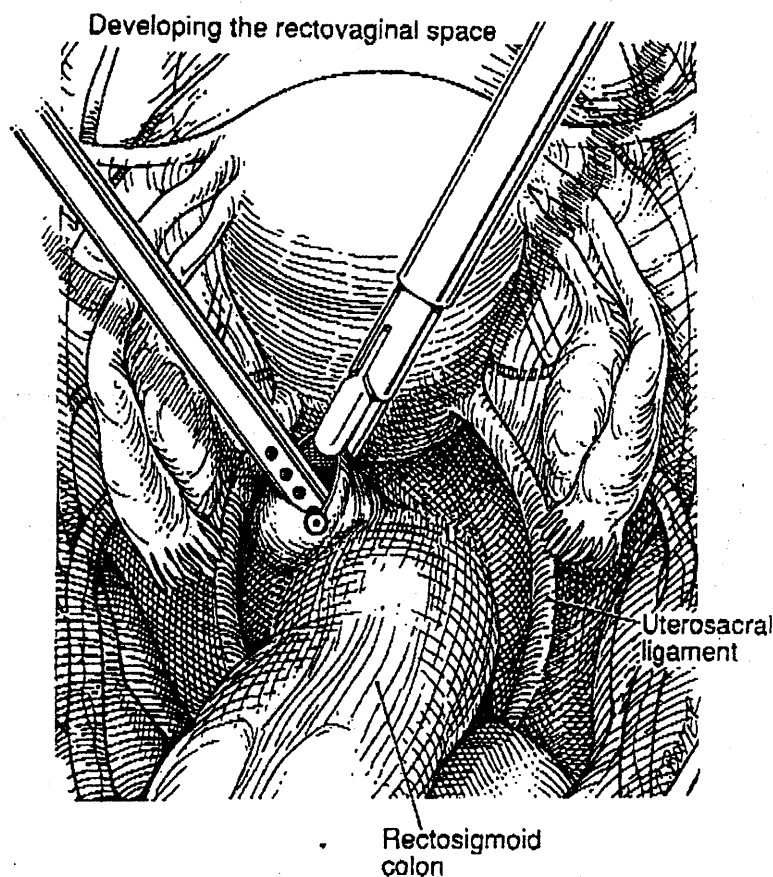


FIG. 5. Developing the rectovaginal space.

performed again. All the pedicles and both ureters were evaluated, and hemostasis was assured under low pneumoperitoneal pressure.¹⁴ No drain was inserted, and the peritoneum was left open to allow lymph drainage into the peritoneal cavity, preventing a lymphocyst. All 18 women underwent laparoscopic pelvic lymphadenectomy.³ The 1 with stage IIA, 7 with stage IB disease, and 3 with stage Ia2 disease with lymphatic channel involvement underwent paraaortic node dissection in addition to pelvic node dissection.³ All patients undergoing laparoscopic radical hysterectomy had suprapubic catheters inserted. All patients undergoing laparoscopically assisted vaginal radical hysterectomy had a Foley catheter placed. The catheters were removed in 2 weeks, and the bladder training was routine.

RESULTS

The average operative time for laparoscopic radical hysterectomy, which included paraaortic and pelvic node dissection in all cases, was 315 min (range 240–480 min). The laparoscopically assisted vaginal radical hysterectomy operations averaged 163 min (range 125–214 min). The average specimen weight was 135 g (range 120–155 g). Blood loss ranged from 30 ml to 250 ml. On average, 3 cm of vaginal tissue and 2 cm of paracervical and paravaginal tissue were removed on each side of the specimen. The number of paraaortic nodes removed ranged from 3 to 9, with an average of 6. The number of pelvic nodes ranged from 11 to 33, with an average of 22. The postoperative hospital stay averaged 2.1 days (range 1–6). There were no major intraoperative or postoperative complications.

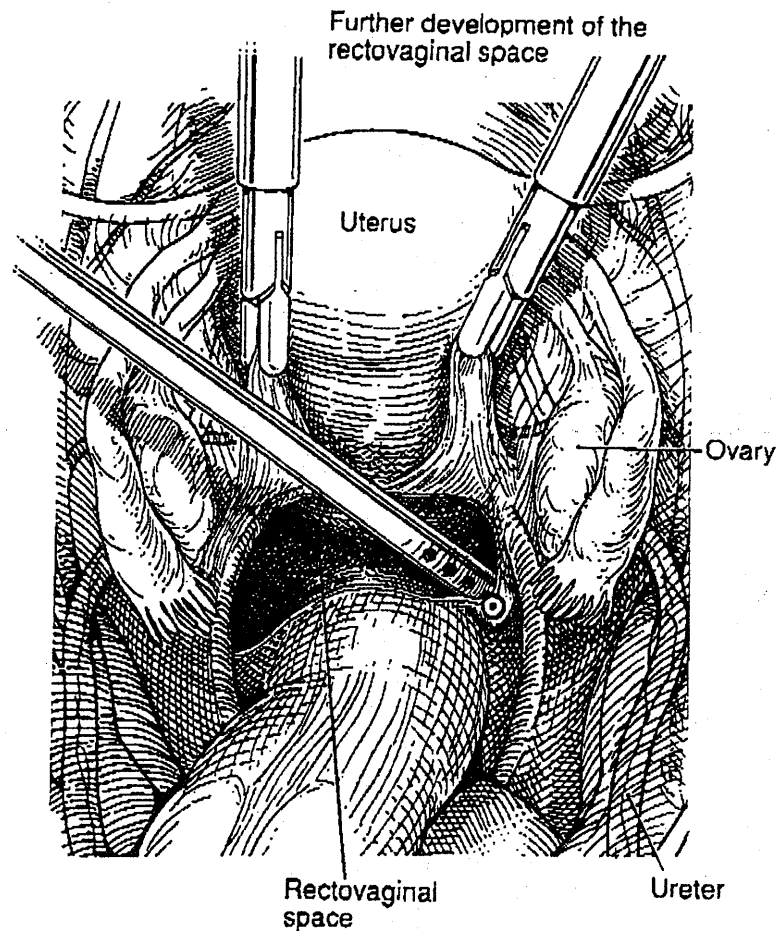


FIG. 6. Further development of the rectovaginal space.

Minor postoperative complications included one incidence of bleeding from the umbilical incision on the first postoperative day. This was easily controlled by one suture applied using a local anesthetic. One patient remained hospitalized for 6 days due to febrile morbidity resulting from a urinary tract infection, which responded to medical therapy. The follow-up for all patients has included clinical examination and vaginal smear. There have been no signs of recurrence, and a longer follow-up is underway. All patients undergoing LRH had a suprapubic catheter that was removed in 2-3 weeks, and all had expected neurogenic bladder dysfunctions that have gradually resolved.

DISCUSSION

Operative mortality from radical hysterectomies has decreased from 8 in 473 cases reported in 1955 to 0 in some more recent studies.¹⁵ Morbidity, as reflected by urinary fistula incidence, has decreased with radical hysterectomies from more than 20% to less than 1%.¹⁵ The reasons for improved results vary, but the goal of gynecologic oncologists has been to reduce surgical morbidity without compromising end results, by any

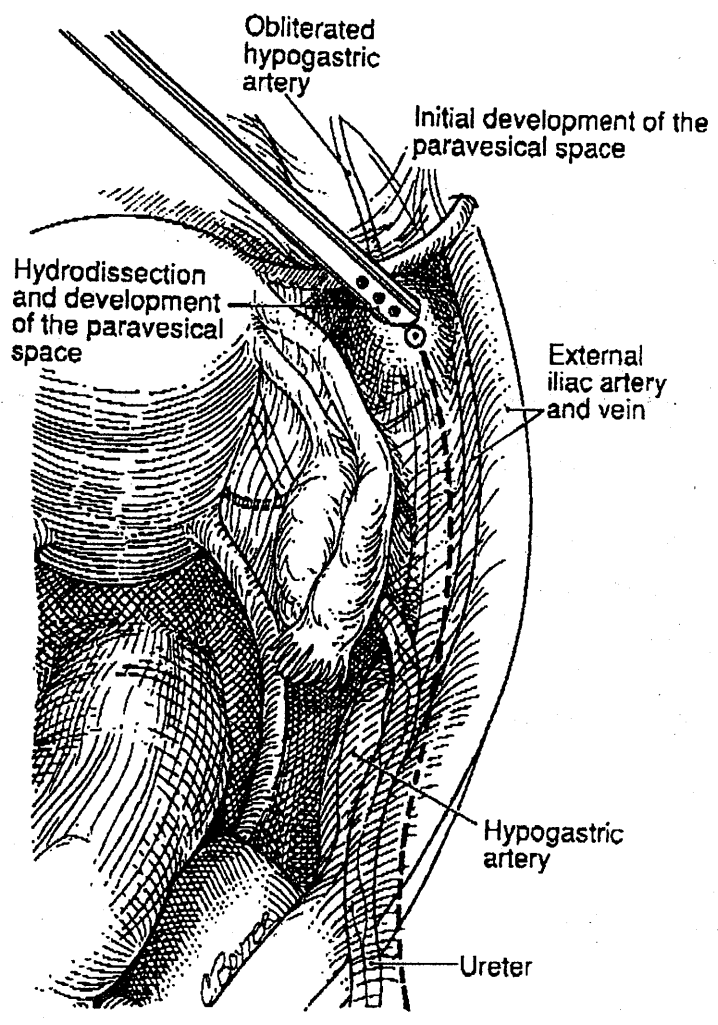


FIG. 7. Paravesical space development.

available technical improvements. We realize that there is a great deal of controversy surrounding the necessity of paraaortic node dissection for stage IB patients, not to mention patients with stage IA2, squamous cell carcinoma of the cervix. However, it is not the purpose of this article to address this issue.

For operative laparoscopy to be effective in oncologic surgery, two fundamental principles must not be violated. First, the extent of the surgery must not be compromised by the new technology. That is, the exploratory information and the specimen removed must be as adequate as could be achieved in the optimal conventional surgery. Second, morbidity from a new procedure must be no greater than that from conventional techniques. We have noted a decrease in morbidity when using these methods.

With these principles in mind, we have performed a series of radical hysterectomies with pelvic and, in some cases, paraaortic lymphadenectomy, using operative videolaparoscopy techniques. Details of pelvic anatomy are more clearly visible than with conventional surgery. By operative laparoscopy, the number of lymph nodes removed, the size of parametrial tissue margins, and the width of the vaginal cuff all can be equal to those achieved with a conventional operation. We would thereby presume that end results of laparoscopic

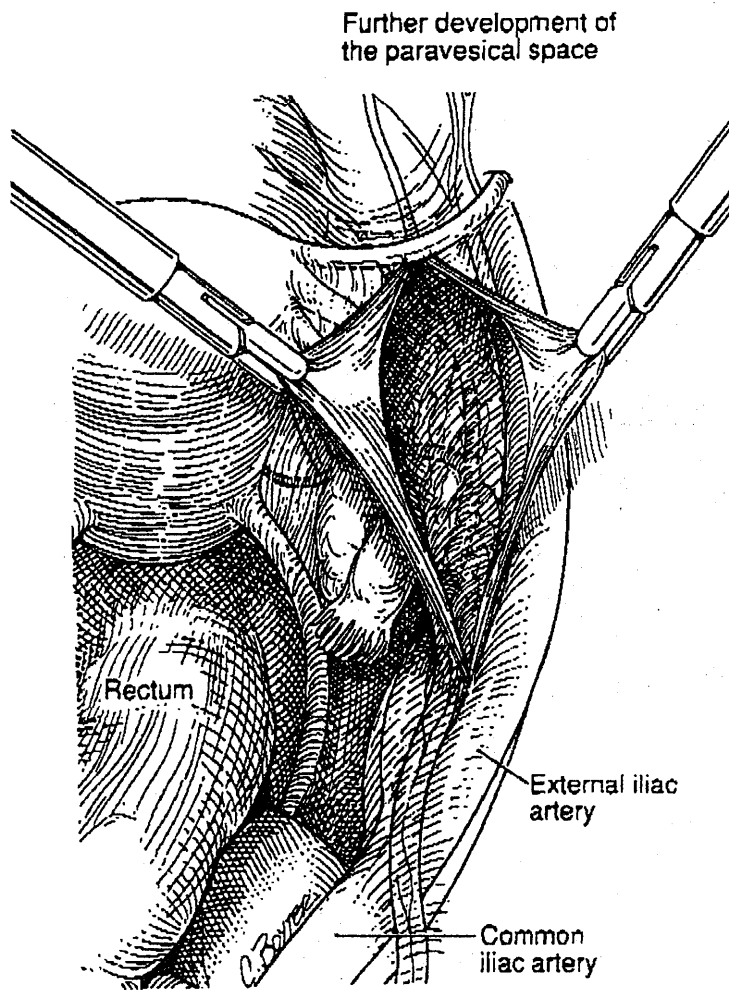


FIG. 8. Paravesical space development.

cancer surgery would be comparable to those yielded by current surgical techniques. In addition, the possibility of de novo adhesion formation with this technique is lower than with laparotomy.^{16,17}

The laparoscopic radical hysterectomy was identical to a laparotomy except that bipolar electrocoagulation and CO₂ laser replaced sutures and scissors. We firmly believe that bipolar electrocoagulation is an adequate and safe method for coagulating and ligating large blood vessels, as long as the operator is familiar with the instrument's function.³⁻⁵ No unusual short-term or long-term ill effects are evident with either approach. Although it has been stated that the only advantages of laparoscopy over laparotomy for radical hysterectomy are a decrease in hospital stay, recovery, and pain,⁴ we believe there are several other advantages, including a decrease in morbidity when using a videolaparoscopic approach.¹ By using a videolaparoscopic technique, we can identify and dissect tissue planes better than during laparotomy. Pressure from the pneumoperitoneum usually prevents small vessel bleeding and oozing. The CO₂ laser seals small blood vessels while cutting. Operative videolaparoscopy allows the patient's abdomen to become the operating theater. The excellent light sources and magnification along with a clean operating field help to provide better exposure in the pelvic and

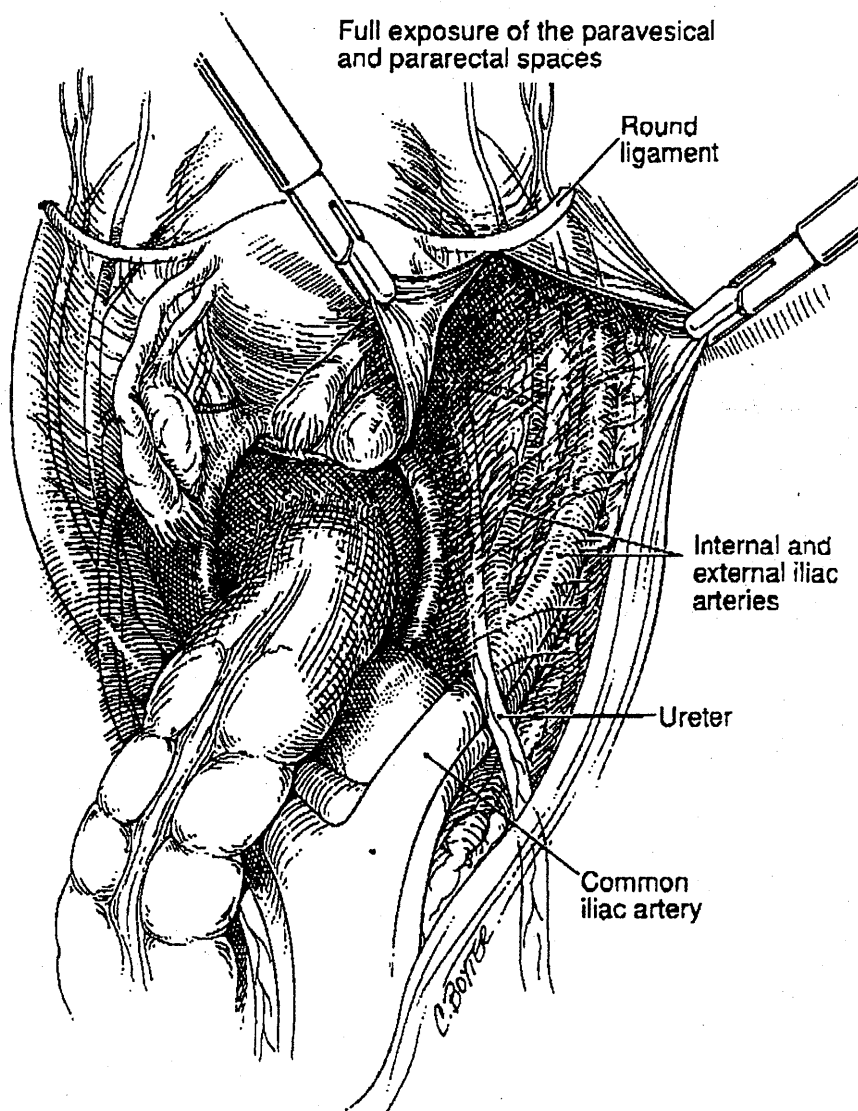


FIG. 9. Full exposure of paravesical and pararectal spaces.

abdominal cavities. The end result is a microsurgical approach to even the most radical procedures. Thus, we believe the rate of complications should be lower.

These procedures have been performed safely in this initial series with no apparent compromise in specimen adequacy. Morbidity in these cases has been less than would have been expected from a standard radical hysterectomy. In our experience, the only drawback to laparoscopy is the increased operative time, which can be quite lengthy. However, as we have observed in performing other laparoscopic procedures, the duration of the operation decreases as experience is gained. Even if the operative time is reasonably longer by laparoscopy than laparotomy, as long as the tissue margins are not compromised, the decrease in complications and morbidity supports the laparoscopic approach as preferable. In this series, the incidence of complications is

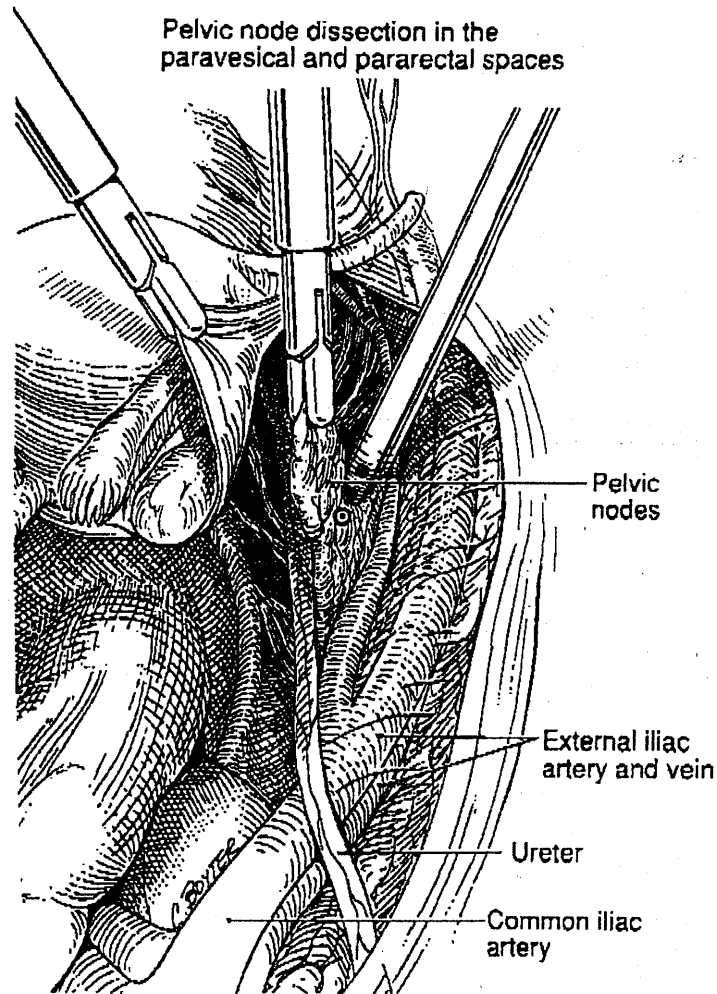


FIG. 10. Pelvic node dissection.

significantly lower than that reported at laparotomy.¹⁸ A thorough knowledge of the disease and pelvic anatomy and expertise in operative laparoscopy are required to perform such procedures and cannot be overemphasized, and an entire surgical team is necessary. Although the skills to perform these procedures take time to acquire, these encouraging preliminary results indicate that operative laparoscopy may increasingly benefit patients who require surgery for malignancy. Because microsurgical principles of magnification, better hemostasis, and delicate dissection are used, complication rates in experienced hands are lower than those associated with laparotomy.

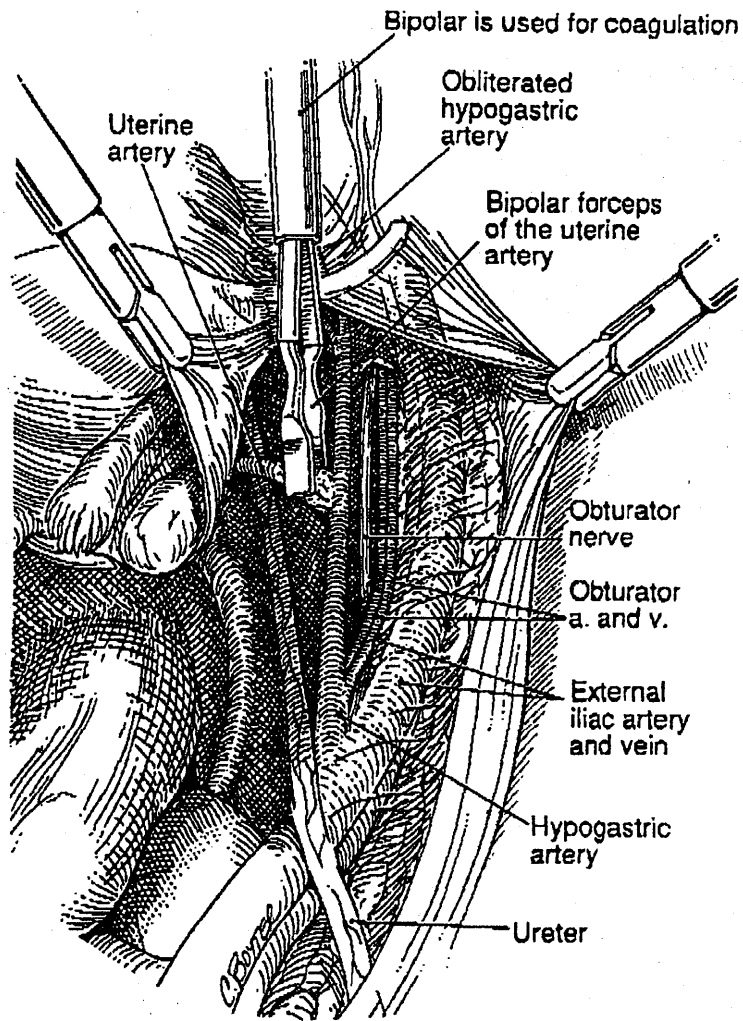
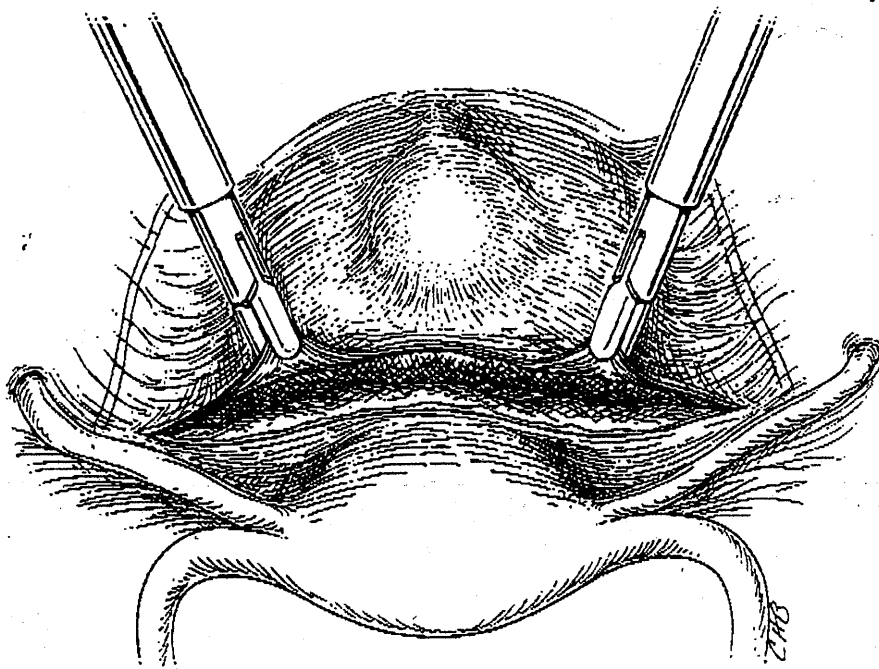
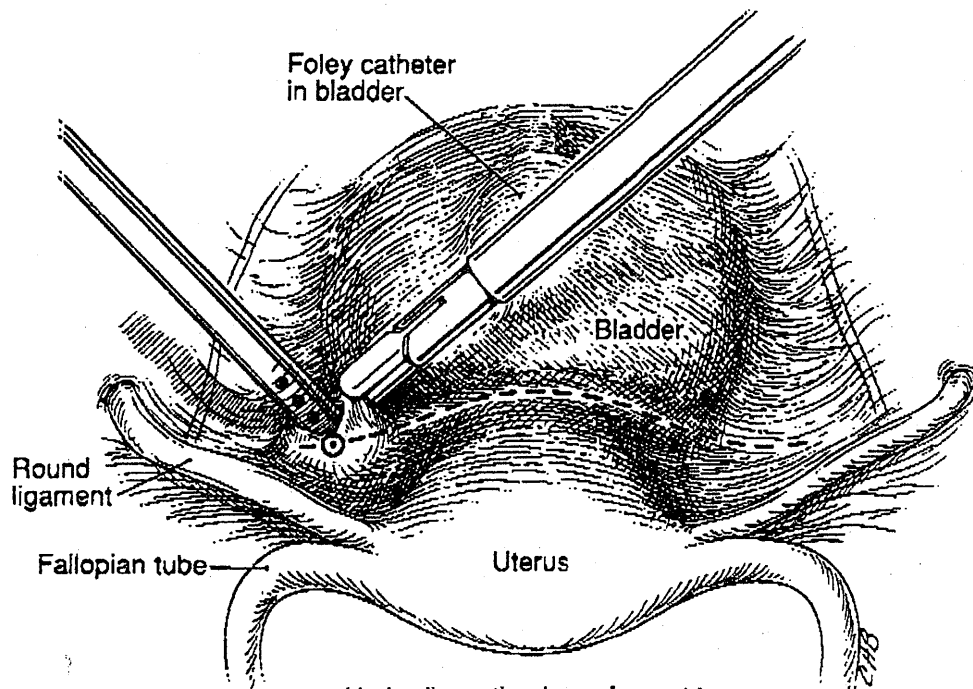


FIG. 11. Desiccation of uterine artery at its origin. a. artery; v. vein.



Incision over the bladder flap

FIG. 12. Vesicovaginal space is being developed.



Hydrodissection is performed for developing the vesicovaginal space

FIG. 13. Further development of vesicovaginal space.

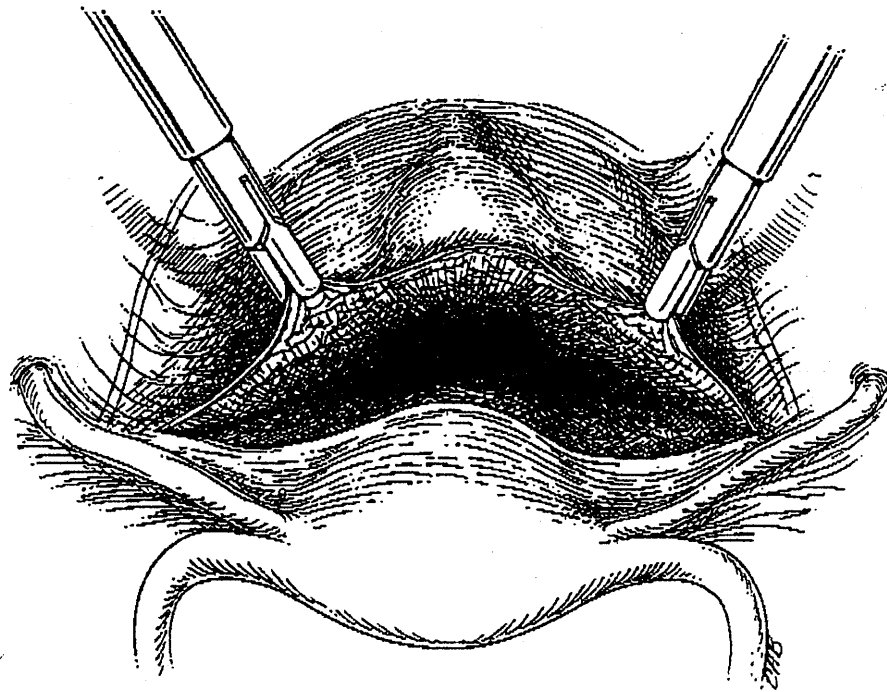


FIG. 14. Further development of vesicovaginal space.

REFERENCES

1. Nezhat C, Nezhat F, Nezhat C. Operative laparoscopy (minimally invasive surgery): State of the art. *J Gynecol Surg* 1992;8:111.
2. d'Argent D, Salvat J. *Envahissement ganglionnaire pelvien. Place de la pelviscopie retroperitoneale*. Paris: Medsi/McGraw-Hill, 1989.
3. Nezhat C, Burrell MO, Nezhat FR, Benigno BB, Welander CE. Laparoscopic radical hysterectomy with para-aortic and pelvic node dissection. *Am J Obstet Gynecol* 1992;166:864.
4. Canis M, Mage G, Wattiez A, Pouly JL, Chapron C, Bruhat MA. Vaginally assisted laparoscopic radical hysterectomy. *J Gynecol Surg* 1992;8:103.
5. Nezhat F, Nezhat C. Setup for operative laparoscopy and vidcolaserotomy. *Contemp Obstet Gynecol* 1992;36:50.
6. Nezhat C, Pennington E, Nezhat F, Silfen SL. Laparoscopically assisted anterior rectal wall resection and reanastomosis for deeply infiltrating endometriosis. *Surg Laparosc Endosc* 1991;1:106.
7. Nezhat C, Nezhat F. Safe laser excision or vaporization of peritoneal endometriosis. *Fertil Steril* 1989;52:149.
8. Nezhat C, Nezhat F, Silfen SL. Laparoscopic hysterectomy and bilateral salpingo-oophorectomy using multifire GIA surgical stapler. *J Gynecol Surg* 1990;6:287.
9. Nezhat C, Nezhat F, Gordon S, Wilkins E. Laparoscopic versus abdominal hysterectomy. *J Reprod Med* 1992;37:247.
10. American College of Obstetricians and Gynecologists. *Gynecologic Oncology Group surgical procedures manual*. Washington: ACOG, 1999:48.
11. Querleu D, Leblanc E, Castelain B. Laparoscopic pelvic lymphadenectomy in staging of early carcinoma of the cervix. *Am J Obstet Gynecol* 1991;164:579.
12. Davis GD, Hruby PH. Transabdominal laser colpotomy. *J Reprod Med* 1989;34:438.

120 Nezhat et al.

Journal of Gynecologic Surgery

13. Schauta F. Die Operation des Gebärmutterkrebes mittels des Schuchardt'schen Paravaginalschnittes. *Montasschr Z Geburtshif Gynakol* 1902;15:133.
14. Nezhat C, Nezhat F, Winer W. Salpingectomy via laparoscopy: A new surgical approach. *J Laparosc Surg* 1991;1:91.
15. Knapp RC, Berkowitz RS, eds. *Gynecologic oncology*. New York: Macmillan, 1986:245.
16. Nezhat CR, Nezhat FR, Metzger DA, Luciano AA. Adhesion reformation after reproductive surgery by videolascroscopy. *Fertil Steril* 1990;53:1008.
17. Diamond MP, et al. Postoperative adhesion development after operative laparoscopy: Evaluation at early second-look procedures. *Fertil Steril* 1991;55:700.
18. Mattingly RF, Thompson JD, eds. *Te Linde's operative gynecology*. 6th ed. Philadelphia: JB Lippincott Co. 1985:814.

Address reprint requests to:

Camran Nezhat, M.D.
5555 Peachtree Dunwoody Road, N.E.
Suite 276
Atlanta, GA 30342