

April 1997

Conservative Laparoscopic Surgical Approaches to Treat Endometriosis

Farr Nezhat, MD, Camran Nezhat, MD, and Ceana Nezhat, MD

We describe the techniques for conservative laparoscopic treatment of endometriosis. The treatment of peritoneal and ovarian implants, as well as endometriosis of the genitourinary tract, intestinal tract, cul-de-sac, and diaphragm is also described in detail. In the hands of an experienced laparoscopist, the most extensive pelvic endometriosis can be treated adequately by using conservative laparoscopic techniques.
Copyright © 1997 by W.B. Saunders Company

The goals of conservational surgery for endometriosis are to remove or destroy all implants, resect all adhesions, and restore the anatomic relationships. Every effort should be made to prevent recurrence of the endometriosis and reformation or de novo formation of adhesions.

The procedure can be performed by using a variety of cutting instruments including mechanical (scissors) and electrical and laser energy. We believe that the CO₂ laser, especially the Ultrapulse 5000L (Coherent, Palo Alto, CA), offers certain advantages. The CO₂ laser beam does not obstruct the surgeon's view, and this laser will not penetrate water. This last property is particularly valuable if the CO₂ laser is used in conjunction with hydrodissection.¹ The fluid develops the tissue planes, and can be used as a backstop to protect sensitive tissues.

In many cases, it will first be necessary to perform a preliminary adhesiolysis. In severe cases of endometriosis, every effort should be made to remove (rather than simply divide) adhesions and all fibrous tissue. They are often found to contain foci of glands and stroma. The adhesions associated with endometriosis frequently involve vital structures. Hydrodissection and the use of the ultra pulse CO₂ laser can greatly facilitate their dissection.

Peritoneal Implants

Peritoneal implants can be excised or ablated in situ. They must be completely eradicated. Superficial lesions up to 5 mm in diameter can be excised, electrodesiccated, or vaporized with the laser. It is preferable to excise larger and infiltrating lesions. Care is taken not to damage any surrounding structures. Any bleeding points are electrodesiccated with micro-

polar forceps. Cutting in close proximity to vital structures should be performed using scissors or the CO₂ laser.

Ablation of small lesions can be effected using bipolar current if the disease is superficial. Unipolar current or fiber laser is required if the lesion penetrates to any depth. The CO₂ laser, set at 3,500 to 5,500 watts/cm², can be used in a similar fashion. Larger lesions can be vaporized or excised by using a combination of hydrodissection and the CO₂ laser. The technique for hydrodissection is shown in Figure 1. The laser is fired in a continuous mode and the lesion is ablated from the surface to its base. The appearance of normal retroperitoneal fat signals the end of the ablation. It will be necessary to remove the laser plume during this process. The technique used for excision is shown in Figure 2.

It is important to use copious irrigation to remove any carbon particles from the site of ablation. If carbon is left it can be mistaken for recurrent endometriosis at the time of any subsequent laparoscopy.

Ovarian Implants

Endometriosis of the ovary can exist as small superficial lesions or endometriomas of less than 2 cm in diameter, cysts of 2 to 5 cm in diameter, and endometriomas that are greater than 5 cm. Like peritoneal lesions, endometrial implants on the ovary can be coagulated, excised, or vaporized. The goal should be to achieve complete treatment while causing the least amount of trauma to ovarian function. Hemorrhagic ovarian cysts clinically resembling endometriomas can be classified into two major types.¹

Type I endometriomas, or pure endometriomas, are small (1 to 2 cm), contain dark fluid, develop from surface endometrial implants, and are difficult to remove surgically (Fig 3). Histologic analysis reveals endometrial tissue in all of them. Although small type I endometriomas are difficult to remove intact because of associated fibrosis and adhesions, they can be biopsied, drained, and vaporized using laser or electro-surgery, or removed in pieces. The larger type I lesions (2 to 3 cm) must be removed completely (Fig 4).

Type II endometriomas, or secondary endometriomas, are caused when follicular or luteal ovarian cysts have been involved or invaded by cortical endometrial implants or by primary endometrioma. Type II endometriomas are classified into three subgroups based on the relationship of cortical endometriosis with the cyst wall.

Type IIA endometriomas are large, the cyst wall is separated easily from the ovarian tissue, and if endometrial implants are found, they do not penetrate the cyst wall (Fig 5). These hemorrhagic cysts are either follicular or luteal in origin. The surgical technique for this type of lesion includes lysis of periovarian adhesions, evaluation of the ovarian cortex, and

From the Stanford Endoscopy Center for Training and Technology; the Departments of Gynecology/Obstetrics and Surgery, Stanford University School of Medicine, Stanford, CA; the Nezhat Institute for Special Pelvic Surgery, Palo Alto, CA; and the Center for Special Pelvic Surgery, Atlanta, GA.

Address reprint requests to Farr Nezhat, MD, 5555 Peachtree Dunwoody Rd, Suite 276, Atlanta, GA 30342.

Copyright © 1997 by W.B. Saunders Company
1085-5610/97/0202-0003\$5.00/0

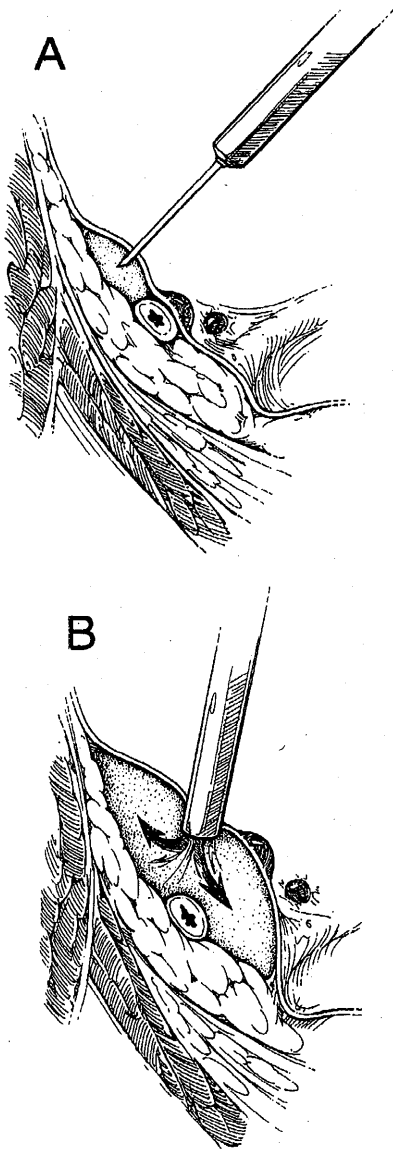


Fig 1. Hydrodissection is performed either by injecting lactated Ringer's beneath the peritoneum with a laparoscopic needle or making a small opening in the peritoneum with scissors or the laser then introducing the suction irrigation cannula and injecting fluid, thus partly dissecting the peritoneum and forming a backstop for the laser. (Reprinted with permission from McGraw-Hill companies [Nezhat C et al, *Operative Gynecologic Laparoscopy: Principles and Techniques*, 1995].¹⁹)

aspiration of the cyst. Superficial implants are vaporized or excised. The cyst is opened and its wall is examined. If it has a yellowish appearance and removal is easy, biopsy is taken for frozen section. Postoperatively, either danazol 800 mg daily, oral contraception pills or a gonadotropin-releasing hormone (GnRH) analogue is used for 6 to 8 weeks.

Types IIB and IIC are endometriomas with features of functional cysts involved deeply with surface endometriosis, with histologic findings of endometriosis in the cyst wall. They usually are large and associated with periovarian adhesions attaching them to the pelvic sidewall and back of the uterus, and tend to rupture during separation. In type IIB, the lining is separated easily from the ovarian capsule and stroma except adjacent to the areas of endometriosis (Fig 6). In type IIC, surface endometrial implants penetrate more deeply into the

cyst wall, making excision more difficult (Fig 7). The degree of endometrial invasion of the cyst wall forms the basis for differentiating between these two subtypes and is characterized by the progressive difficulty in removing the cyst wall. Surgical treatment of types IIB and IIC includes mobilizing the ovary and removing the contents of the cyst and irrigating the cavity using the suction-irrigator probe. Removal of endometrioma types IIB and IIC is shown in Figures 8 and 9, respectively.

The redundant ovarian tissue is approximated with low-power laser or electrosurgery to avoid adhesions. Low-power, continuous laser or bipolar coagulation applied to the inside wall of the redundant ovarian capsule causes it to invert, but excessive coagulation of the adjacent ovarian stroma must be avoided. Sutures, if needed, are placed inside the capsule and

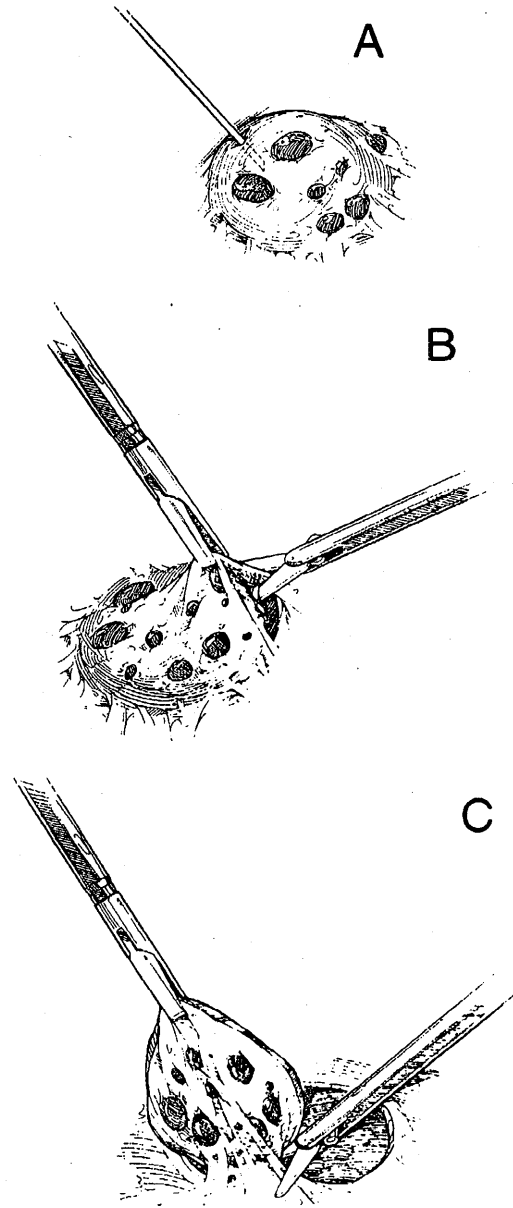


Fig 2. Excisional biopsy of peritoneal implants. (A) Injection of fluid under peritoneum. (B) Elevation of lesion and surrounding peritoneum with initial incision using scissors or the laser. (C) The incised peritoneum on the side of the lesion is elevated with grasping forceps and the lesion is excised using sharp or blunt dissection. (Reprinted with permission.¹⁹)

Fig 3. Type I endometriomas are small (1 to 2 cm), contain dark fluid, develop from surface endometriosis, and are difficult to remove surgically. (Reprinted with permission.²⁰)

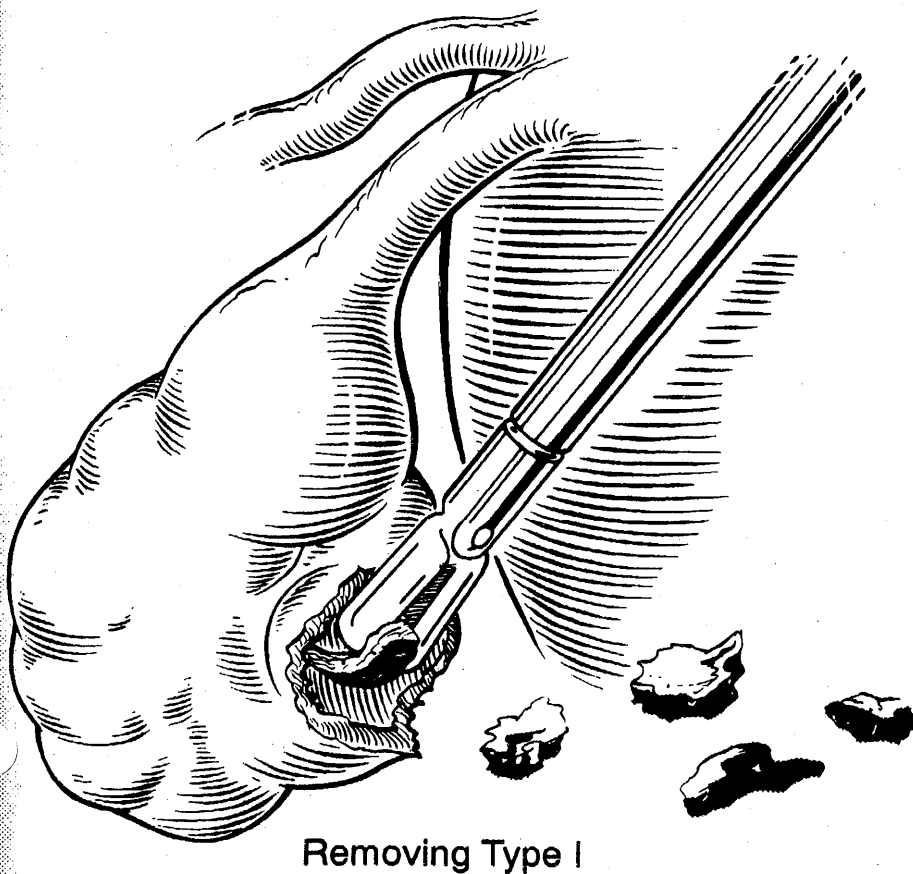
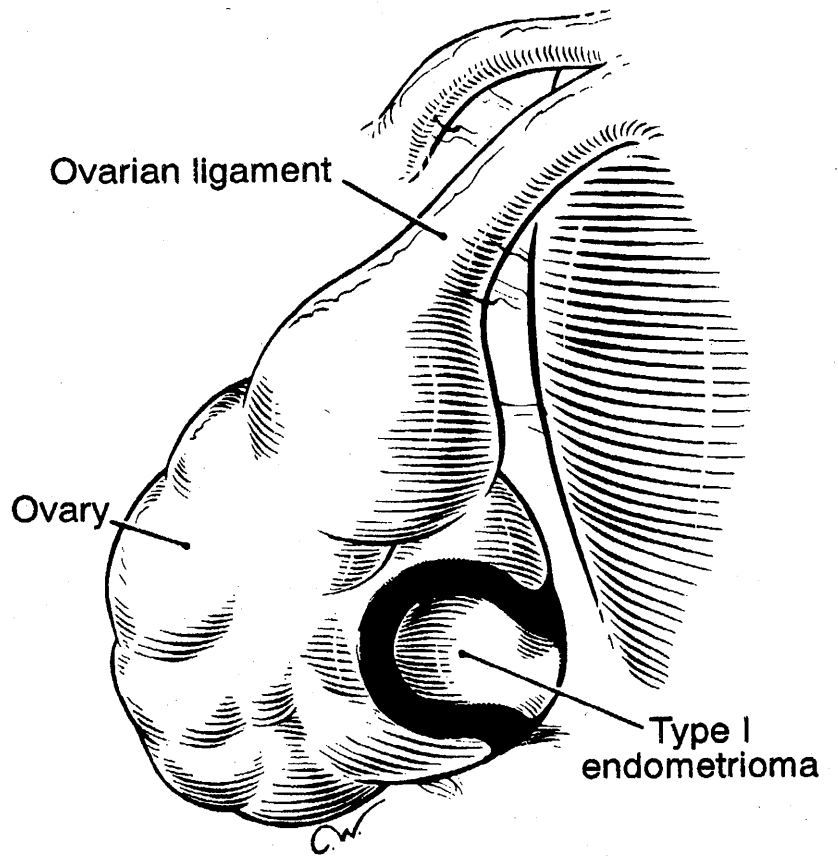


Fig 4. A type I endometrioma is difficult to remove and is removed in pieces. (Reprinted with permission.²⁰)

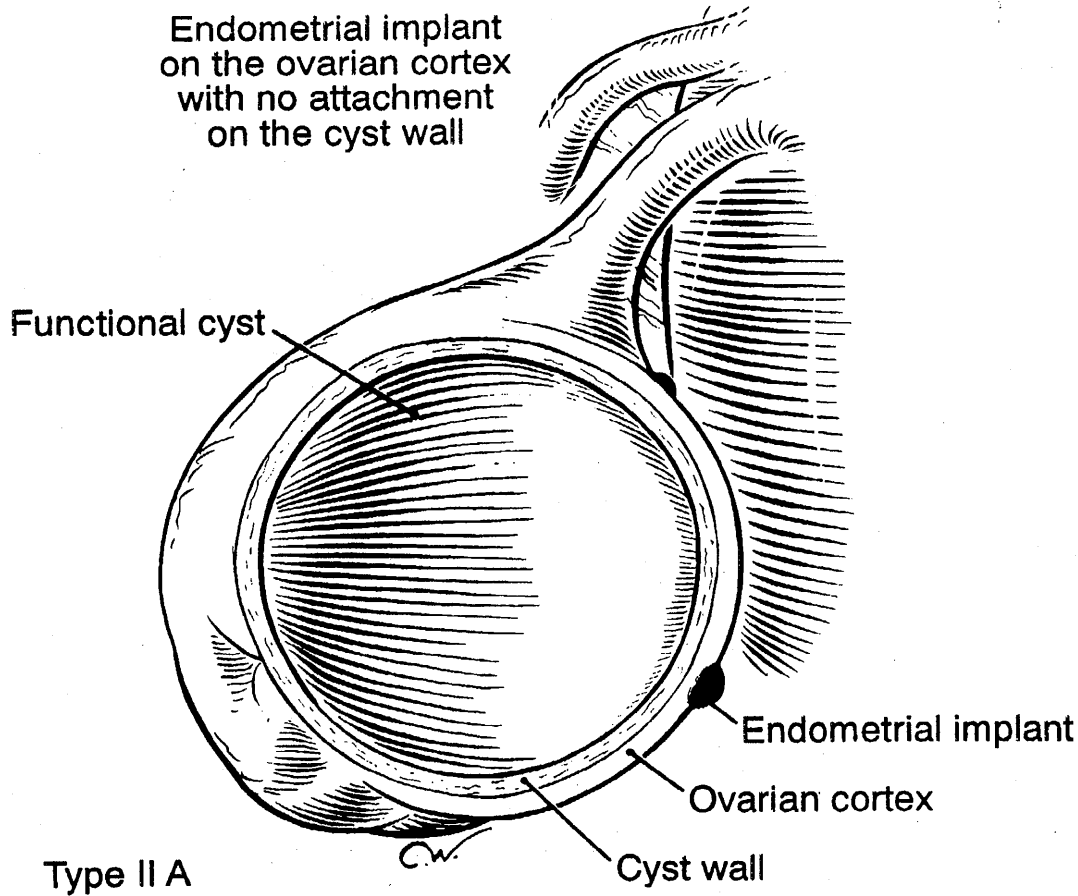


Fig 5. Type IIA endometriomas are large, and the cyst wall is separated easily from the ovarian tissue. Endometrial implants do not penetrate the cyst wall. (Reprinted with permission.²⁰)

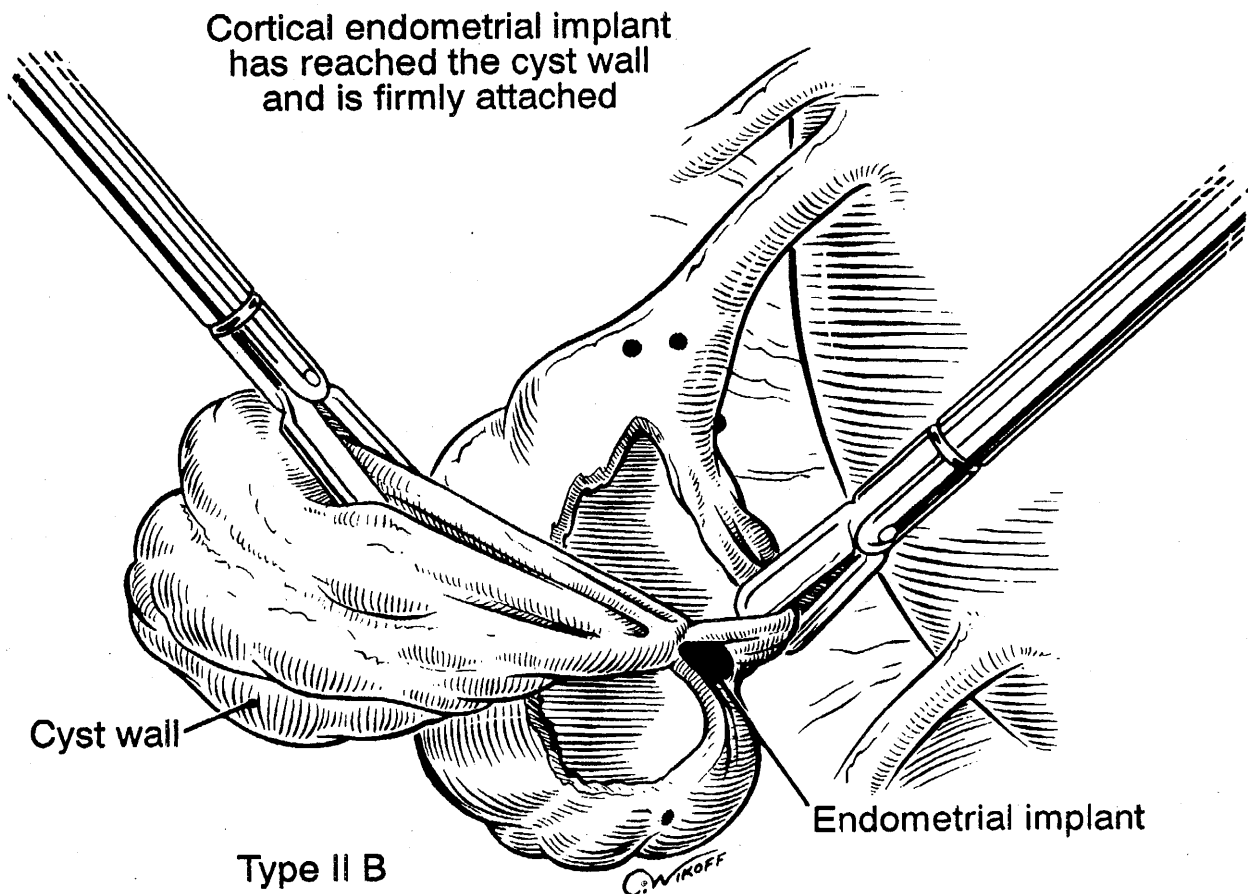


Fig 6. Type IIB endometrioma. Lining is separated easily from the ovarian capsule and stroma, except adjacent to the areas of endometriosis. (Reprinted with permission.²⁰)

Endometrial implant has reached the cyst and is spreading

Cyst is attached to the pelvic side wall with dense adhesions

Type II C

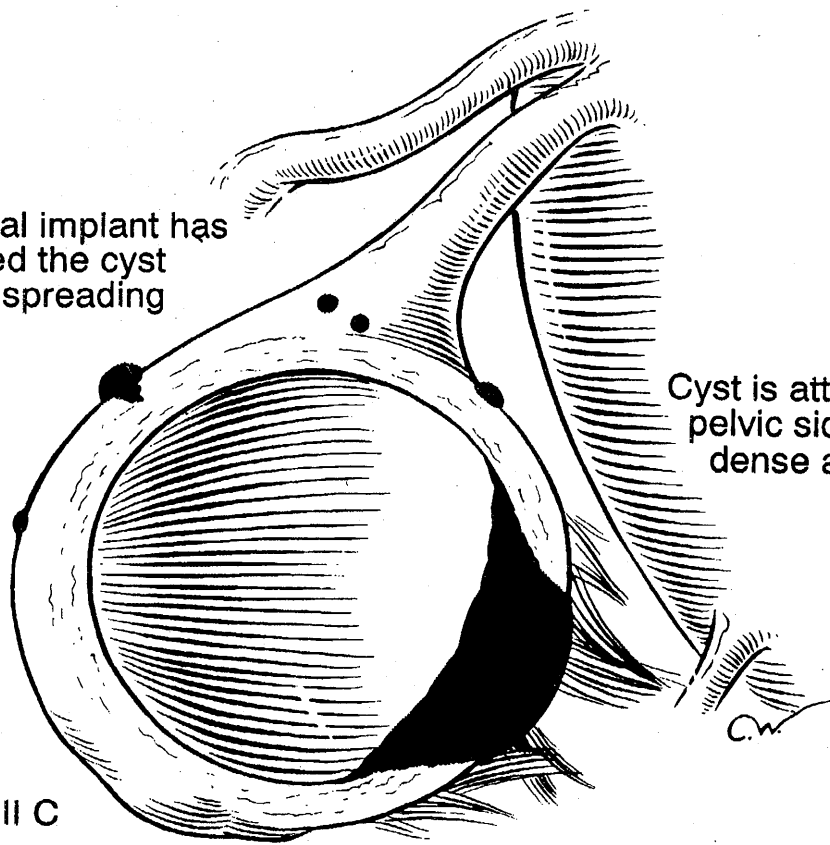
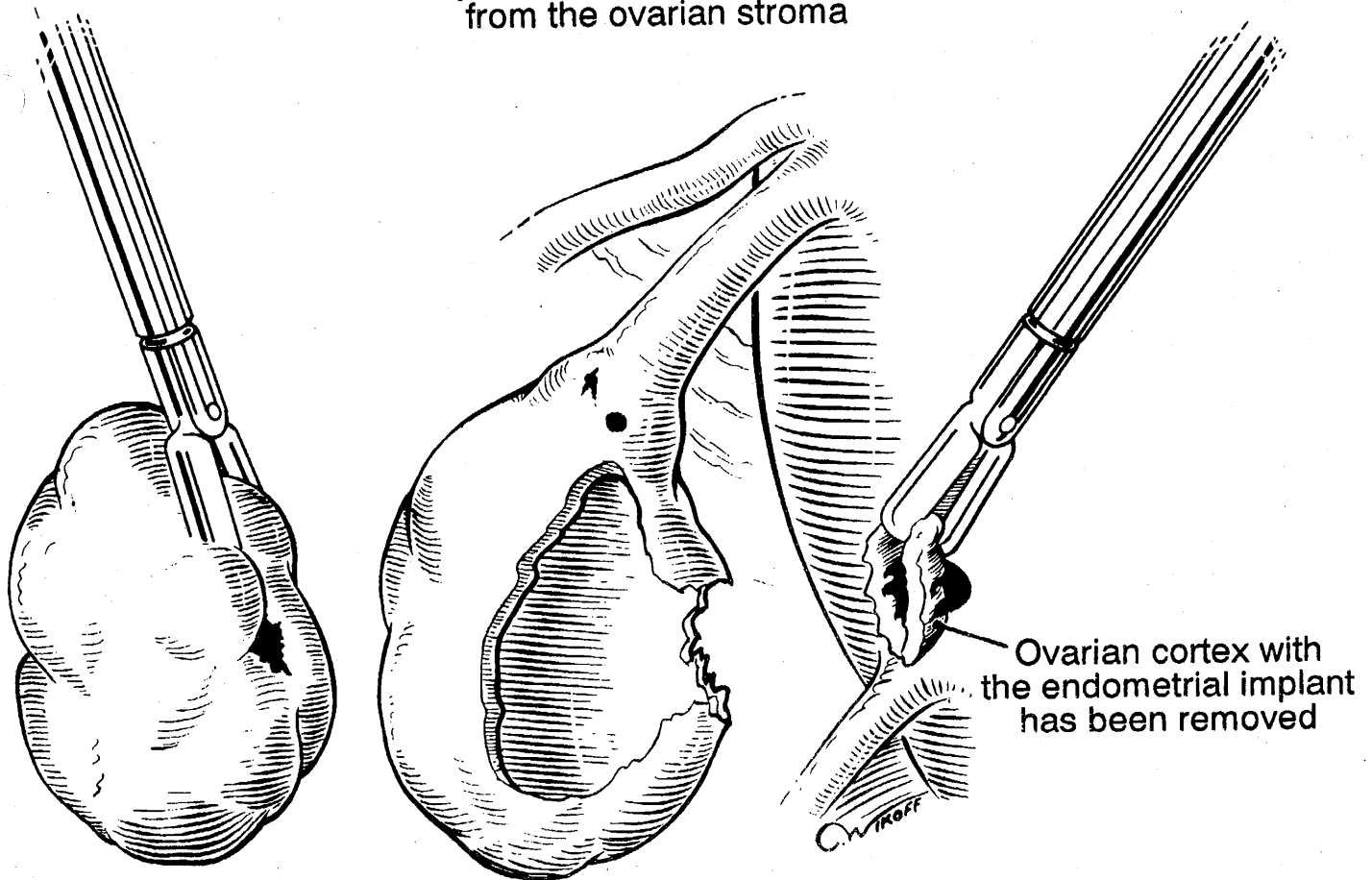


Fig 7. Type IIC endometrioma. Surface endometrial implants penetrate into the cyst wall. (Reprinted with permission.²⁰)

Cyst wall has been removed from the ovarian stroma



Removing Type II B

Fig 8. Excision of type IIB endometrioma. An opening is made and the suction-irrigator probe is introduced inside the cystic cavity. By alternating suction and irrigation, the contents are removed. The inside of the cyst is evaluated and the portion of ovarian cortex involved with endometriosis is removed. Using the grasping forceps and the suction-irrigator probe, the cyst wall is grasped and separated from the ovarian stroma by traction and countertraction. Hydrodissection facilitates complete removal. (Reprinted with permission.²⁰)

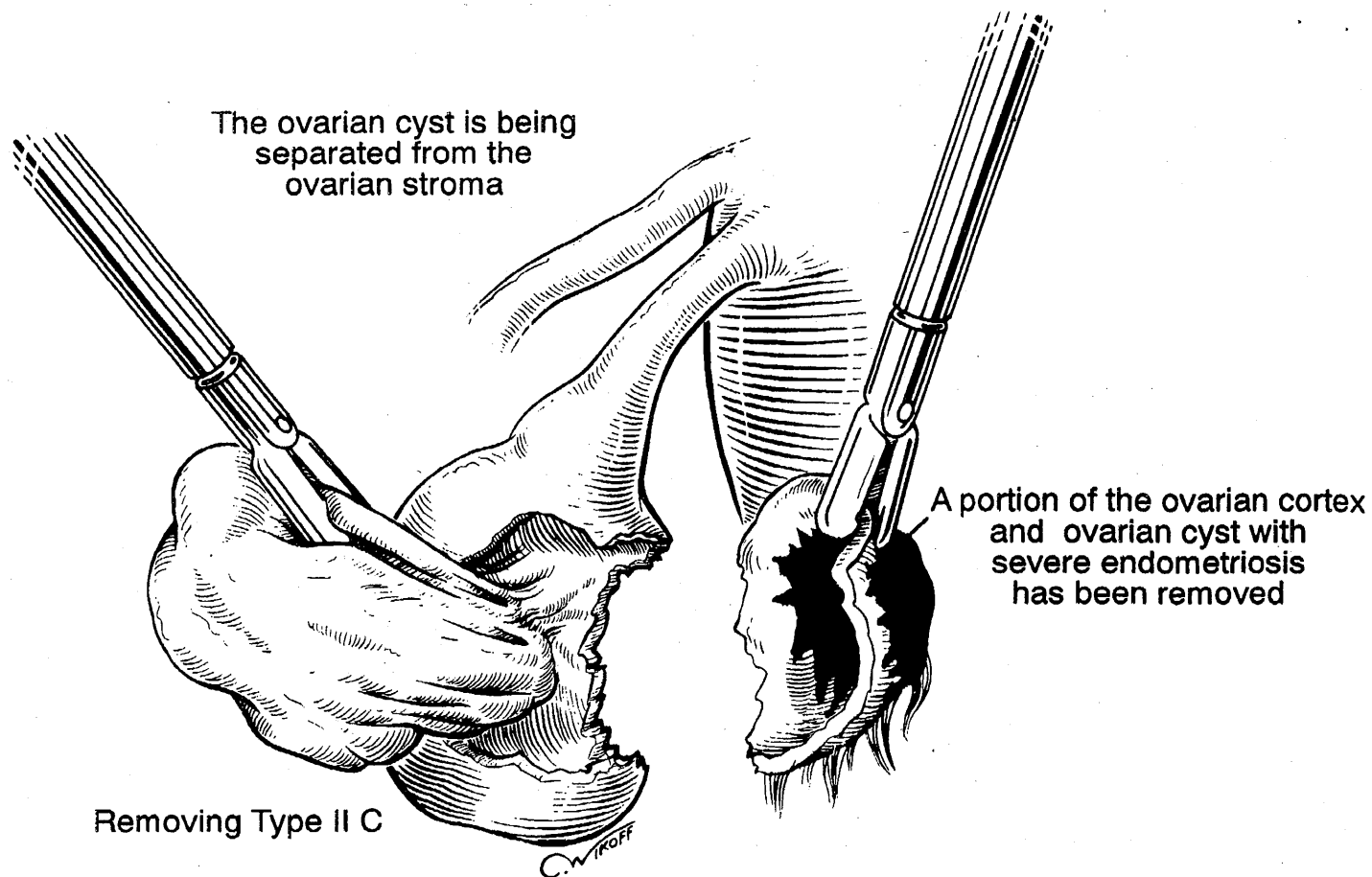


Fig 9. Excision of type IIC endometrioma. It is difficult to develop a plane between the cyst wall and the ovarian capsule so that the portion of the ovary attached to the cyst wall is removed until an area is found to develop a plane. The remainder of the procedure is similar to that used for IIB endometrioma. The cyst wall is grasped and stripped from the ovarian stroma. (Reprinted with permission.²⁰)




Fig 10. Partial right ureteral obstruction caused by endometriosis.

Fig 11. Histology of ureteral endometriosis (L, lumen; E, endometriosis).

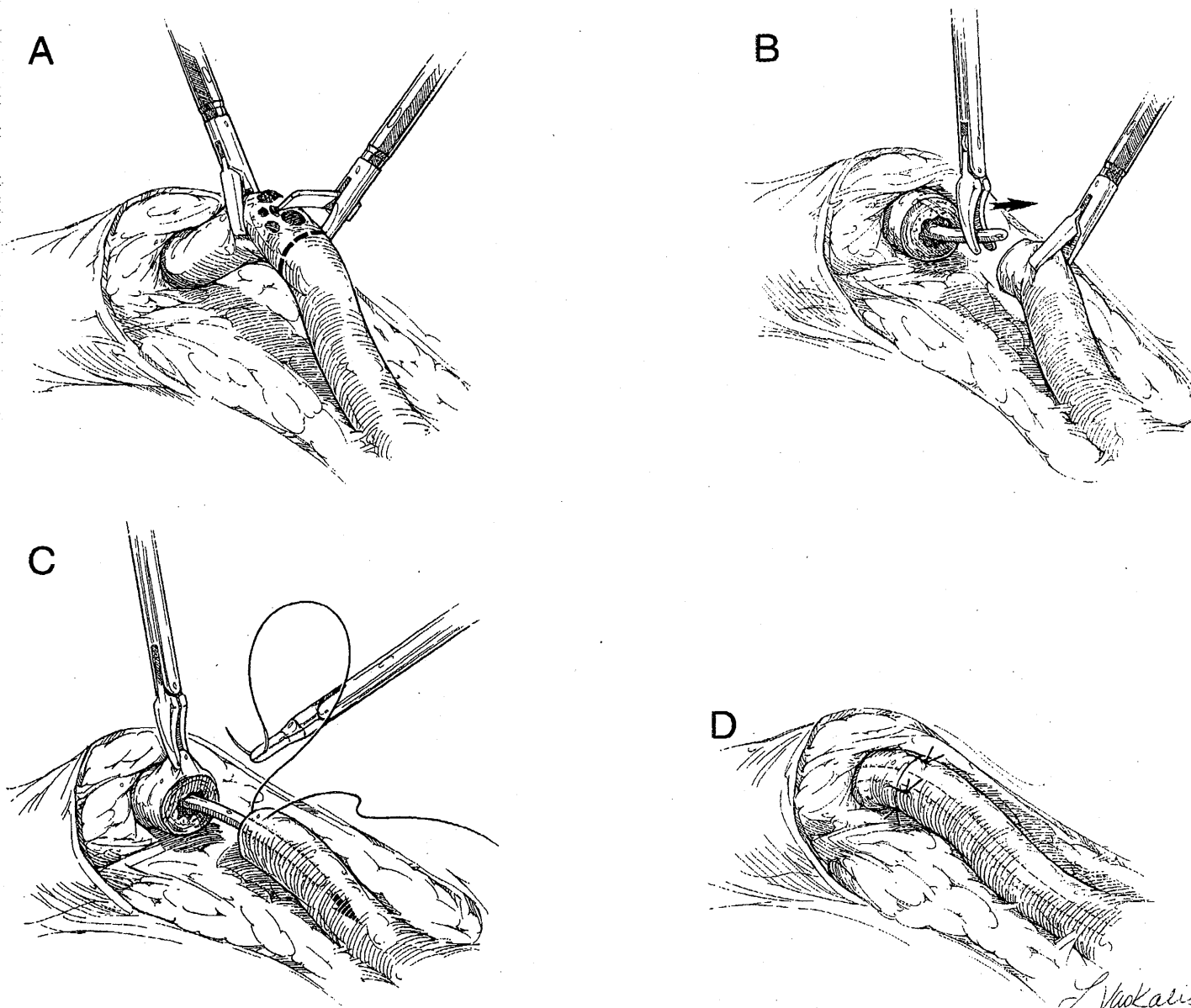
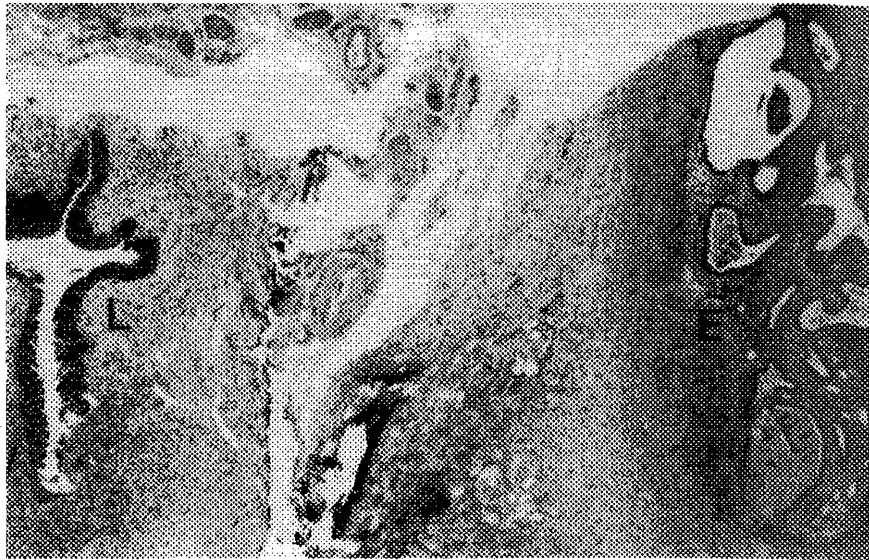
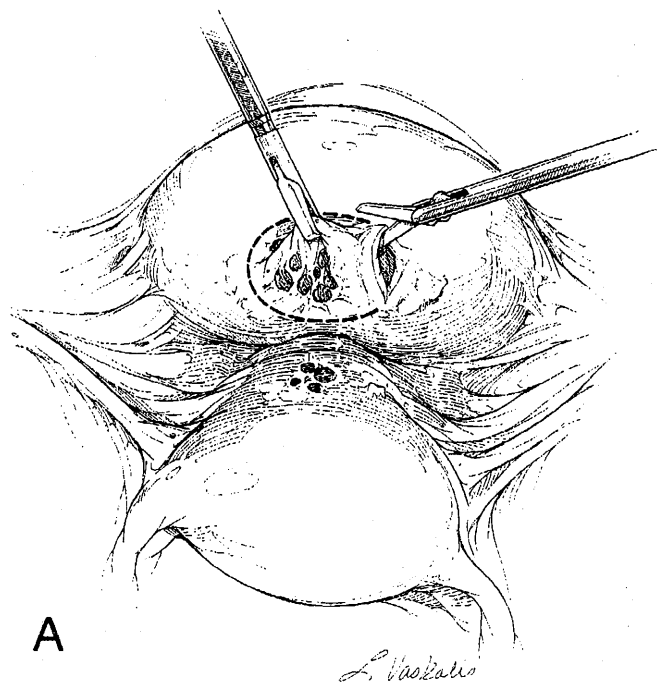
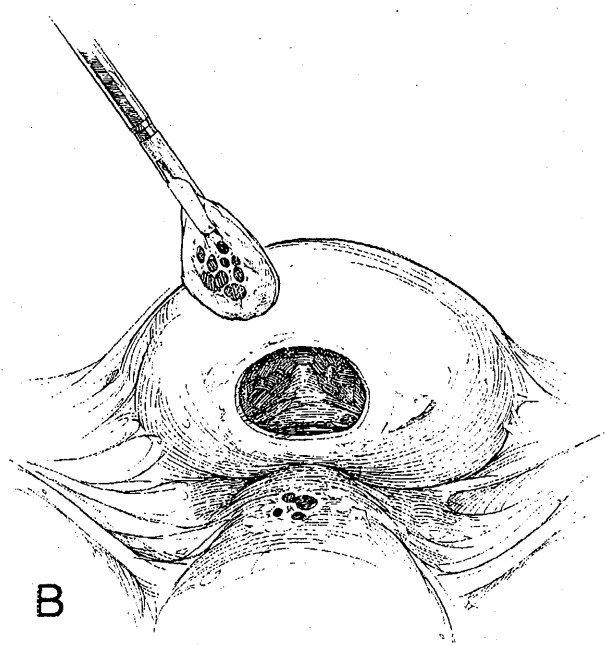


Fig 13. Excision of the occluded segment of the ureter and end-to-end anastomosis. (A) The retroperitoneal space is entered at the pelvic brim. By using a combination of hydrodissection and blunt and sharp dissection, the ureter is mobilized and the affected region of the ureter exposed. A no. 7 French ureteric catheter is inserted under cystoscopic guidance. This catheter helps to identify the distal site of occlusion and acts as a stent for the anastomosis. The ureter is divided above and below the affected section which is excised. (B, C) Grasping forceps are used to maneuver the ureteric catheter into the proximal ureter and on into the renal pelvis. (D) The healthy segments of the ureter are approximated with four 4-0 polydioxanone sutures which are placed at cardinal points (3, 6, 9, and 12 o'clock). (Reprinted with permission.¹⁹)



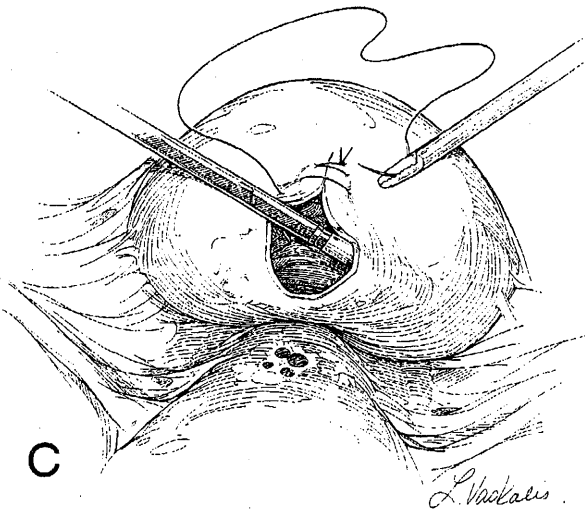
A

L. Nezhat



B

Fig 14. Excision of lesion infiltrating the full thickness of the bladder wall. (A) Grasping forceps are used to elevate the affected portion of the bladder wall. A circumferential excision is made using the CO₂ laser or scissors. The excision lines should be placed 5 mm beyond the limits of the nodule. (B) The specimen is removed from the peritoneal cavity and sent for histologic examination. The interior of the bladder is then distended with CO₂ and the laparoscope inserted through the defect in the bladder wall so that the ureteral openings and bladder mucosa can be evaluated. (C) The defect is repaired with continuous or interrupted 4-0 polydioxanone or 0 Vicryl sutures. These sutures include all tissue layers and are tied extracorporeally or intracorporeally. The bladder is distended with methylene blue or indigo carmine solution and observed laparoscopically to ensure that the suture line is watertight. (Reprinted with permission.¹⁹)



C

L. Nezhat

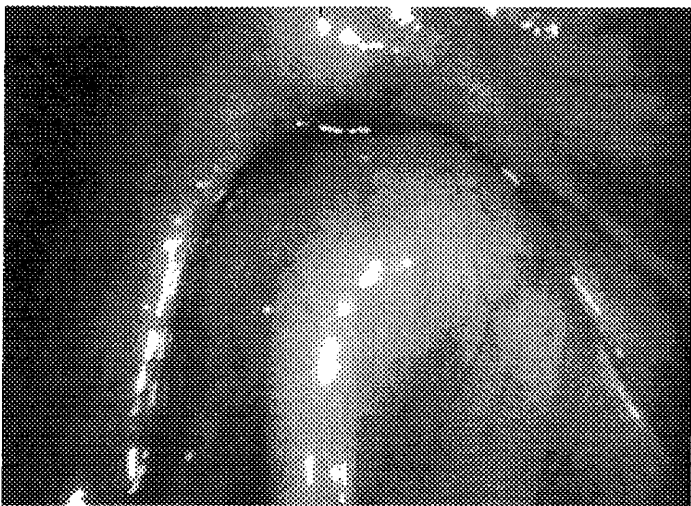

Fig 15. Posterior cul-de-sac obliteration. The rectum is pulled up and is severely attached to the back of the vagina and cervix.




Fig 18. Infiltrative endometriosis of the rectum is being removed by disk excision of the anterior rectum.

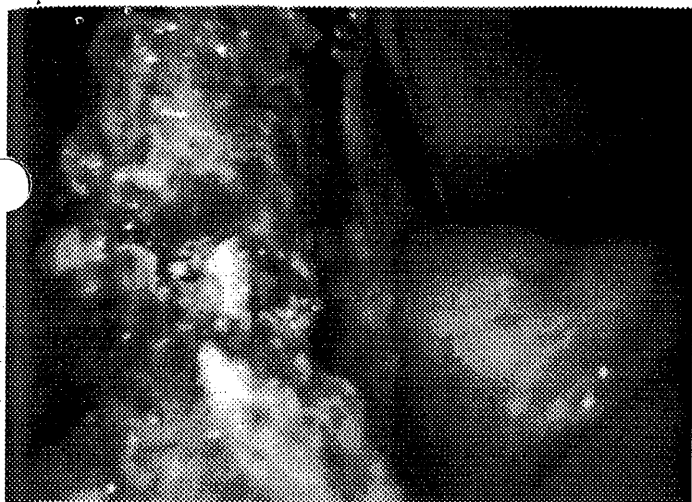


Fig 12. Ureterostomy after the ureteral endometriosis has been removed.

4-0 polydioxanone sutures used. Fewer sutures result in fewer adhesions.³

Genitourinary Endometriosis

Ureteral involvement has been reported in 1% to 11% of women in whom a diagnosis of endometriosis has been confirmed.⁴ It tends to be superficial but can be invasive on occasion and may even result in partial or complete obstruction of the ureter (Fig 10-12). In most cases the diagnosis is made at the time of diagnostic laparoscopy for complaints of

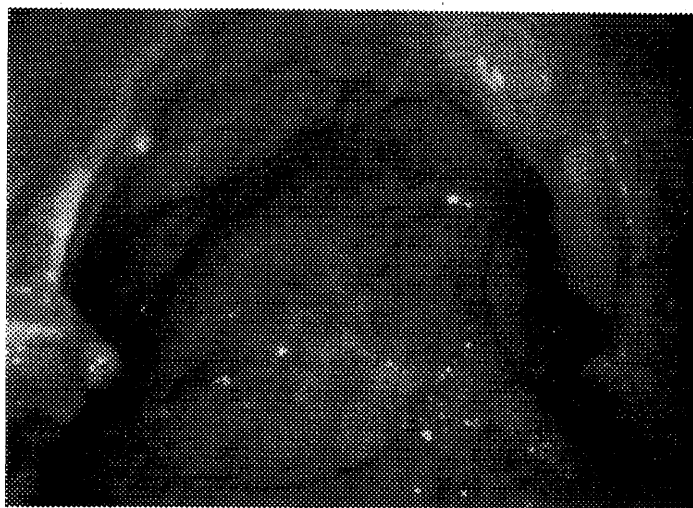

Fig 17. Infiltrative endometriosis of the rectum is being shaved and removed from the anterior rectum.

creatinine and urea levels, ultrasonography of the kidneys, and intravenous pyelography (IVP) should be performed. Cystoscopy is usually reserved for cases where there is evidence of recurrent hematuria or to rule out other pathology.

Surgery for Endometriosis of the Ureter

Hydrodissection, as previously described, has greatly simplified the laparoscopic management of superficial peritoneal implants that are sited over or in close proximity to the ureter. Implants that are firmly embedded, with scarring to the subperitoneal connective tissues, can be more difficult to

ically. The technique for management is shown in Figure 13. The ureteral stents are removed 2 to 8 weeks postoperatively after the integrity of the repair is confirmed by IVP.⁶

Surgery for Endometriosis of the Bladder

Deeply infiltrative endometriosis of the bladder wall is uncommon.⁵ The lesions are usually superficial. When invasive, they usually penetrate the muscularis but spare the mucosa. Rarely they may infiltrate the full thickness of the bladder wall. They can be dealt with by laparoscopic means.

Superficial lesions can be treated by excision, electrodesiccation, or laser vaporization as for other peritoneal implants as previously described. This approach can also be used when the muscularis is involved. It will be necessary to excise the affected muscularis and close the defect. Residual disease can be treated with postoperative ovarian suppression.⁵⁻⁷

If the entire thickness of the bladder wall has been infiltrated by endometriosis it is necessary to excise the affected section of the bladder wall and reconstruct the defect (Fig 14).⁸ A cystoscopy is performed, and when necessary, ureteric catheters are inserted to facilitate the identification of the ureters. The technique for this treatment is shown in Figure 14. A Foley catheter is left in the bladder and removed after 10 to 14 days after a cystogram demonstrates bladder integrity.

Cul-De-Sac Obliteration

The cul-de-sac may be partially or totally obliterated, which is often a source of pain and may hinder oocyte pickup by the fimbria. There is usually a great degree of anatomic disorganization involving the rectosigmoid, vaginal fornix, posterior aspects of the cervix and uterus, ureter, and major blood vessels.⁹

There may be endometriosis of the rectovaginal septum. The bowel should be prepared preoperatively in such cases.

Laparoscopic restoration of the cul-de-sac is not simple and should only be undertaken if surgical and/or urologic assistance is readily available, or by a surgeon who is familiar with the performance of surgery on the gastrointestinal (GI) and urinary tracts. In many cases preliminary adhesiolysis will be required before the cul-de-sac can be approached. The technique for restoration is shown in Figures 15 through 19.

Once the rectum has been mobilized, any endometriotic lesions on the rectum are excised or vaporized with the CO₂ laser. Involved areas may be fibrosed. Vaporization or excision may result in perforation of the bowel. From time to time the cul-de-sac is filled with irrigation fluid and air insufflated into the rectum from below. The appearance of bubbles in the fluid will serve to identify any bowel perforation. Such perforations can be repaired with a single layer of interrupted 3-0 silk, 4-0 polydioxanone, or 0 Vicryl sutures. It is unusual for endometriosis to penetrate the bowel mucosa. It often will involve the serosa and muscularis. If the endometriosis has penetrated deeply and a large segment of bowel is involved, some type of bowel resection is required (see below).

Intestinal Endometriosis

The intestinal tract is involved in 3% to 37% of women with endometriosis.^{10,11} The rectosigmoid is most commonly affected. Clinical presentations vary from the asymptomatic where the disease is noted at the time of laparoscopy or laparotomy to one of complete intestinal obstruction. The presence of intestinal endometriosis should be suspected in any woman of child bearing age who presents with GI symptoms and a history of known endometriosis or intestinal

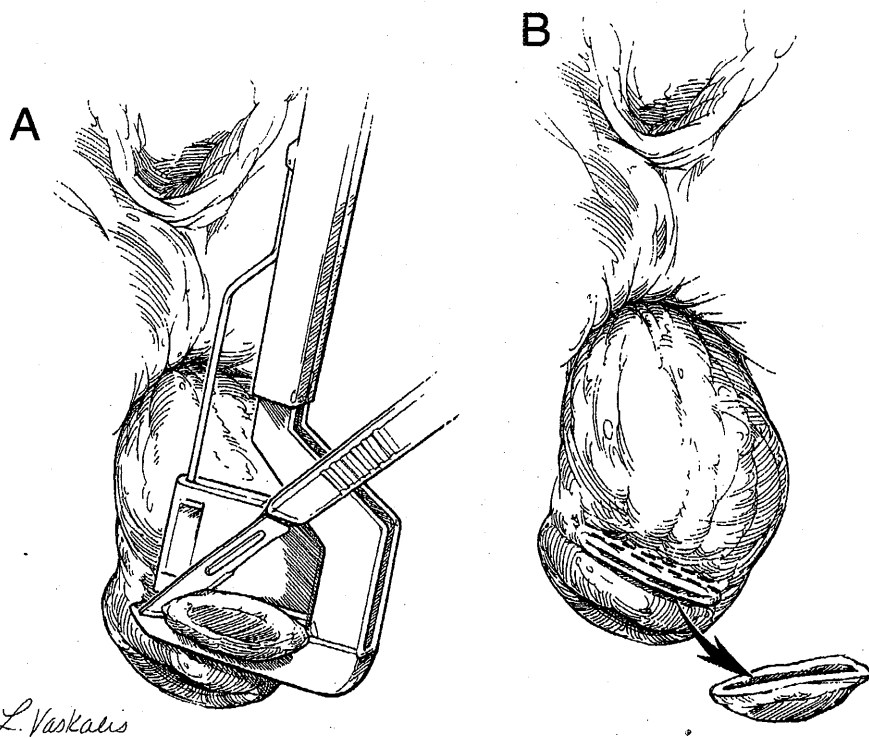


Fig 20. Excision and repair of infiltrating lesion of the anterior rectal wall. (A, B) The rectum is prolapsed and an automatic stapling device used to excise the lesion and repair the defect. The site is reinforced with interrupted 2-0 polyglactin sutures. (Reprinted with permission.¹⁹)

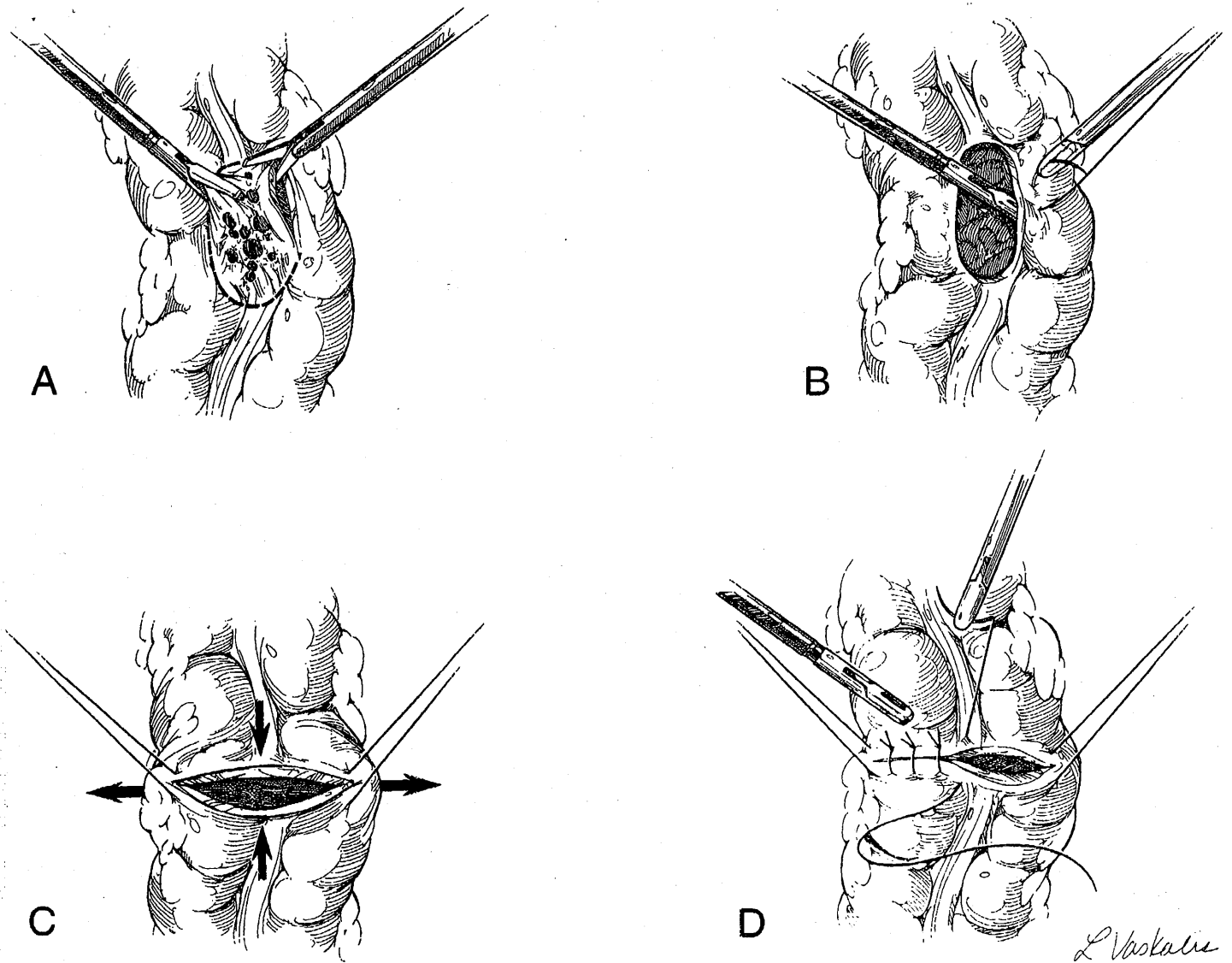


Fig 21. Excision of infiltrating lesion from the anterior wall of the colon. (A) Grasping forceps are used to steady the lesion and a full thickness circumferential incision is made. (B) The affected segment of bowel wall is removed. (C) Stay sutures are placed at the edges of the incision and traction applied to realign the axis of the incision. (D) Interrupted sutures are placed to close the incision transversely. (Reprinted with permission.¹⁹)

stricture in the absence of an intraluminal mass.¹² Cyclical rectal bleeding is a rare presentation and occurs when the lesion infiltrates the bowel mucosa. Because, in addition to the rectosigmoid, the uterosacral ligaments and rectovaginal septum are often involved in the disease process, the patient may complain of low abdominal pain, back pain, dysmenorrhea, and dyspareunia. She may experience diarrhea, constipation, and tenesmus. Radiographic studies that suggest constriction of the bowel, proctoscopy, and colonoscopy may provide helpful clues but are rarely diagnostic.¹³ Occasionally microscopic examination of a biopsy of the bowel mucosa may reveal the presence of endometrial tissue.¹⁴ Laparoscopy is the best method of diagnosis.

The implants can occur at any location from the small bowel to the anal canal. The rectum and sigmoid colon are most commonly affected and involved in 76% of such cases. The appendix and cecum are involved in 18% and 5%, respectively.¹²

Infiltrating bowel lesions may be dealt with by shaving the lesion off the bowel (see below) or full-thickness resection of the affected area of the colon wall and reconstruction of the defect. Extensive and multifocal bowel lesions will require a bowel resection and anastomosis. These procedures can be effected by laparoscopic means. A preoperative full bowel preparation forms an integral part of such procedures.

There are three steps to the procedure: (1) mobilization of the lower colon; (2) transanal, transvaginal, or transabdominal exteriorization of the bowel segments; and (3) resection-anastomosis. The operation is essentially that performed by laparotomy, the role of the laparoscopy being to provide access for the mobilization step.^{13,16}

To mobilize the lower colon and rectum, the lateral rectal pedicles are electrodesiccated and divided and the presacral space entered. Dissection proceeds to the level of the levatores ani. Descending branches of the inferior mesenteric vessels are electrodesiccated and cut.

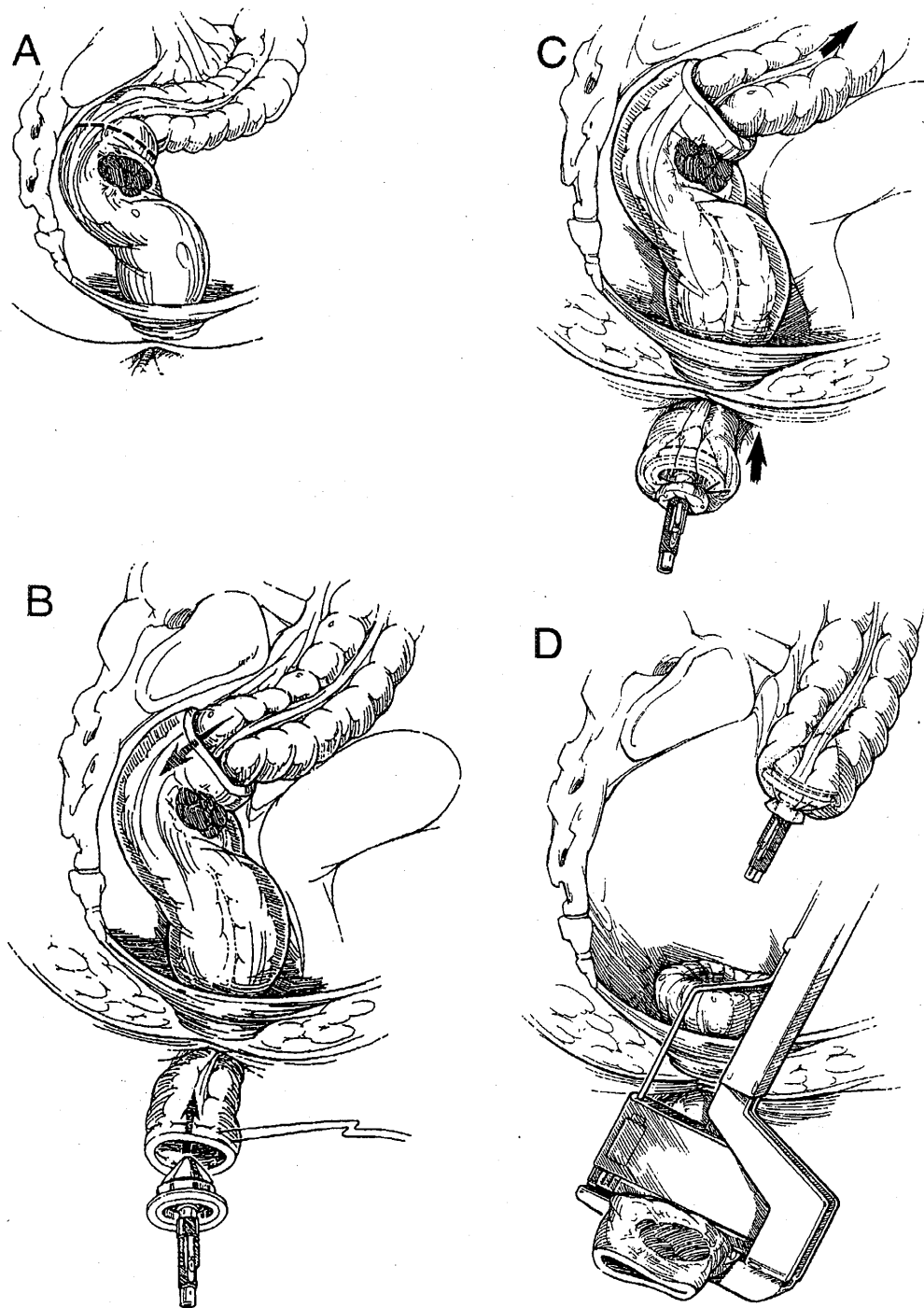
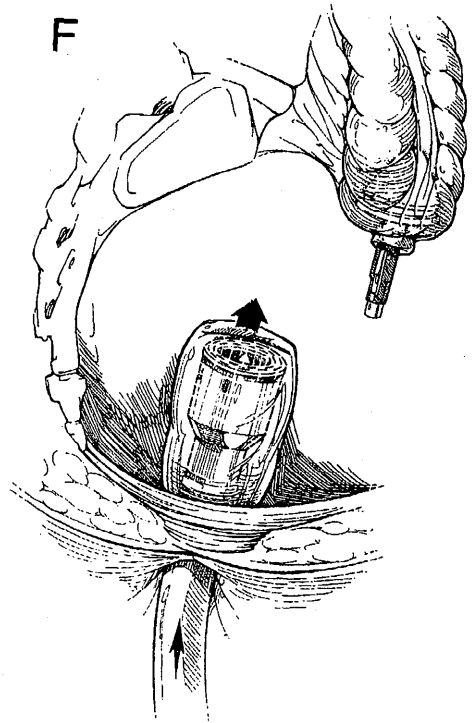
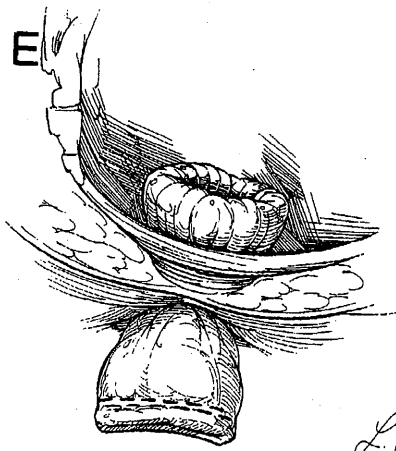


Fig 22. Resection of a rectal segment and end-to-end anastomosis. (A) The rectum is laparoscopically transected cephalad to the lesion. (B) The healthy retrosigmoid is exteriorized by prolapsing it through the rectum and a purse-string suture inserted. (C) The anvil of a 29 or 33 ILS stapler (Ethicon) is inserted into the bowel, and the purse-string tied. (D, E) The healthy rectosigmoid and anvil are replaced in the abdominal cavity. The distal rectum is prolapsed and stapled between healthy tissue and the lesion. The diseased segment is thus excised. (F) The ILS stapler is placed into the closed rectal stump and used to push the stump into the abdominal cavity. (G) The trocar of the stapling device penetrates the rectal stump. Laparoscopic grasping forceps are used to maneuver the anvil over the trocar. (H) The ends of the two segments of bowel are brought together and the stapling device segments of bowel are brought together and the stapling device fired to complete the anastomosis. (Reprinted with permission,¹⁹)

Isolated anterior rectal lesions are treated differently from extensive and multifocal lesions. If an anterior lesion is close to the rectum or vagina, once the lower colon and rectum have been mobilized, the rectum is prolapsed through the anal or vaginal canal until the lesion has been exteriorized. Figure 20 shows the technique for excision of an anterior rectal lesion. The disk excision technique can be performed entirely laparoscopically. The lesion is evaluated visually and by palpation with the tip of the suction irrigator to delineate the extent of involvement. Low lesions can also be palpated by digital rectal examination. Sigmoidoscopy is also used for this purpose. Refer to Figure 21 for the details of the procedure. This technique is especially suitable for higher lesions when the

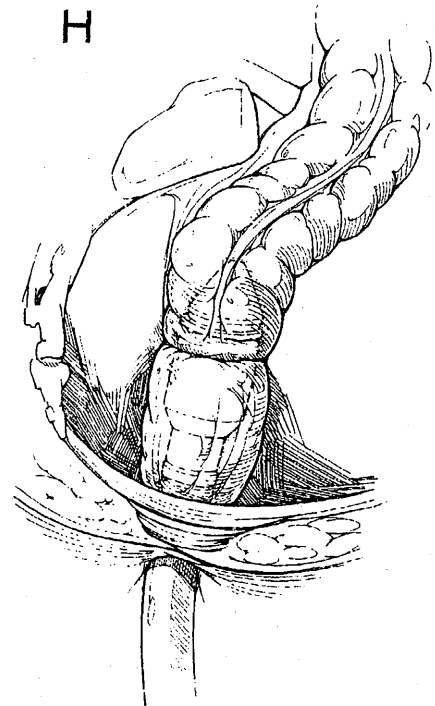
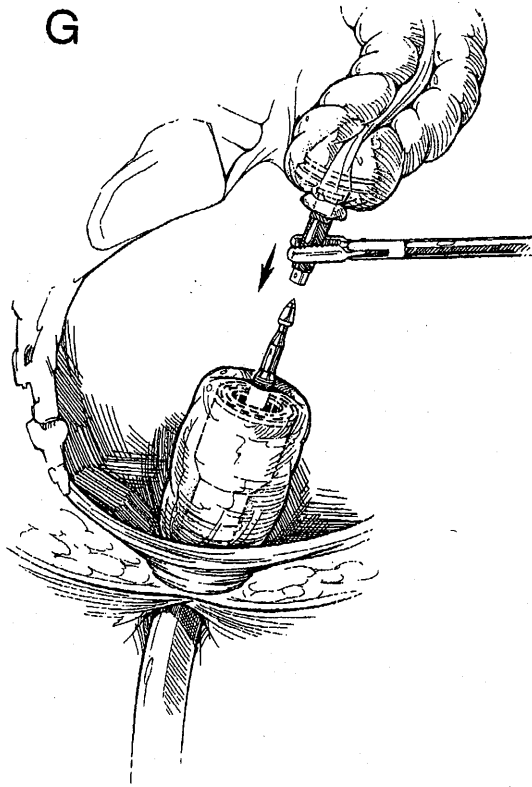
surgeon is skilled in laparoscopic suturing and knot tying. Circumferential lesions are dealt with by excision of the affected segment and end-to-end anastomosis. The technique for this approach is shown in Figure 22. An alternate technique is intraabdominal segmental resection, which is shown in Figure 23.

Once the resection is complete, a series of further steps are taken, irrespective of the method used. A proctoscope is passed to permit inspection of the internal sites of anastomosis to confirm structural integrity and that there is no bleeding. The pelvis is flooded with irrigation fluid and air is insufflated into the rectum. If air is seen to leak, 0 Vicryl or 2-0 polyglactin sutures can be placed to close the defect.



L. Vaskalis

Fig 22. (Cont'd).



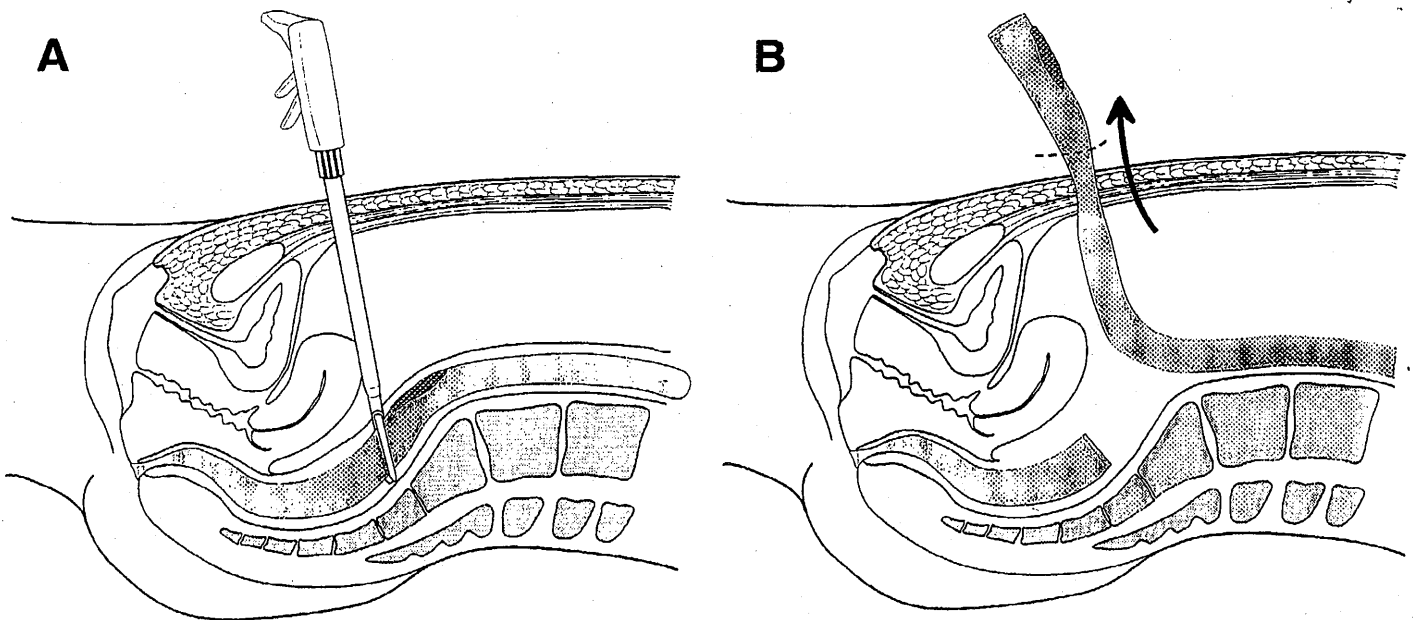


Fig 23. Intraabdominal laparoscopic bowel resection. (A) After the bowel is completely mobilized, an ILS 60 stapler (Ethicon) is fired distal to the lesion. **(B)** The proximal limb of the colon is delivered from the abdomen or through the vagina by posterior colpotomy and the lesion is exteriorized through a small incision. After the lesion is removed, the anvil of the 29 or 33 ILS stapler is applied and the bowel segment is returned to the abdominal cavity. Reanastomosis is performed as previously described. (Reprinted with permission.²¹)

Endometriosis of the Diaphragm

Endometriosis of the diaphragm is rare. In centers that deal with a very large number of patients with endometriosis, such lesions are identified in under 1% of cases.¹⁷ Because most of these cases are asymptomatic, identification of such lesions requires a thorough examination of the under surface of the diaphragm, which is more easily effected by laparoscopy than by laparotomy (Fig 24). The symptoms included pleuritic, shoulder, or upper abdominal pain which may occur in conjunction with menses. Rarely, it can cause catamenial pneumothorax.

Laparoscopic removal of such lesions is hazardous, as the

phrenic nerves, lungs, and heart may all be at risk of injury. All other treatment options should be fully explored before recourse to surgery. A course of medical suppressive therapy may be all that is required, and suppression may be assured if radical treatment of pelvic endometriosis is undertaken. If fertility is still an issue and symptoms have not responded to medical therapy, laparoscopic intervention may be undertaken.

The laparoscope is introduced intraumbilically and three ancillary portals are placed in the upper quadrant, in a fashion akin to that used for cholecystectomy. Two expandable retracting probes or closed grasping forceps are used to retract the

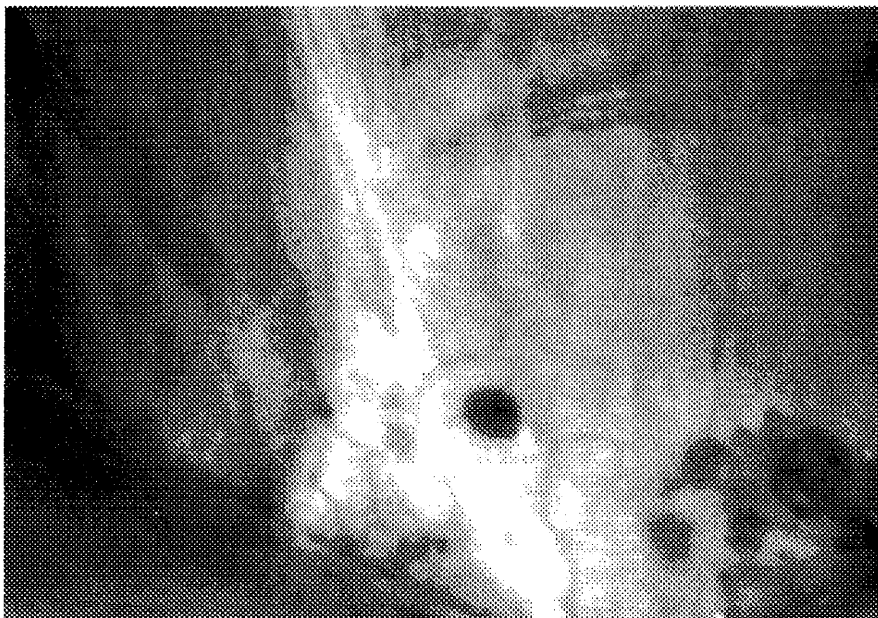


Fig 24. Laparoscopic view of diaphragmatic endometriosis.

liver and expose the operative field. Lesions are removed by a combination of hydrodissection, excision, or laser vaporization. Should a diaphragmatic defect appear it can be repaired with interrupted nonabsorbable sutures.¹⁸

While the patient is still under anesthesia, the pharynx, esophagus, and proximal main bronchi should be evaluated by a cardiopulmonary consultant. Pulmonary endometriosis may coexist.

Conclusion

Laparoscopy is an ideal method for the diagnosis of endometriosis of different stages and colors. The most extensive endometriosis of the pelvis can be treated adequately by laparoscopy in the hands of an experienced laparoscopist who is familiar with the natural history of the disease and supports other disciplines such as colorectal surgeons, urologists, and thoracic surgeons.

References

1. Nezhat C, Nezhat F: Safe laser excision or vaporization of peritoneal endometriosis. *Fertil Steril* 52:149-151, 1989
2. Nezhat F, Nezhat C, Allan CJ, et al: A clinical and histologic classification of endometriomas: Implications for a mechanism of pathogenesis. *J Reprod Med* 37:771-776, 1992
3. Nezhat C, Nezhat F: Postoperative adhesion formation after ovarian cystectomy with and without ovarian reconstruction. Presented at the 47th Annual Meeting of the American Fertility Society, Orlando, FL, October 21-24, 1991
4. Stanley EK, Utz DC, Dockerty MB: Clinically significant endometriosis of the urinary tract. *Surg Gynecol Obstetr* 120:491, 1965
5. Goldstein MS, Brodman ML: Cystometric evaluation of vesical endometriosis before and after hormonal or surgical treatment. *Mt Sinai J Med* 57:109-111, 1990
6. Nezhat C, Nezhat F, Nezhat CH, et al: Urinary tract endometriosis treated by laparoscopy. *Fertil Steril* 66:920-924, 1996
7. Nezhat CH, Seidman DS, Nezhat F, et al: Laparoscopic management of intentional and unintentional cystotomy. *J Urol* 156:1400-1402, 1996.
8. Nezhat C, Nezhat F: Laparoscopic segmental bladder resection for endometriosis: A report of two cases. *Obstet Gynecol* 81:882-884, 1993
9. Nezhat C, Nezhat F, Pennington E: Laparoscopic treatment of lower colorectal and infiltrative rectovaginal septum endometriosis by the technique of videolaseroscopy. *Br J Obstet Gynaecol* 99:664-667, 1992
10. Jenkinson EL, Brown WH: Endometriosis: A study of 117 cases with special reference to constricting lesions of the rectum and sigmoid colon. *JAMA* 122:349-354, 1943
11. Samper ER, Sagle GW, Hand AM: Colonic endometriosis: Its clinical spectrum. *South Med J* 77:912-914, 1984
12. Prystowsky JB, Stryker SJ, Ujiki GT, et al: Gastrointestinal endometriosis: Incidence and indications for resection. *Arch Surg* 7:855-858, 1988
13. Ponka JL, Brush BE, Hodgkinson CP: Colorectal endometriosis. *Dis Colon Rectum* 16:490, 1973
14. Meyers WC, Kelvin FM, Jones RS: Diagnosis and surgical treatment of colonic endometriosis. *Arch Surg* 114:169-175, 1979
15. Nezhat C, Pennington E, Nezhat F, Silfen SL: Laparoscopically assisted anterior rectal wall resection and reanastomosis for deeply infiltrating endometriosis. *Surg Laparosc Endosc* 1:106-108, 1991
16. Nezhat C, Nezhat F, Pennington E: Laparoscopic proctectomy for infiltrating endometriosis of the rectum. *Fertil Steril* 57:1129, 1992
17. Nezhat F, Nezhat C, Levy JS: Laparoscopic treatment of symptomatic diaphragmatic endometriosis: A case report. *Fertil Steril* 58:614-616, 1992
18. Mangal R, Taskin O, Nezhat C, Franklin R: Laparoscopic vaporization of diaphragmatic endometriosis in a woman with epigastric pain: A case report. *J Reprod Med* 41:64-66, 1996
19. Nezhat C, Nezhat F: Endometriosis, in Gomel V, Taylor PJ (eds): *Diagnostic and Operative Gynecologic Laparoscopy*. St Louis, MO, Mosby-Year Book, 1995
20. Nezhat C, Nezhat F, Luciano AA, et al (eds): *Operative Gynecologic Laparoscopy: Principles and Techniques*. New York, NY, McGraw-Hill, 1995
21. Seidman D, Nezhat F, Nezhat CH, et al: Laparoscopic appendectomy and other intestinal procedures, in Azziz R, Murphy AA (eds): *Practical Manual of Operative Laparoscopy and Hysteroscopy* (ed 2). New York, NY, Springer-Verlag, 1996