

# CHAPTER 34

## Complications of Operative Laparoscopy

Wayne S. Maxson, David I. Hoffman, Farr Nezhat, and G. David Adamson

The applications of the laparoscope have extended rapidly from the simple diagnosis of pelvic pathology to tubal sterilization, and—over the past two decades—to the treatment of multiple intraabdominal diseases previously performed by laparotomy. The avalanche of new laparoscopic techniques and instruments has been triggered primarily by uncontrolled demonstrations of feasibility rather than by controlled prospective evaluations of utility and safety.

The complications of operative endoscopy arise from poor technique, poor judgment, inadequate instrumentation, or unavoidable misadventure. The precipitous assimilation of untested novel procedures into routine surgical practice challenges the novice and potentially increases the operative risks.

This chapter outlines some of the more common or most dreaded complications of operative laparoscopy and offers clues for their avoidance and treatment. The photographs in this chapter are from the collections of the authors and of Dr. Dan C. Martin. Fortunately, these complications are from cases from many sources and are not just our own. The quality of the photographs is inevitably influenced by the recording methods available and the composure (or blissful unawareness) of the surgeon.

### PREOPERATIVE PLANNING

Proper preoperative planning is essential to minimize intraoperative problems that otherwise could have been anticipated, and adequate counseling before surgery can make the expectations of patient and families more real-

istic (see the Chapter by Sgarlata, "Preoperative Patient Preparation"). Preparation for the patient considering operative endoscopy must include a review of previous medical records, a discussion of the differential diagnosis and therapeutic alternatives, an accurate assessment of the costs and outcomes, a review of the risks of each alternative, the potential necessity for laparotomy, and an analysis of the anesthetic alternatives. Whenever possible, these discussions should involve both the patient and the partner or parent. Preoperative consultation should include a consideration of special circumstances, such as autologous blood donation, bowel preparation, and antibiotic prophylaxis for mitral valve prolapse. A preoperative vaginal ultrasound scan is recommended for all patients about to undergo pelvic laparoscopy to detect an unsuspected ovarian cyst or uterine tumor that could alter the operative approach.

### OVERVIEW OF LAPAROSCOPIC COMPLICATIONS

Since many surgical complications go unreported, it is difficult to accurately estimate the prevalence of a given adverse outcome. The American Association of Gynecologic Laparoscopists (AAGL) has conducted regular evaluations of complications by reviewing and tabulating responses to questionnaires mailed to all members. Results from three of those questionnaires are provided in Table 1.

The Carbon Dioxide Laser Laparoscopy Study Group reviewed 821 operative laparoscopies performed for multiple indications (4). Complications occurred in 14 women (17.1 per 1000) and all were treated laparoscopically. A single, unplanned laparotomy was performed for suspected small-bowel injury, but none was noted in this patient. No deaths were reported in this series.

W. S. Maxson and D. I. Hoffman: Northwest Center for Infertility, Margate, Florida 33063.  
F. Nezhat: Department of Obstetrics and Gynecology, Stanford University, Palo Alto, California 94304.  
G. D. Adamson: Fertility Physicians of Northern California, Palo Alto, California 94301.

TABLE 1. Evaluation of complications conducted by the American Association of Gynecologic Laparoscopists (AAGL)

Date	Response rate (%)	Number of procedures	Total major complications <sup>a</sup>	Complication rate per thousand	Complications leading to death	Deaths per 100,000 procedures	Ref.
1973	NA	12,182	82	6.8	3	25.0	1
1988	24	36,928	568	15.4	2	5.4	2
1991	17	56,536	573	10.1	1	1.8	3

<sup>a</sup> These numbers perhaps reflect increasingly aggressive gynecologic endoscopy.

Lehmann-Willenbrock et al. summarized the German experience with pelviscopy from 1949 through 1988 (5). Questionnaires were sent to 800 clinics and 215 consultants (private practitioners) in two mailings with a response rate of 44.9% from the former and 66% from the latter. Operative laparoscopies were performed in 98.9% of the clinics and 90.9% of the private practices of those responding. Serious complications occurred in 3.56 per 1000 cases in the summary of procedures from 1949 to 1977, decreasing to 2.36 per thousand in 1986–1988. Deaths from laparoscopy were 24 (90 per 100,000) in 1949–1977, compared to 6 (24 per 100,000) in 1983–1985, and 2 (8 per 100,000) in 1986–1988. In this last series, one patient died from intestinal perforation after leakage from a repaired trocar injury and one from agranulocytosis after bipolar, high-frequency adhesiolysis.

### Compared to Laparotomy

No well-controlled studies have directly compared laparoscopy and laparotomy complication rates. The most serious common laparoscopic injuries are injuries to the internal organs (especially the bowel), hemorrhage, and anesthetic complications. The earlier postoperative ambulation following operative laparoscopy should reduce the rate of pneumonia and thrombophlebitis (6). Laparoscopic surgery may be safer than laparotomy for the surgeon because of a lower risk of percutaneous injury from scalpels or other sharp instruments (7).

Although complications associated with operative laparoscopy may be lower than those associated with laparotomy, certain complications are unique to laparoscopy (8). Anesthesia complications, such as respiratory embarrassment because of increased intraabdominal CO<sub>2</sub> gas pressure and/or deep Trendelenburg position, can occur. Subcutaneous emphysema, pneumothorax, and pneumomediastinum are more common. Cervical laceration and/or uterine perforation can occur with placement of manipulating instruments. Inadvertent intravascular Veress needle placement and CO<sub>2</sub> embolism can result in cardiovascular collapse, as can laceration of a major blood vessel. Injury to organs from blind placement of instruments occurs more often than at laparot-

omy. Unipolar electro-surgical injury poses a greater risk at laparoscopy than at laparotomy. These injuries may also be less recognizable at laparoscopy than at laparotomy. Hemorrhage may be more difficult to control because of reduced ability to apply pressure. In addition, some operations, such as myomectomy, may take longer at laparoscopy. It is important for all surgeons to be aware of these differences in the nature and potential complications between laparotomy and laparoscopy.

## EQUIPMENT AND ANESTHESIA COMPLICATIONS

### Equipment

Major complications can occur at laparoscopy because of inadequate visualization. It is imperative that the surgeon use an adequate laparoscope with matching light cable and an adequate light source. The surgeon requires a high-flow insufflator as well as a sharp Veress needle to maintain the pneumoperitoneum. Gas recirculators may be helpful during laparoscopy when a CO<sub>2</sub> laser is used. Also required are adequate trocars with matching sleeves, so as to avoid electro-surgical capacitance, and matching gaskets. Electro-surgical equipment, both unipolar and bipolar, and matching cords must be available. A laser and a staff knowledgeable in all aspects of its function are necessary when this equipment is a primary modality of energy. Different types of graspers, scissors, and sutures must be available. There must be adequate backup for all of the described instrumentation or else the surgeon may find it impossible to complete the laparoscopic procedure. In addition, working with suboptimal equipment can markedly increase the risk of complications.

### Anesthesia

The 1973 AAGL survey documented an anesthesia complication rate of 0.7 per 1000 cases. No such adverse reactions were reported in the 1991 summary.

Anesthetic morbidity can follow hypoventilation (esophageal or endobronchial); aspiration of gastric contents, arrhythmias (rapid insufflation of carbon diox-

ide at pneumoperitoneum), vascular gas embolism, and gastric distention. These complications can be minimized by the routine use of a nasogastric tube, a short and cuffed endotracheal tube, slow induction of pneumoperitoneum with CO<sub>2</sub>, maintenance of adequate relaxation, automatic control of maximum intraabdominal pressure, pulse oximetry, and measurement of expired CO<sub>2</sub> levels (see the Chapter by Collins and Jackson, "Anesthesia in Hysteroscopic and Laparoscopic Infertility Procedures.")

## INTRAOPERATIVE SURGICAL COMPLICATIONS

### Needle and Trocar Injuries

Most complications from laparoscopy have been reported to occur at the time of Veress needle or trocar insertion (9). Superficial introduction of the needle can lead to extraperitoneal insufflation and emphysema, which can dissect the peritoneum from the posterior rectus sheath and limit entry into the peritoneal cavity. Alternative approaches to the establishment of a pneumoperitoneum in these cases include open laparoscopy, passage of the needle vaginally through the posterior cul-de-sac or the uterine fundus, introduction of the needle in the left upper quadrant, or suprapubic needle insertion under visualization by the extraperitoneally placed laparoscope (10).

Responses (50.9% response rate) to a questionnaire mailed to the Society of Obstetricians and Gynecologists of Canada indicated that 26.7% of 407 gynecologists had encountered at least one Veress needle injury (11). The majority of these injuries involved the bowel (30.3%) and significant blood vessels (28.4%).

Techniques to minimize or identify a needle-induced injury include umbilical introduction with the patient supine and the abdominal wall elevated, minimal advancement of the needle after feeling two levels of resistance, and use of a needle placement test, such as the hissing sound, the aspiration test, the hanging drop test, or identification of low intraabdominal pressure (12).

Even after apparent successful induction of pneumoperitoneum, intraabdominal injuries can follow the insertion of the primary umbilical trocar. In the Canadian review, the majority of respondents indicated that they established a large pneumoperitoneum first. Nevertheless, in this summary, 25.6% of physicians had encountered a vascular or organ injury attributed to the primary trocar (11).

Direct insertion of the umbilical trocar without prior pneumoperitoneum reduces the number of blind insertion steps and avoids the risks of extraperitoneal insufflation, gas embolism, and pneumointestine (13).

Further, the Veress needle has been implicated in more major vascular injuries than has the trocar (14).

Copeland et al. (15) used the direct trocar insertion technique in more than 2000 unselected patients with only three major complications. In a high-volume training center at Tripler Army Medical Center, 937 laparoscopies involving direct trocar insertion were reviewed (16). No major complications were reported and minor adverse effects decreased with departmental experience from 5.3% to 1.3% over 3 years. Interestingly, in this series the skill level of the surgeon did not affect the complication rate. Two thirds of the minor complications encountered occurred in obese patients.

Nezhat et al. compared the Veress needle method to the direct trocar technique in 200 patients, none of whom had had previous laparotomy (13). No major complications were associated with either approach. Minor adverse effects (emphysema of the retroperitoneum or omentum) occurred in 22% of the Veress group, whereas only 3% of the trocar group experienced complications (omental perforation and subcutaneous emphysema). All three of the direct trocar problems were seen in the 50 patients receiving the conventional reusable instrument. No complications occurred in the 50 women who received the disposable trocar, but 20% (10 patients) in each direct trocar group required two insertion attempts; 8% of those with the reusable and 4% of those with the disposable resulted in failed insertions.

### Vascular Injuries

Whereas some gastrointestinal perforations at laparoscopy may be inevitable, the majority of injuries to the great vessels of the abdomen and pelvis should be avoidable. Indeed, most vascular trauma affects the smaller blood vessels of the omentum, mesentery, pelvic viscera, and abdominal wall.

Although vascular injuries account for 30–50% of surgical trauma at laparoscopy (11), the frequency of perforation of the aorta, iliac vessels, or vena cava is probably less than 1 per 1000. A survey of the Royal College of Obstetricians and Gynaecologists in 1978 reported injury to the great vessels in 0.9 per 1000 laparoscopies (17). A contemporaneous review of 100,000 laparoscopies in France identified 31 major vascular injuries (0.3 per 1000 cases) (18). The Veress needle accounted for 36% of vascular perforations, whereas the primary and secondary trocars each caused about 32%.

The usual site of trauma to the large vessels is the terminal aorta near its bifurcation and the common iliac arteries. Only 1 woman out of 15 with major vascular injuries reviewed by Baadsgaard et al. had an injury to the external iliac vessels (14). The vena cava and the iliac veins may also be lacerated and may be more difficult to repair.

The anatomy of the abdomen and the alterations in organ relationships consequent to the Trendelenberg position help to explain these serious injuries. In nonobese women, the distance from the umbilicus to the aortic bifurcation averages 6 cm (19), and the umbilicus is directly over or cephalad to the bifurcation in 53% (20). In obese women, the umbilicus lies directly over the aorta in only 30% of cases. The Veress needle and the trocar should be inserted with the patient flat and not in the Trendelenberg position, since this displaces the umbilicus upwards, brings the common iliac vessels closer to the horizontal plane, and decreases the distance between the umbilicus and the aortic bifurcation (12).

Vascular perforation, like bowel injuries, can be minimized by careful attention to anatomy and by smooth needle and trocar introduction. Adequate skin incisions, sharp instruments, and controlled insertion are all necessary. For the auxiliary trocars, introduction under direct visualization is mandatory, following identification of the inferior epigastric and external iliac vessels.

### Deep Epigastric Vessels

Injury to the deep epigastric vessels is the most common vascular injury at operative laparoscopy. The deep epigastric artery and its veins come off the external iliac artery near its transition to the femoral artery and lie in the medial peritoneal fold of the internal inguinal ring. The round ligament curls around these vessels on entrance into the inguinal canal. Deep epigastric vessels are adjacent to the obliterated umbilical ligaments and be-

neath the lateral margin of the rectus muscle (Figs. 1 and 2) (21). The deep epigastric vessels can be seen through the laparoscope intraabdominally. Placement of trocars lateral to this region will minimize injury. The lower quadrant secondary puncture trocars should be placed under direct vision. Transillumination aids primarily in visualization of the superficial epigastric vessels. Should bleeding occur from the deep epigastric vessels, the first approach to diagnosis and management includes rotation of the trocar through 360° to determine where the bleeding site is, followed by immediate control of the bleeding (Fig. 3A). The Kleppinger bipolar electro-surgical forceps can then be used to desiccate the deep epigastric vessels above and below the site of injury (Fig. 3B). Should this not be successful, pressure can be placed in the region by passing a Foley catheter through the 5-mm sheath, insufflating the balloon and pulling it snugly up against the abdominal wall, and maintaining pressure by placement of a Kelly or similar clamp over a 4 × 4 gauze wedged against the skin. The Foley catheter can be released approximately 10 min later to facilitate evaluation of bleeding and/or to attempt to maintain hemostasis with the Kleppinger bipolar electro-surgical forceps, since bleeding may well be reduced. Copious irrigation of the area helps to identify the bleeding site. Should this approach be unsuccessful, a figure-of-eight suture with either a straight or a curved needle can be placed through-and-through the anterior abdominal wall; alternatively, a figure-of-eight suture can be placed laparoscopically, although this is more technically difficult (Fig. 3C). In the unlikely event that these approaches are unsuccessful, the lower quadrant should be explored from the skin

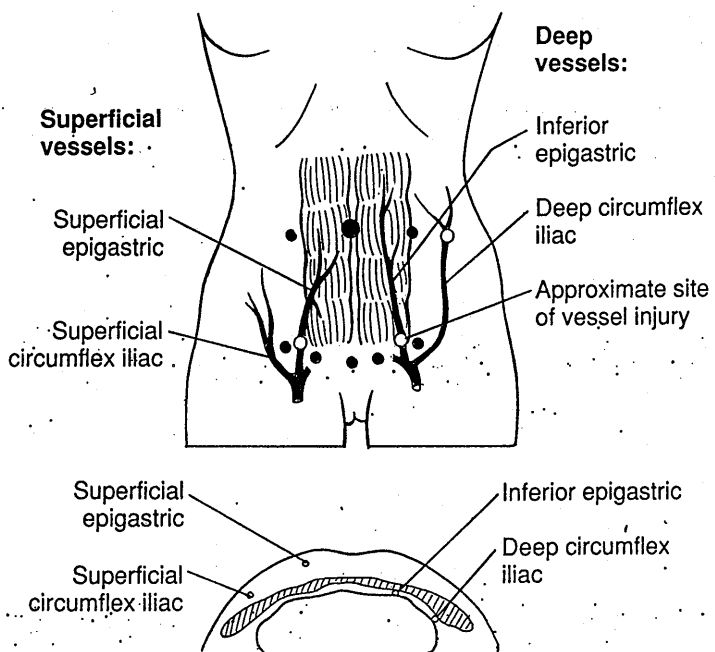
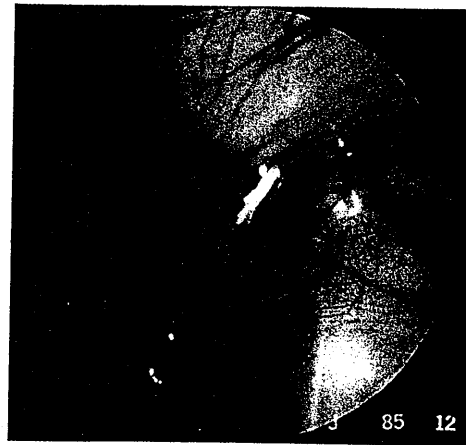
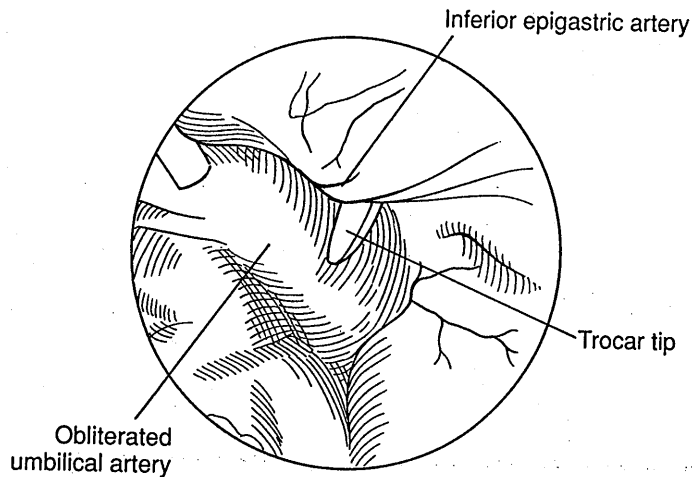


FIG. 1. Approximate location of the superficial and deep vessels of the anterior abdominal wall, frontal and axial views. In the frontal view, dashed lines indicate the relative location of the lateral margin of the rectus abdominis muscle, and solid circles indicate ideal laparoscopic trocar placement sites. The open circles indicate the approximate sites of vessel injuries in three reported cases (21). In the axial view, taken at a level 1 cm below the umbilicus, soft tissue layers are indicated in gray and bone in white.



**FIG. 2.** Identification of the inferior epigastric vessels. The inferior epigastric vessels lie retroperitoneal and lateral to the easily identified obliterated umbilical arteries. Here the inferior epigastric artery is stretched across the sharp tip of the trocar. Bipolar coagulation was used for hemostasis through a separate puncture site.

and ligation of the vessels carried out. After hemostasis is obtained, copious irrigation and aspiration should be performed to evacuate any hematoma. Small hematomas will resolve spontaneously (Fig. 4).

#### *Anterior Abdominal Wall*

Bleeding from the anterior abdominal wall can also occur from the superficial epigastric vessels, the rectus muscle, or from small vessels in the skin and subcutaneous tissue. In general, this bleeding can be controlled with external pressure. Should this not be successful, ligation or an electrosurgical approach is necessary. It is imperative that the abdominal puncture sites be observed carefully with and without the pneumoperitoneum upon removal of trocars at the completion of the operation to ensure that vascular injury that was unrecognized because of pressure of the transabdominal instruments is now identified. Intrarectal sheath bleeding, in particular, can be difficult to diagnose.


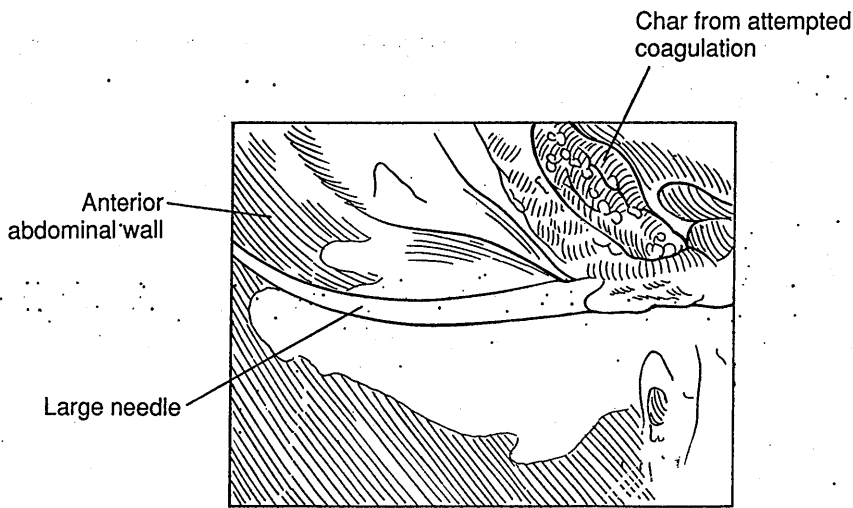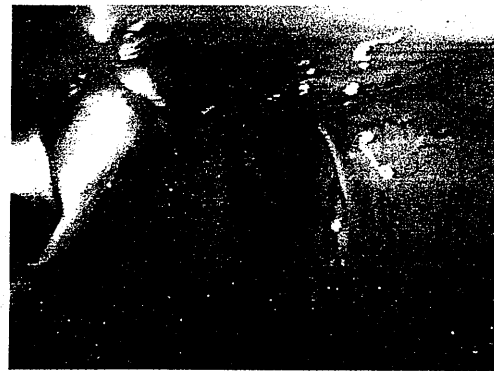
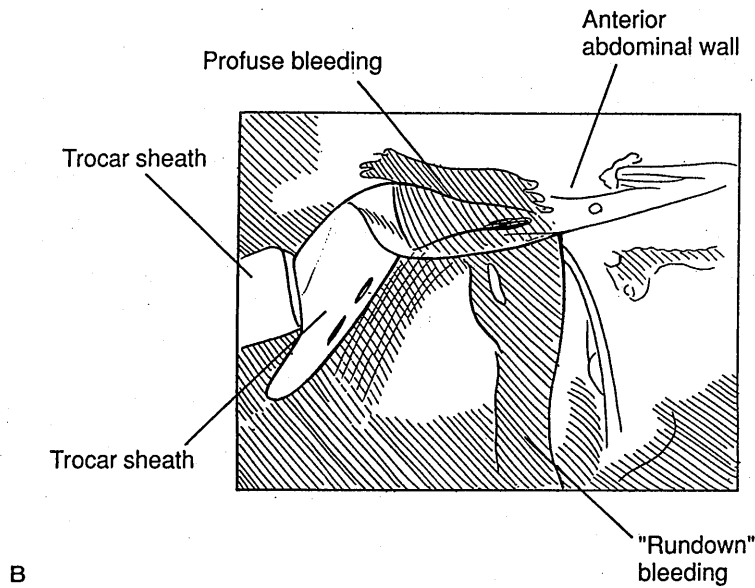

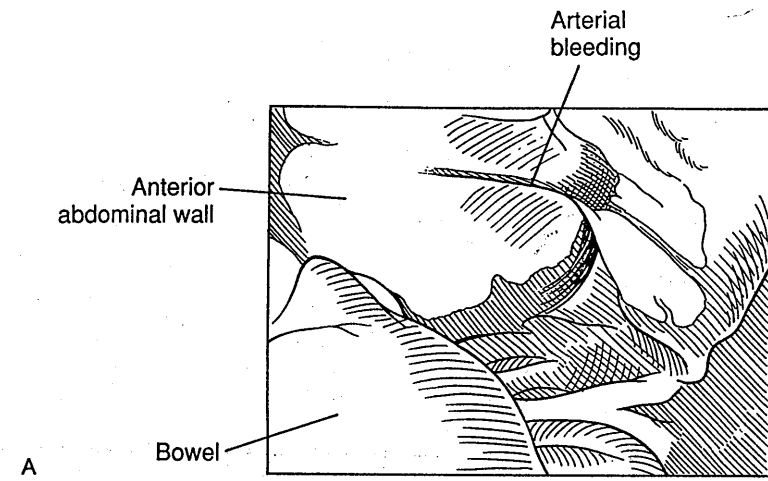
#### *Large Vessels*

Large-vessel injury to the aorta, inferior vena cava, or common iliac artery or vein can be life threatening. Frequency of perforation is approximately 1 per 1000 cases or less (17,18). The usual site of injury is the terminal aorta near its bifurcation and the common iliac arteries (14). Such injuries are usually caused by the Veress needle or the trocar (Fig. 5A). Risk of injury can be reduced by the supine position, elevation of the abdominal wall, advancement of the needle through two layers of resistance in a Z fashion, placement of cervical traction to

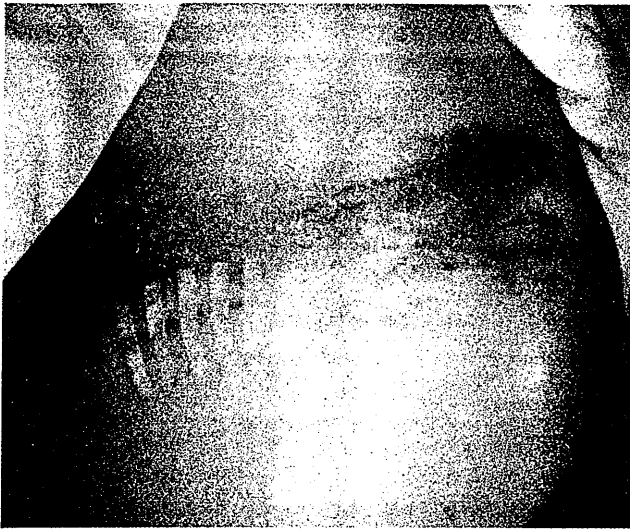
move the fundus inferiorly, and use of tests of needle placement such as the hissing sound, the aspiration test, the hanging drop test, and identification of a low intraabdominal pressure (12). Careful attention to anatomy, adequate skin incisions, and sharp instruments is also important. In one series, 2 of 15 patients with major vascular injuries died (14). These injuries may result in immediately obvious, copious intraabdominal hemorrhage, in which case immediate laparotomy and management by a vascular surgeon is indicated (Fig. 5B). However, such injury may not appear immediately because of increased intraabdominal pressure (10–15 mm Hg) caused by insufflation of CO<sub>2</sub> gas, decreased venous pressure from Trendelenburg position, and retroperitoneal hematoma, which may tamponade the large vessels. However, postoperatively, when pressure returns to normal, bleeding may occur. Therefore, it is essential that the large intraabdominal vessels be examined at the beginning and end of the operative procedure to evaluate their integrity. The Veress needle tends to produce a round hole in a vessel and may be observed postoperatively with the patient in the intensive care unit if there appears to be no active bleeding. However, a triangular hole is created by a trocar and merits immediate laparotomy and exploration with a vascular surgeon. Retroperitoneal hematomas can be exceedingly difficult to identify, and merit very careful examination and exploration to prevent major morbidity and mortality. Retroperitoneal injury occurs more commonly in thin patients.

#### *Intrapelvic Vessels*

Intrapelvic vessels, including the ovarian and uterine vessels, can bleed profusely if injured during surgery (Fig.

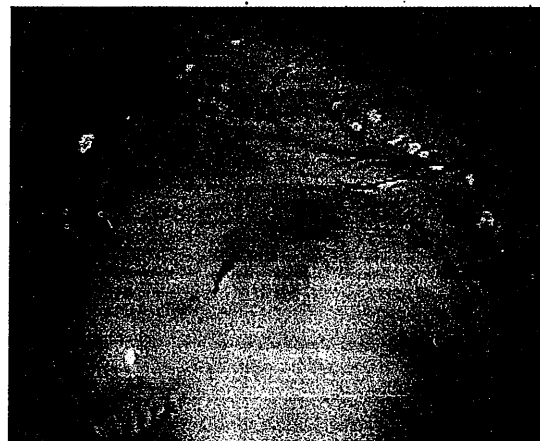
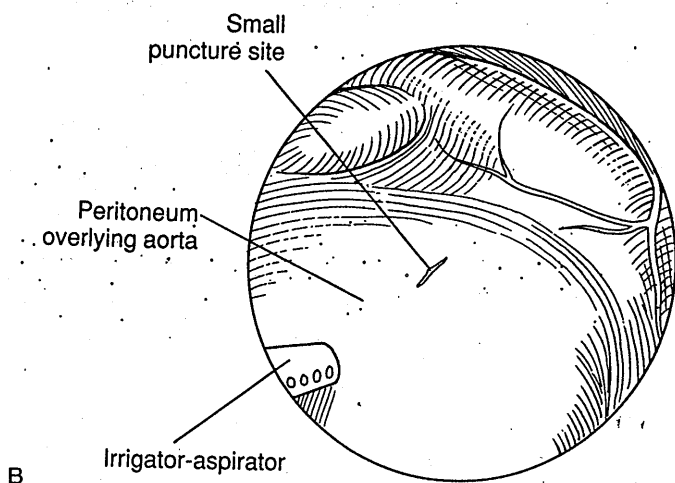
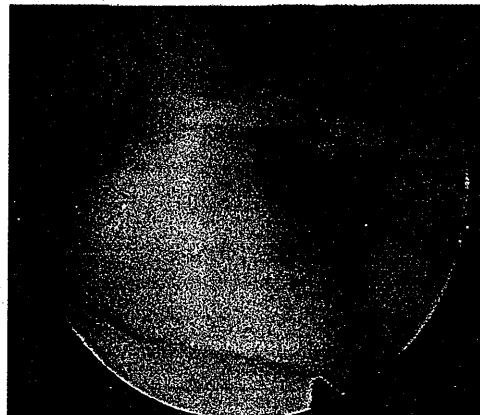
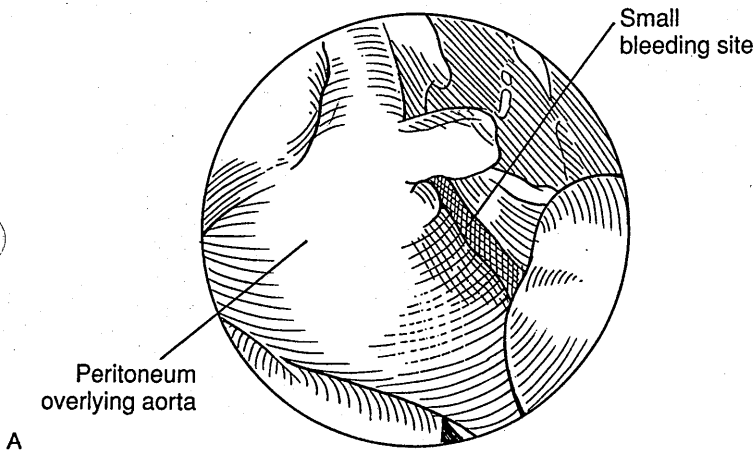


**FIG. 3.** A: Arterial bleeding from the inferior epigastric vessels cut with the secondary trocar. Attempts at tamponade are unsuccessful. B: Bleeding continues. Bipolar cauterization of the trocar track may be beneficial, but the inferior epigastric vessels often retract and require suturing. C: In this case, a large needle is passed and tied on the anterior abdominal wall for hemostasis.

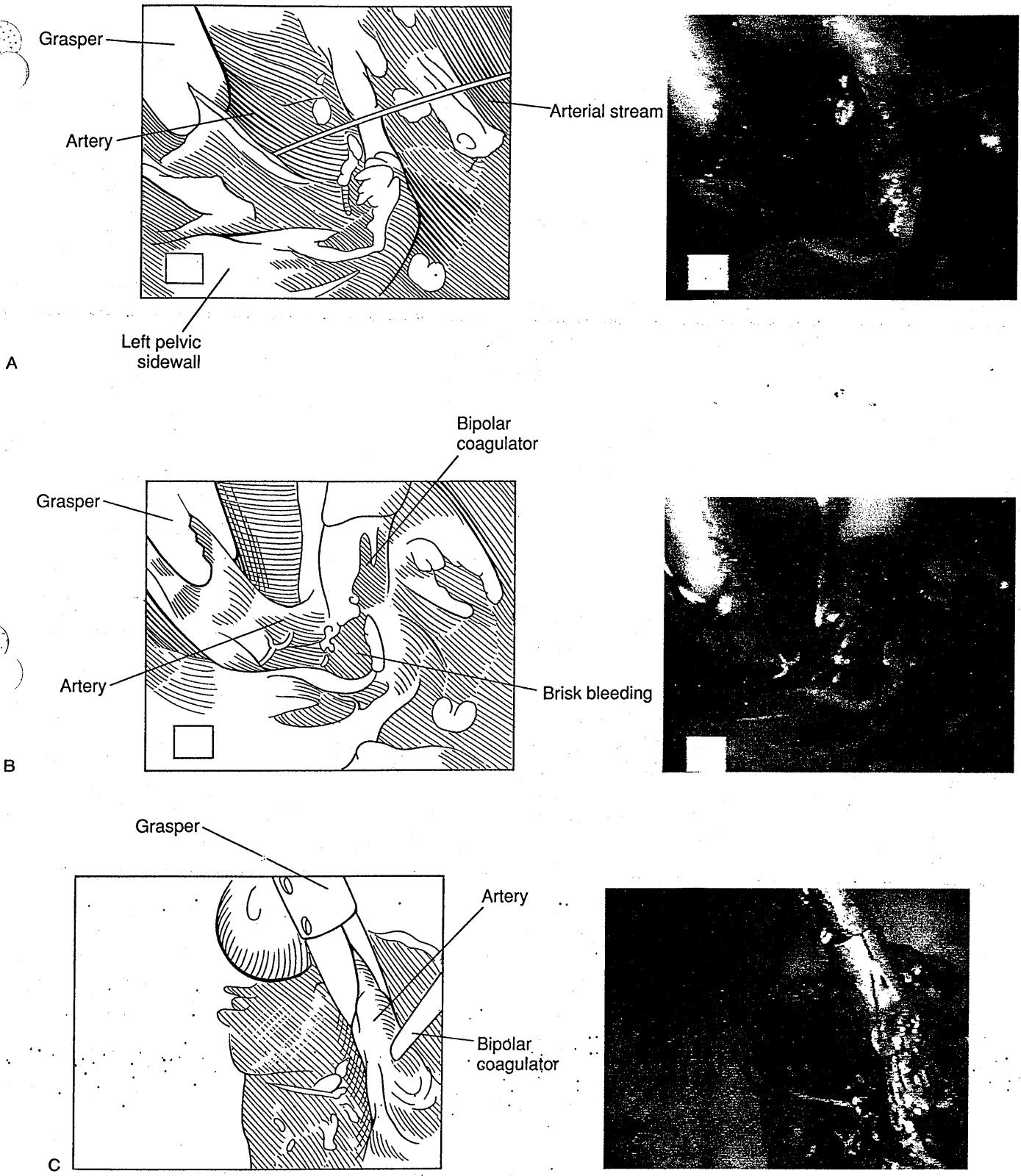


**FIG. 4.** Subcutaneous hematoma after ligation of the inferior epigastric vessels. This small hematoma with impressive ecchymosis resolved spontaneously.

6A,B). The initial approach is to obtain hemostasis through application of a blunt clamp to the vessel to enable adequate visualization of the vessel and surrounding structures, such as the ureter. Hemostasis can then be obtained by use of bipolar electrosurgery, clips, or occasionally loop ligature (Fig. 6C). Injury to these vessels can be avoided by careful identification of the anatomy, use of backstops when laser is used, hydrodissection to identify tissue planes and structures, and placement of fluid in the cul-de-sac to produce a backstop for CO<sub>2</sub> laser energy (Fig. 7). Power density needs to be appropriate for the nature of the disease, anatomic location, and surgeon's skill. Finally, pulsing of the pedal when using the laser, and/or the use of small strokes with the electro-surgical needle, and/or small bites with the endoscopic scissors will reduce the risk of injury. Adequate hemostatic control also can be enhanced throughout the operation by the surgeon's ensuring that bleeders are identified and controlled immediately rather than allowing multiple bleeders to develop within the pelvis.

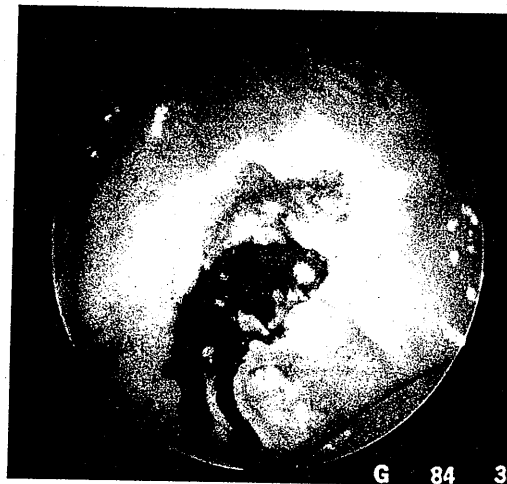
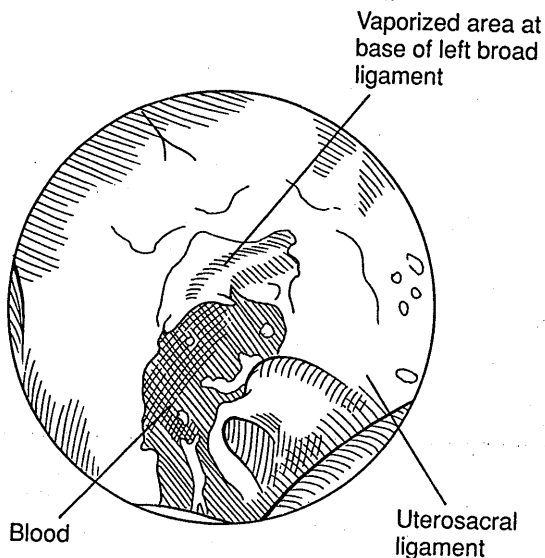


**FIG. 5. A:** Puncture of the aorta with the Veress needle. Minimal intraperitoneal bleeding is seen in a patient with an acute drop in blood pressure after induction of pneumoperitoneum. **B:** A small puncture site is seen and overlies a retroperitoneal hematoma which expands under direct visualization. An immediate laparotomy is required.



**FIG. 6. A:** Coagulation of a lacerated pelvic artery. Dissection of adhesions to the lateral pelvic side wall cut a small but persistent artery. **B:** Bipolar coagulation is hampered by brisk bleeding. **C:** Elevation of the artery with compression reduces the blood flow and permits successful coagulation and hemostasis. Alternatively, clips or sutures could be used as long as the location of the ureter is known.

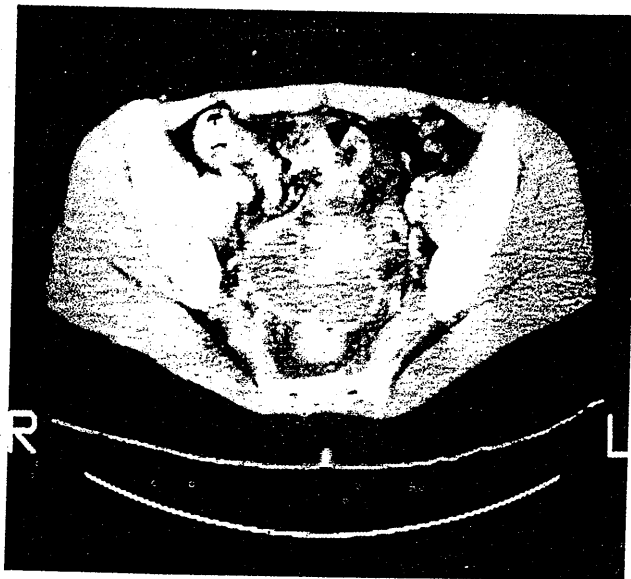




**FIG. 7.** Arterial bleeding lateral to the uterosacral ligament. Resection or vaporization of the uterosacral ligaments risks perforation of the branch of the vaginal arteries, which courses just lateral to and sometimes beneath the ligament. Bipolar cauterization is usually effective, but care must be taken to avoid the ureter, which can lie immediately lateral to the uterosacral ligament.

**Peritoneum**

Bleeding from the peritoneum can be prevented by careful attention to the anatomy and appropriate use of titanium backstops for laser as well as by placing fluid in

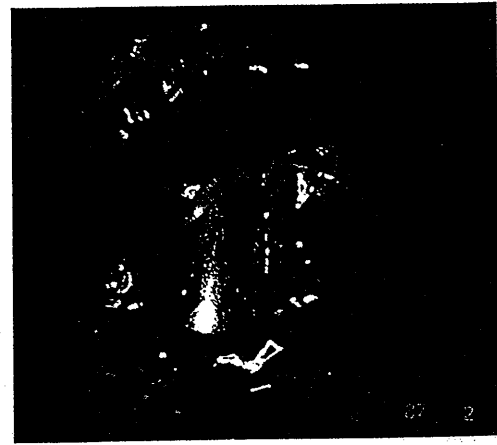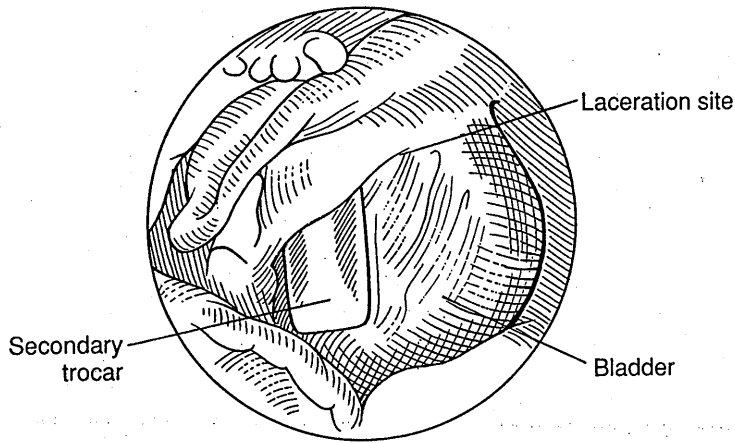


**FIG. 8.** CT scan of a hematoma in the posterior cul-de-sac. Eighteen days prior, the patient had a laparoscopy with lysis of dense right ovarian and bowel adhesions and resection of severe recurrent pelvic endometriosis. Postoperatively, the patient was transfused two units of packed cells and discharged. Despite absence of infection and evidence of gradual resolution of the hematoma by serial ultrasound scans, a laparotomy was performed with evacuation of the hematoma 42 days after initial surgery because of persistent pelvic pain.

the pelvis to act as a backstop for CO<sub>2</sub> laser. Small bleeders can be observed, as these may stop on their own. The CO<sub>2</sub> laser beam coagulates small vessels adequately. Electrosurgical bipolar and unipolar units can be utilized for hemostasis. In addition, pressure with instruments or clamps, use of the argon beam coagulator in selected circumstances, and warm Ringer's solution may assist in obtaining hemostasis on peritoneal surfaces. It is imperative that the pneumoperitoneum be decompressed for at least 3 min "by the clock" at the end of surgery to allow small bleeders tamponaded by the pneumoperitoneum to be identified through direct visualization and the finding of trailers in a fluid bath placed in the pelvis. The patient should also be placed in reverse Trendelenburg position near the end of the procedure to allow intraabdominal fluid and blood, which may have accumulated in the upper abdomen, to flow into the pelvis and be aspirated. Bleeding may also occur from mesosalpingeal tears as a result of inappropriate traction on the fallopian tube. These vessels must be coagulated carefully to avoid devascularization of the fallopian tube. Vascular adhesions may also bleed; these should be coagulated prior to division. These procedures will help ensure that intraoperative and postoperative bleeding will be minimized and not result in postoperative hematomas (Fig. 8).

**Cervix and Uterus**

Cervical laceration following placement of the cervical clamp for uterine manipulation is usually minor but in selected instances merits repair with an interrupted su-



**FIG. 9.** Laceration of bladder muscularis with the secondary trocar. Four hundred ml of saline and methylene blue were instilled into the bladder and no leakage was seen. The patient was treated with 10 days of an indwelling Foley catheter without complication.

ture. Uterine perforation can also occur with the uterine manipulator or through injury from the primary or secondary abdominal puncture sites. Hemostasis should be obtained with the electro-surgical bipolar unit. Further repair of the uterus is generally unnecessary.

#### **Abdominal Wall**

Abdominal wall vessel injury occasionally results in a hemocele. This should be treated with drainage and copious irrigation and appropriate hemostasis with electro-surgery or suture.

#### **Omental Vessels and Bowel Mesentery**

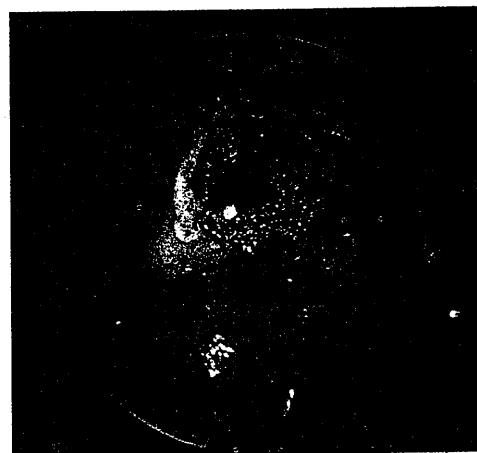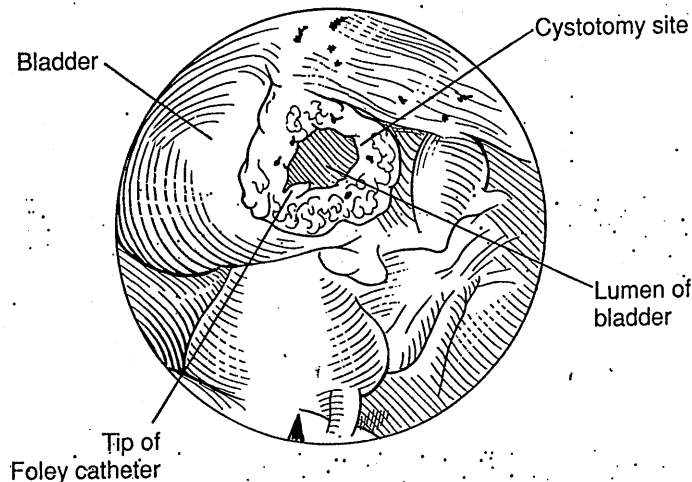
Bleeding from omental vessels or bowel mesentery can occur from injury associated with placement of the

Veress needle or trocar. Such bleeding is often self-limited but can be controlled with bipolar electro-surgical desiccation.

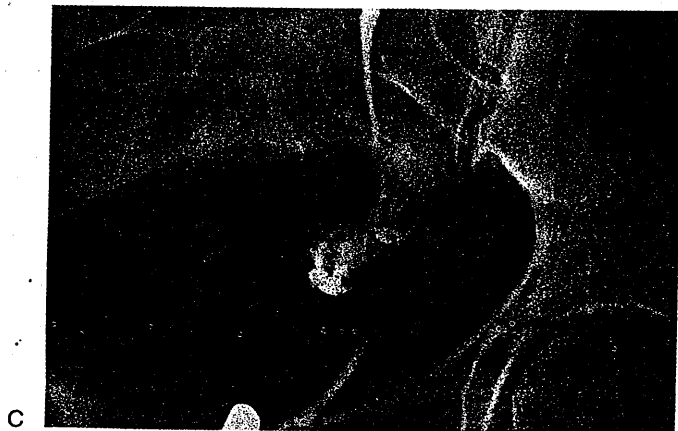
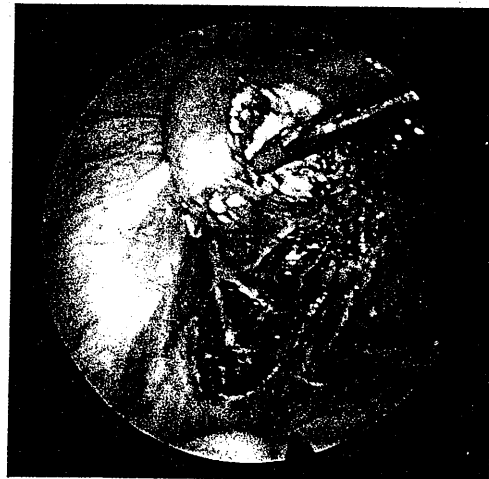
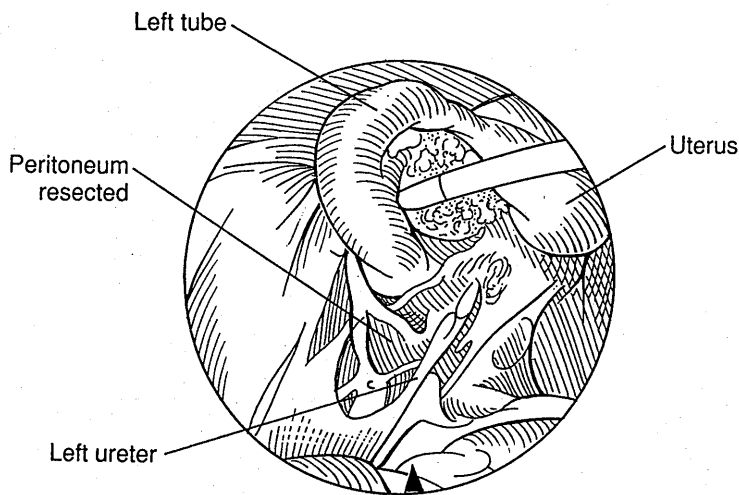
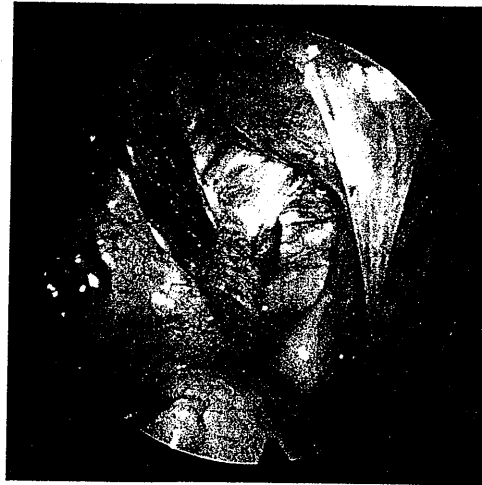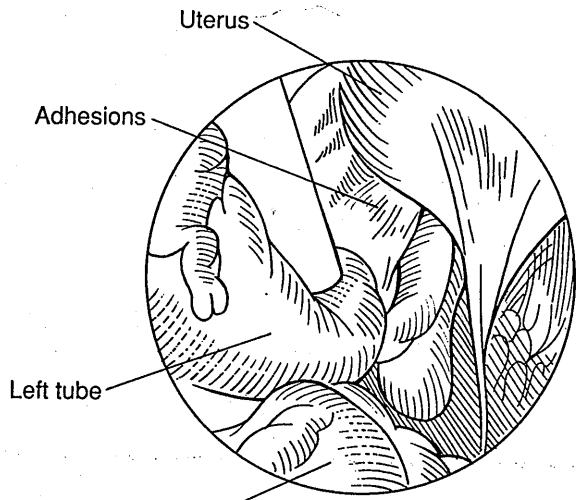
#### **Urinary Tract Injuries**

##### **Bladder**

Bladder perforation can result from placement of the Veress needle or the primary or secondary trocars in the lower abdomen (11) (Fig. 9). Since the routine use of a transurethral catheter to drain the bladder, needle or trocar perforations of the bladder have been rare. A survey of Canadian gynecologists indicated that the occurrence of Veress needle injuries equaled those caused by trocars and that the trocar perforations were evenly distributed between the primary and accessory instruments (11).



**FIG. 10.** Cystotomy during adhesiolysis. A bladder laceration during lysis of extensive adhesions was repaired by minilaparotomy and a two-layer closure. A Foley catheter was left in place for 10 days and the patient recovered uneventfully.



**FIG. 11. A:** Left tube and ovary adherent to the broad ligament. Severe left adnexal adhesions are seen with nonvisualization of the left ovary and distal tube. **B:** The adhesions have been lysed and the broad ligament endometriosis resected. The left ureter is visualized after superficial coagulation to stop bleeding from an ureteral vessel. **C:** A ureteral fistula is diagnosed 4 days postoperatively and treated with a stent for 4 weeks. Replacement of the stent was required because of persistence of the fistula, which healed after another 4 weeks.

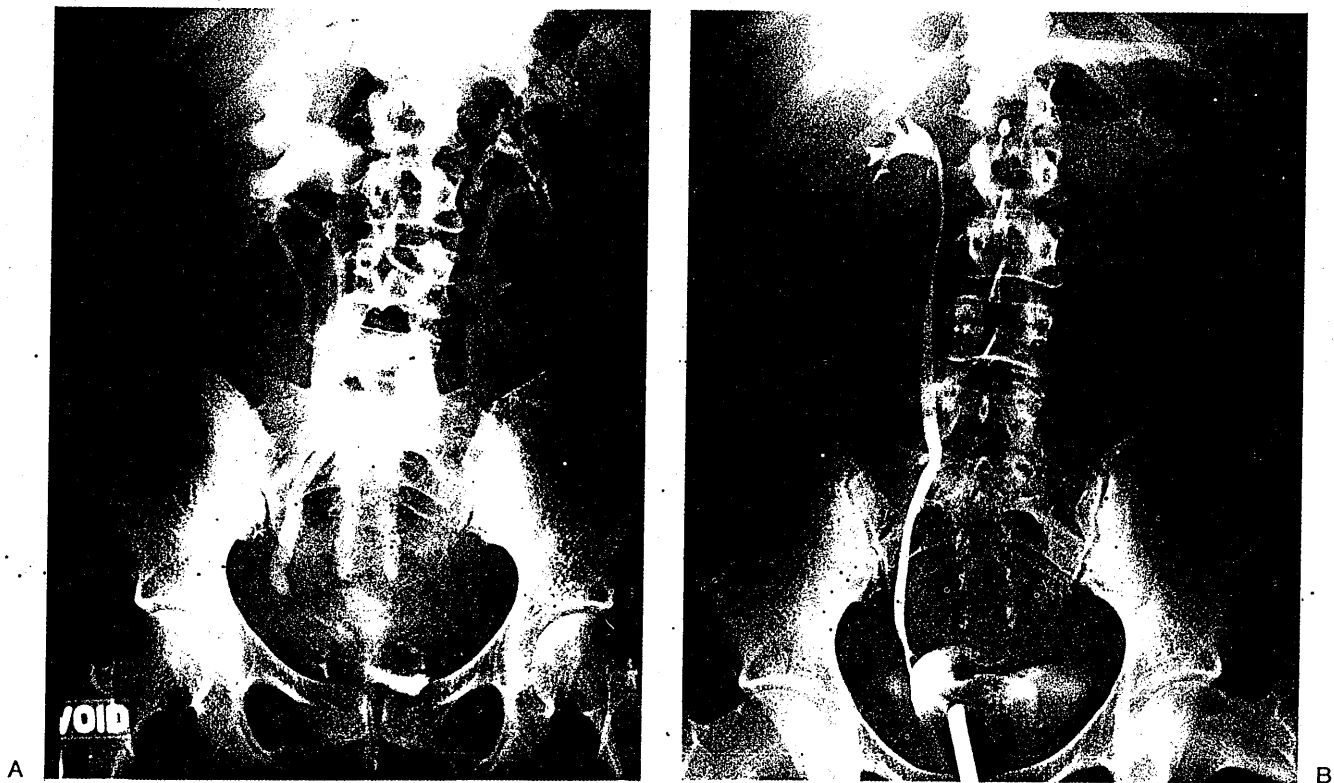
Bladder injuries are more common in patients with severe anterior cul-de-sac endometriosis, previous bladder surgery, and prior cesarean sections, although the most common cause remains bladder distention (12) (Fig. 10). Recently, the laparoscopically assisted vaginal hysterectomy in the hands of the neophyte has also increased the frequency of bladder laceration. Bladder injuries usually can be avoided by placement of a Foley catheter preoperatively and by placement of the secondary puncture site under direct vision. Injury has also been documented from transvaginal placement of the Rubin's cannula into the bladder, and an urachal sinus perforation has also been reported (22,23).

The diagnosis of bladder perforation can be made by the finding of gas in the Foley bag, and it can be confirmed by cystography, retrograde instillation of indigo carmine or methylene blue solution, or cystoscopy. Treatment includes a double-layer, watertight closure with polydioxanone (PDS) (24). Following repair, indigo carmine should be injected in a retrograde fashion to confirm the watertight closure. An indwelling catheter is then left for 7–10 days and the patient is treated with prophylactic antibiotics for a similar period of time. Urologic consultation should be obtained if there is any question regarding the adequacy of management and repair.

### Ureters

Ureteral injury is not common (25). It is usually caused by unipolar or bipolar electrocautery and most commonly occurs near the uterosacral ligaments (Fig. 11A–C). Injury by trocar has also been reported. Injury generally results in ureteral narrowing and hydroureter. This damage can be significant since in one study 3 of 13 patients suffering injury lost renal function and 2 required nephrectomy (25). The diagnosis of ureteral injury is suggested by the presence of flank, pelvic, low back, or abdominal pain as well as fever, leukocytosis, and peritonitis in the early postoperative period (48–72 hr). However, diagnosis may be delayed for up to 3 weeks (12). Increased blood urea nitrogen (BUN) may also occur by urinary contact with the peritoneum. Suspicion of injury should be immediately confirmed by intravenous pyelogram (Fig. 12A, 12B). Treatment with a retrograde or percutaneous stent left in situ for approximately 2 months may be effective, but surgery for resection and reanastomosis of the injured segment of ureter frequently is needed. Urologic consultation is obviously indicated.

Prevention of ureteral injury is most easily accomplished by careful identification of the course of the ure-



**FIG.: 12.** A: Intravenous pyelogram showing a hydroureter and hydronephrosis due to a fistula and stenosis of the right ureter. This followed extensive lysis of right adnexal adhesions and was manifested by fever and abdominal pain. B: A retrograde study in the same patient with ureteral injury.

ter (Fig. 13A-C). This should be done at the initiation of the operative laparoscopy when peristalsis is still active and the peritoneum has not lost its translucency, as occurs in prolonged operative laparoscopy procedures. Special care should be taken to identify the location of the ureter at the pelvic brim and its relation to the infundibulopelvic ligaments, as well as its location with respect to the uterine vessels in the cardinal ligament region. Continued evaluation of the course and location of the ureter throughout the procedure should be performed. Extraperitoneal dissection of placement of catheters may be of assistance. Should any concern be present regarding potential injury, 5 cm<sup>3</sup> of indigo carmine can be injected intravenously by the anesthesiologist. This should appear in the Foley catheter bag within approximately 10 min. Underwater exploration of the ureter for trailers suggesting ureteral injury can then be performed. If suspicion of injury is present, a cystoscopy with placement of an ureteral stent can be performed and/or appropriate intraoperative repair effected. Postoperative diagnosis can be assisted by intravenous pyelography.

### Gastrointestinal Injuries

The reported prevalence of gastrointestinal injury is estimated to be 1-3 per 1000 laparoscopies (12,26)—a rate higher than the 6.2 per 10,000 incidence of bowel penetration extracted from the literature in 1975 by Loffer and Pent (27). The actual occurrence of bowel perforation is unknown and may be somewhat higher, since such injuries may go unnoticed or unreported. Soderstrom personally reviewed 66 cases brought to litigation for bowel perforation after laparoscopy (28).

Of the 20 case reports prior to 1975, 9 represented injuries to the stomach (4 needle-induced and 5 trocar-induced), 5 to the small bowel (3 needle and 2 trocar), and 6 to the colon (4 needle and 2 trocar) (27).

The majority of intestinal injuries are secondary to mechanical trauma. Electrosurgical or laser perforations are relatively rare. Utilizing careful histologic analysis, only 6 of 66 laparoscopic bowel perforations were caused by direct electric desiccation, 2 were the result of defective equipment, 3 were due to operator error, and 1 was a "calculated risk" of extensive adhesiolysis (28).

### Small Bowel

The open technique of laparoscopy may reduce but does not eliminate the risk of bowel injury (28). Small bowel laceration generally occurs with extensive enterolysis for small bowel adhesions (Fig. 14A-C). Injury has been reported in up to 25% of patients undergoing complex operations for small bowel adhesions. Another very common cause of small bowel injury occurs with place-

ment of secondary lower quadrant puncture sites when this is not done under direct vision. Often such injury goes unrecognized. Repair should be carried out with 3-0 or 4-0 silk or PDS on a tapered SH needle (Fig. 14D). At the completion of the repair, sterile milk can be instilled to detect occult perforations. A nasogastric tube is also indicated, and a general surgical consultation should be obtained.

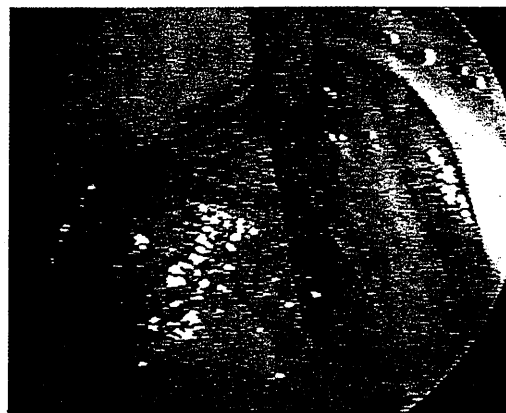
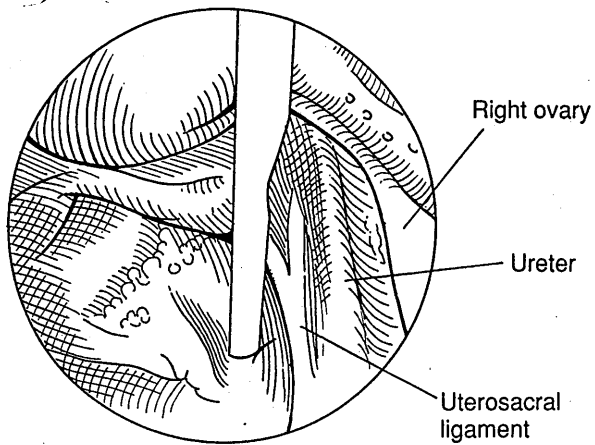
### Large Bowel

Large bowel injury is frequently caused by the Veress needle and probably is often undiagnosed. Diagnosis is made by the presence of foul-smelling gas. Injury to the large bowel from a small hole made by the Veress needle can usually be managed expectantly. Other Veress needle placement sites that can be utilized to avoid bowel injury include the left costal margin in the midclavicular line, lateral to the umbilicus in the midclavicular line, or transvaginally through the posterior cul-de-sac and suprapubically in the midline.

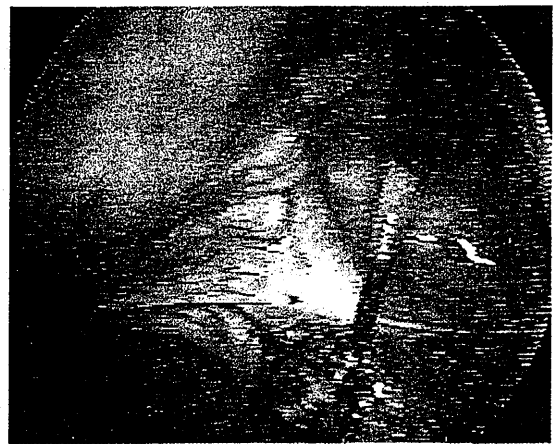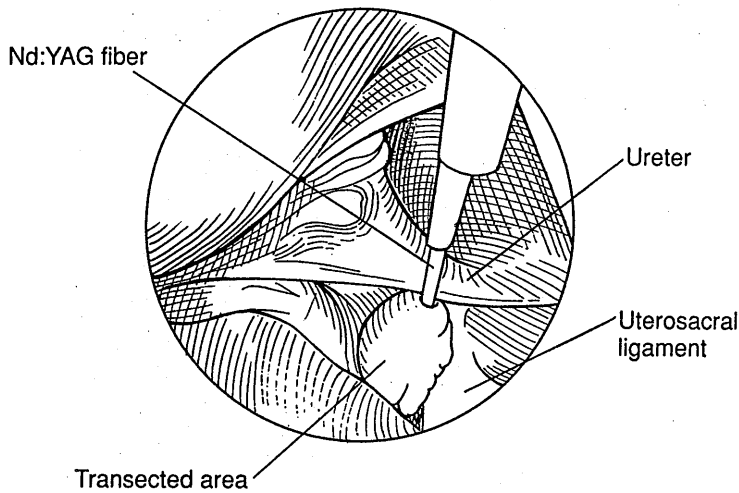
Injury to the large bowel by a trocar may occur when there is complete transfixation of large bowel to the anterior abdominal wall (Fig. 15). This complication is often undiagnosed, and it can only be determined through careful observation through the laparoscope as the laparoscope is entirely removed from the abdominopelvic cavity back through the abdominal wall. Should an injury be diagnosed in this area, the trocar should be left in situ to identify the site of injury while a laparotomy is performed, and double-layer closure with 3-0 or 4-0 PDS or silk performed, or bowel resection and reanastomosis carried out if the extent of injury so merits.

The most common site of large bowel injury is the rectosigmoid. This occurs most frequently as a result of treatment of endometriosis or dense adhesions in the pelvis or from injury with the Veress needle or trocar. Superficial injury may be managed simply by observation (Fig. 16). Deep injury requires surgical repair, preferably in two layers, with 3-0 or 4-0 PDS or silk suture (Fig. 17A,B).

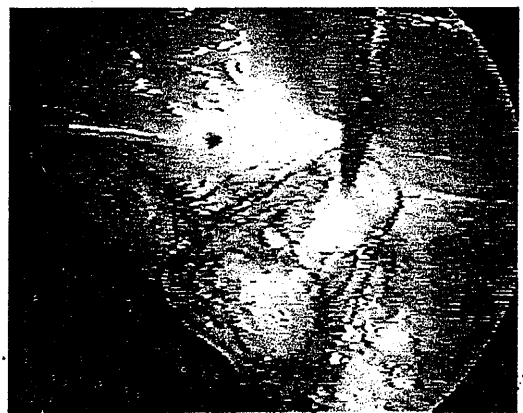
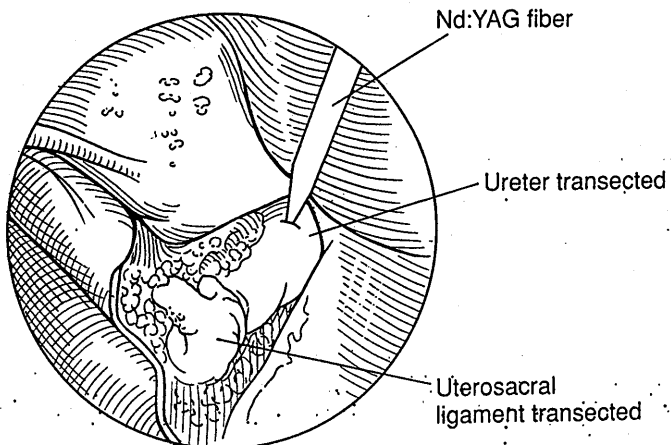
The majority of intestinal injuries are secondary to mechanical trauma (28). However, injury to the large bowel is not uncommon. Superficial thermal injury may be treated by a pursestring suture placed beyond the thermally damaged tissue. However, deep thermal injury requires resection and repair of the damaged tissue in two layers, with 3-0 or 4-0 silk or PDS. The bowel should be checked following repair by placement of a 30-cm<sup>3</sup> Foley catheter in the rectum with clamping of the bowel above the site of repair, followed by injection of a dilute solution of 50% betadine. Underwater exploration documents trailers of iodine antiseptic solution. A 100-cm<sup>3</sup> syringe can also be utilized to inject air into the bowel to look for bubbles and ensure that complete closure has been effected.



A

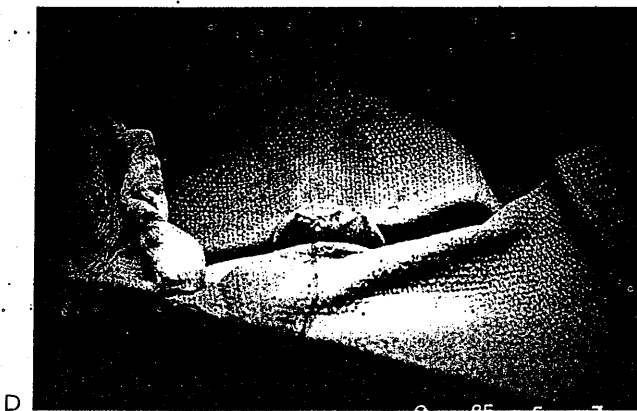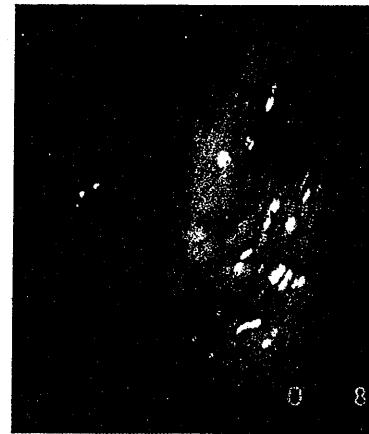
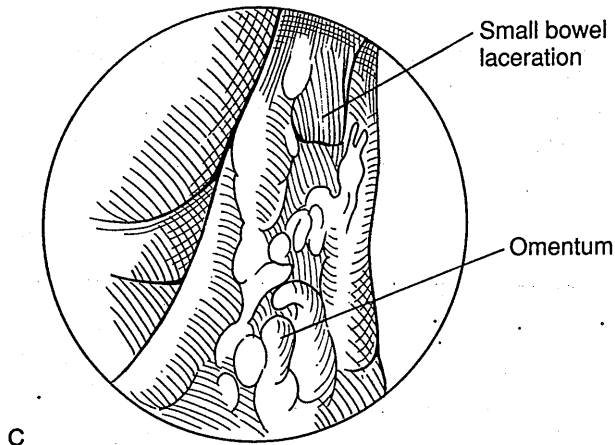
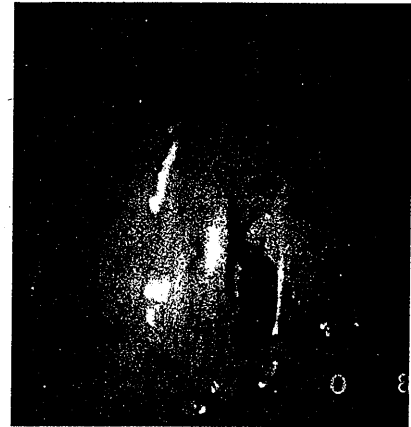
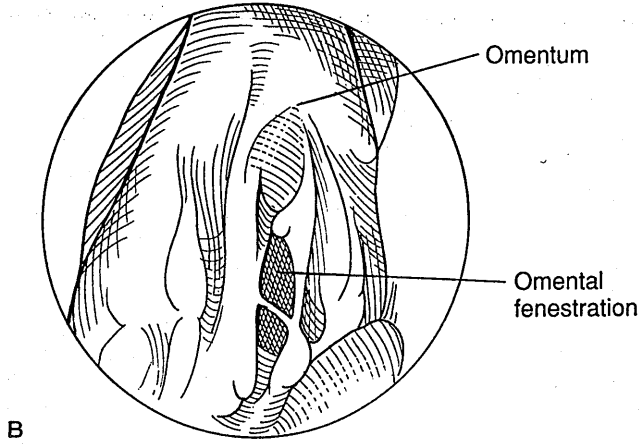

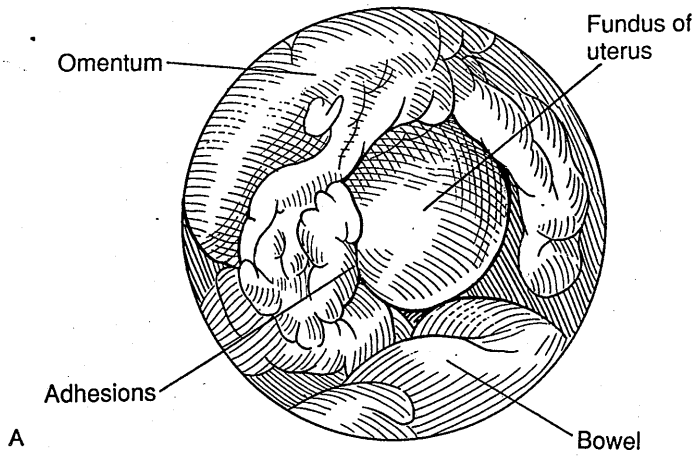


B

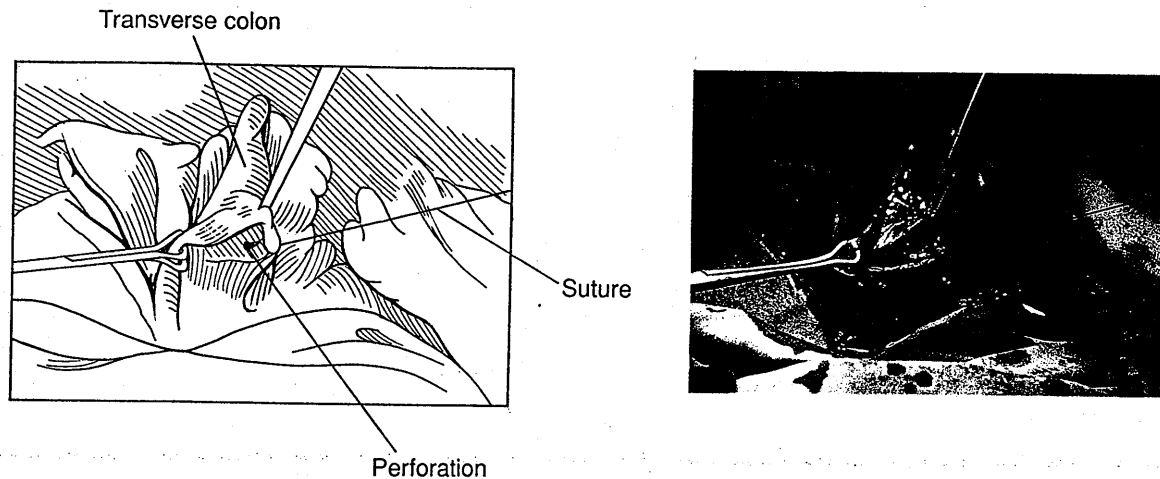


C

**FIG. 13.** A: Close approximation of the ureter to the uterosacral ligament prior to a laser uterosacral nerve ablation (LUNA). B: Transection of the uterosacral ligament and the ureter with the neodymium: yttrium-aluminum-garnet (Nd:YAG) laser fiber. C: Further dissection through the ligament and ureter. The ureter is apparently not noticed by the operator, and the ablation of the uterosacral ligament is carried too far laterally. The patient was subsequently anuric and required ureteral implantation.




**FIG. 14.** A: Omental adhesions with small bowel laceration. In this case, the omentum was adherent to the uterine fundus and pelvis following a previous laparotomy. Because the omentum obscured the pelvic viscera, the risk of injury to bowel or vasculature was increased when the primary or secondary trocars are introduced. B: The omentum was fenestrated with rather blunt scissors without adequate visualization of structures lying behind. C: The small bowel, adherent to the omentum, has been cut. D: A mini-laparotomy was performed and the small bowel was oversewn. The patient was observed in the hospital for 2 days and then discharged.



**FIG. 15.** Trocar perforation of the transverse colon. This patient had a history of an automobile accident and a consequent laparotomy with splenectomy. The colon was adherent to the anterior abdominal wall. Subsequent laparotomy showed essentially no anterior parietal peritoneum and dense adhesions to the entire upper abdominal wall extending 6 cm below the umbilicus. The bowel was oversewn and the patient was discharged in 6 days.

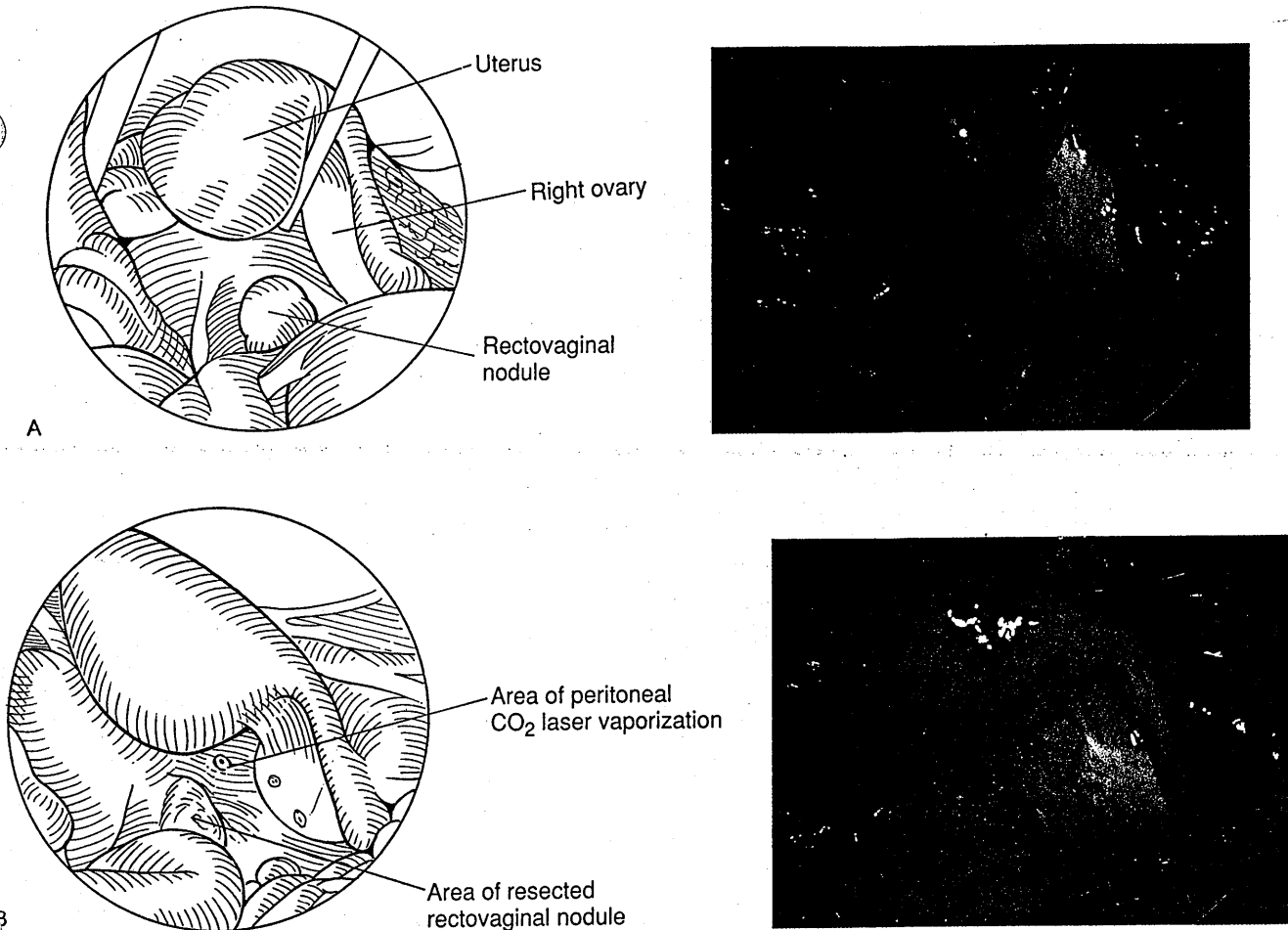
Many patients undergo operative laparoscopy with an unprepared bowel. The decision on the method of bowel repair in this situation depends on the amount of fecal spillage. A large amount of spillage merits laparotomy, whereas a small amount of spillage may be treated by laparoscopic suture and copious irrigation. It may not be necessary to perform a colostomy with bowel injuries associated with laparoscopy. Nevertheless, much greater safety for the patient and comfort for the surgeon can be effected by ensuring that a full-bowel preparation is performed on patients who are undergoing extensive operative laparoscopy, especially those with suspected disease around the bowel (Fig. 18A-D).

It is common for injury to large bowel to go unrecognized intraoperatively. Traumatic injury generally presents with symptoms within 24–48 hr, but electro-surgical injury may not cause symptoms for 4–10 days. The patient then presents with abdominal pain, fever, leukocytosis, and often nausea and vomiting. Delayed symptoms of bowel injury can also occur after perforation of bowel that has been devascularized mechanically or by hemorrhagic ischemic necrosis, although such situations are rare. Treatment of bowel injury after delayed diagnosis requires bowel resection of all necrotic tissue with end-to-end anastomosis, copious lavage, use of antibiotics, and minidose heparin therapy. General surgical and



**FIG. 16.** Serosal burn of the descending colon with the CO<sub>2</sub> laser. The serosa of the colon is grazed with the laser beam during vaporization of endometriosis of the left ovary. No perforation is seen and the patient recovered without event. These patients should be cautioned about signs of peritonitis which can be delayed for as long as 2 weeks after surgery.





**FIG. 17. A:** Delayed peritonitis following CO<sub>2</sub> laser resection of a rectovaginal nodule of endometriosis. Prior to resection, a painful, 2-cm nodule of endometriosis is seen medial to the right uterosacral ligament. **B:** The pelvis is inspected after the nodule has been resected utilizing a sponge stick in the rectum to delineate the rectal margins. Recovery was uneventful until 11 days after surgery, when the patient presented with an acute abdomen. No perforation was seen and peritoneal cultures were negative, but a temporary diverting colostomy was performed. An intraoperative indigo carmine or gastrografin enema may have avoided the colostomy.

other appropriate consultation should be obtained (Fig. 19).

**Stomach**

Stomach injury is usually caused by the Veress needle or laparoscopic trocar. It is especially common following difficult intubations and resultant gastric distention. It can be prevented by use of an orogastric tube. When a stomach injury is recognized through direct visualization of the stomach mucosa, treatment can be effected by leaving the trocar in place and incising over it to produce a minilaparotomy, thereby assisting the identification of the injury site. The stomach can be repaired with a pursestring suture or figure-of-eight suture in a two-layer closure of 2-0 or 3-0 PDS. A nasogastric tube should be left in place for 2 days and appropriate general surgery consultation obtained.

**Subcutaneous and Subfascial Emphysema and Edema**

Emphysema is a common minor complication of operative laparoscopy. Emphysema can occur in the omentum, anterior abdominal wall, space of Retzius, retroperitoneum, or bowel mesentery as a result of inappropriate placement of the Veress needle and/or passage of CO<sub>2</sub> gas through defects created by the instrumentation or surgical procedure (Fig. 20). Such emphysema is rarely of much significance, although it can be of concern to the patient. It generally subsides within a few hours but can be present for a couple of days. It can be recognized in the anterior abdominal wall and even in the thoracic wall through the finding of crepitus. Emphysema involving the face is usually of limited clinical significance because it resolves spontaneously, but patient reassurance is necessary.

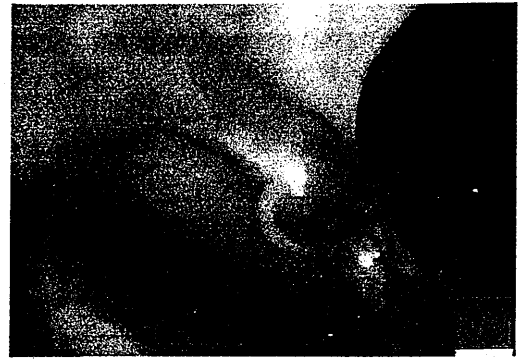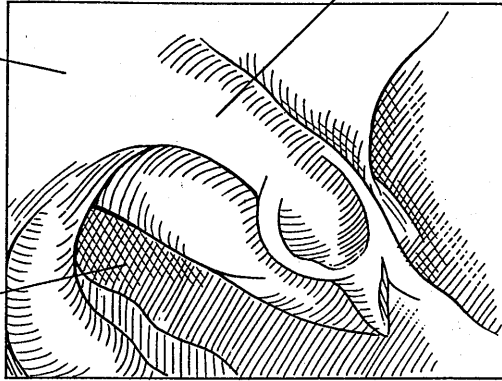
Edema, the presence of fluid in the tissues, occurs in the same location as subcutaneous emphysema, but usu-

Right fallopian tube

Uterus


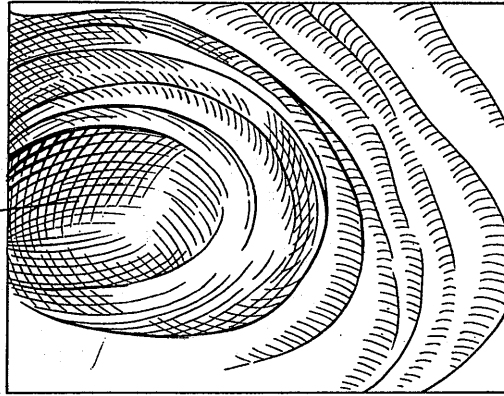
Lumen of large bowel

A



Large bowel lumen

B




Uterus

Bowel defect

Large bowel

Suture

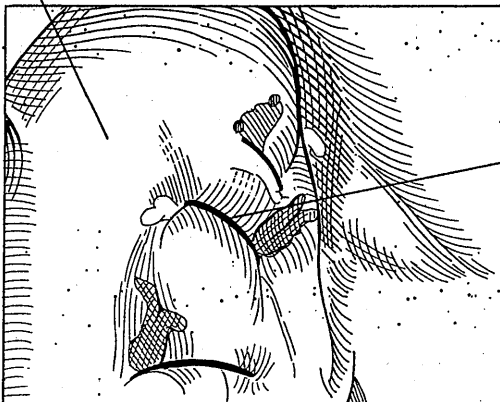C

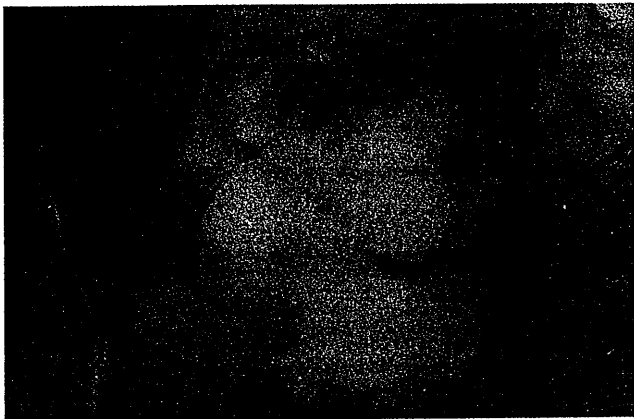


Large bowel


Interrupted sutures

D





**FIG. 19.** Gastrografin enema demonstrating bowel perforation. Five days after extensive cul-de-sac dissection the patient developed right chest pain. Pelvic tenderness was minimal, a white cell count was normal, and free air was seen under the diaphragm on upright x-ray. A computed tomography (CT) scan of the pelvis showed an abnormality in the region of the rectum but no obvious perforation.



**FIG. 20.** Omental insufflation. The omentum has been pierced by the Veress needle and is distended with CO<sub>2</sub>. The bowel is inspected and appears normal, and no omental or mesenteric vessels have been severed.

ally in more dependent areas, especially the flanks and vulva. Subcutaneous edema may occur concurrently with subcutaneous emphysema. Severe vulvar edema may rarely require the placement of a Foley catheter. Fascial edema is proportional to the length of the procedure and the degree of Trendelenburg position, usually resolving within hours after surgery.

### Vasopressin Complications

Vasopressin is a potent vasoconstrictor that can cause hypertension and severe coronary vasoconstriction. It may be used during ectopic salpingostomy and laparoscopic myomectomy. Prevention of complications is facilitated by the use of dilute solutions and by careful injection with aspiration to avoid intravascular injection. The minimum amount necessary should be utilized, and the anesthesiologist should be informed prior to its injection.

### Carbon Dioxide Laser Complications.

A recent study found that only 1.2% of laparoscopic injuries were directly attributable to CO<sub>2</sub> laser use (4). Prevention of CO<sub>2</sub> laser complications includes ade-


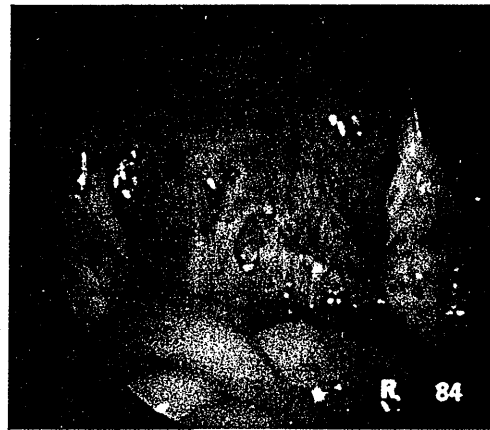
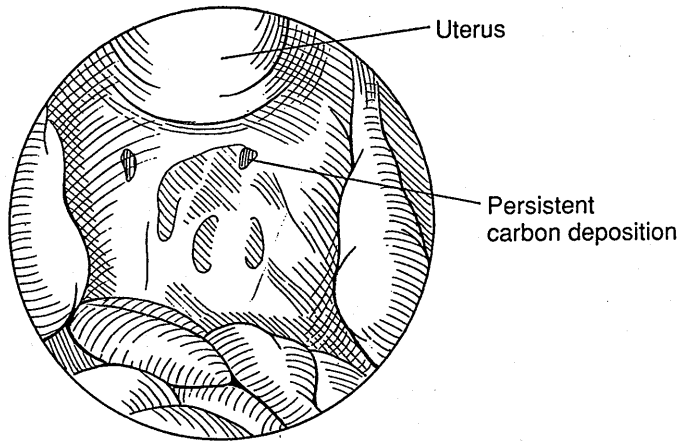
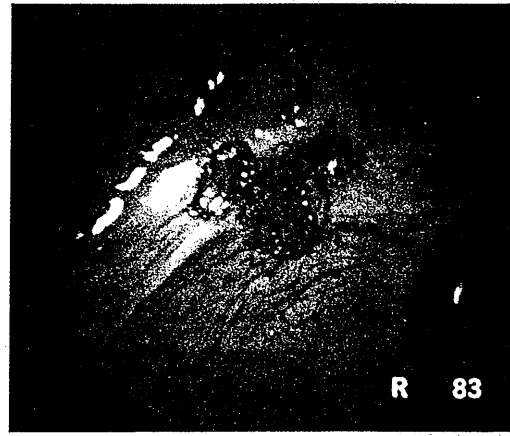
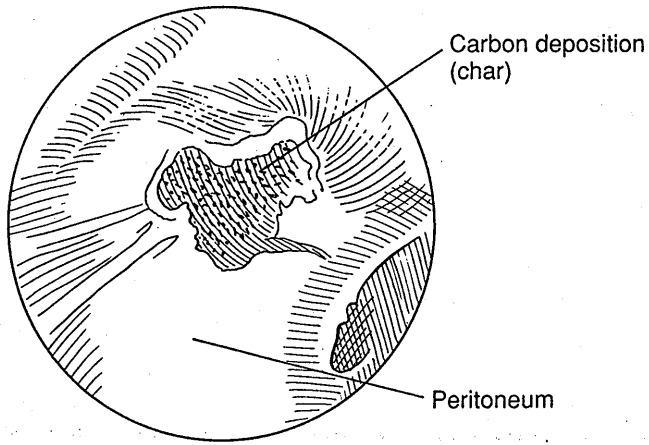
quate training and experience for the surgeon, use of a backstop to prevent the laser beam striking distant tissues, placement of fluid in the cul-de-sac, hydrodissection, and careful observation of the bowel at all times. Care should be taken never to fire the laser unless the HeNe aiming beam can be visualized. Recognition that a blind region occurs out of the field of view of the laparoscope, close to the end of the laparoscope, is mandatory. Carbon particles should be washed off tissue and removed from the pelvis. Currently, there are no known clinically significant sequelae of these carbon particles, but it seems prudent to remove as much carbon as possible (Fig. 21A-D).

### Impairment of Normal Function

Care should be taken to avoid aspiration of the fimbria into the aspiration cannula, grasping of the fimbria, or creation of other thermal or mechanical injury near the fimbria. In the treatment of ectopic pregnancy, intraluminal damage should be minimized. Adhesiolysis should be performed with a view to maintaining the serosa of the fallopian tube as much as possible.

Ovarian adhesiolysis can easily result in injury to the ovarian surface, which tends to form adhesions postoperatively very easily. Ovarian cystectomy should be

**FIG. 18.** **A:** During lysis of dense posterior cul-de-sac adhesions, the large bowel is entered. **B:** An inadvertent laparoscopic colonoscopy is performed, showing excellent results from the patient's preoperative bowel preparation. **C:** The defect is repaired with interrupted sutures laparoscopically. **D:** A watertight seal is created. Less bold endoscopists may choose to repair this type of defect with a minilaparotomy and with the assistance of a general surgeon. The use of a bowel preparation obviated the need for a temporary diverting colostomy.



**FIG. 21. A:** Extensive carbon deposition after CO<sub>2</sub> laser vaporization of endometriosis using low-power densities. **B:** Second-look laparoscopy on the same patient shows persistent carbon. These spots can mimic recurrent endometriosis but may be differentiated by their irregular margins on close inspection under magnification. **C:** Residual carbon produces a foreign body giant cell reaction. **D:** Endometriosis may be hidden behind the carbon and foreign body reaction.

effected with a view to maintaining the maximum amount of normal ovarian tissue. Failure to remove all of the ovarian cyst, and especially an endometrioma, can result in persistence of disease associated with the cysts. Oophorotomy by electrosurgery or laser for treatment of polycystic ovarian disease can potentially lead to ovarian adhesions and should only be performed in highly selected patients. Excessive resection of ovarian tissue, cortical damage, or vascular compromise can potentially result in premature ovarian failure. As a general rule, an ovary should always be conserved unless oophorectomy is absolutely mandatory.

The uterus can be injured at the time of myomectomy. It is important to leave as much uterine tissue as possible when removing leiomyomata. In addition, the uterine cavity should be left intact if possible. Suturing of the myoma site is necessary when large myomas are removed, although adhesion formation will likely be greater.

#### Failure to Complete Procedure

Failure to complete the operative laparoscopy procedure can result in inadequate treatment for the patient. The patient should always be counseled preoperatively regarding the potential necessity of laparotomy. Laparotomy should be performed to complete the operation when necessary to obtain the optimum result for the patient. Different surgeons have different skill levels and different thresholds for performing a laparotomy. Performance of a laparotomy by itself does not constitute a complication, but the surgeon and the patient need to understand preoperatively that such an outcome may be necessary to obtain the optimal surgical result. Patients with extensive pelvic adhesions or endometriosis and who have infertility as their only symptom are often best treated with in vitro fertilization (IVF), therefore avoiding the risks of complex pelvic surgery.

### EARLY POSTOPERATIVE COMPLICATIONS

#### Abdominal Pain

Early postoperative complications include abdominal pain. This can be minimized by using the smallest possible abdominal incisions, ensuring careful closure with hemostasis of the abdominal wounds, placing 0.25–0.5% bupivacaine into the wound margins at the completion of the surgery, and avoiding abdominal overdistention. Abdominal pain as a result of postoperative ileus can be reduced through the use of preoperative bowel preparation. Postoperative analgesics are appropriate to help manage pain.

#### Shoulder Pain

Shoulder pain, in particular on the right side, may be the result of diaphragmatic stimulation of C4 as a result of gas or air left intraabdominally. The CO<sub>2</sub> gas should be expelled at the termination of the procedure through pressure placed on the abdominal wall. Shoulder pain, when it occurs, can be quite severe and last for several days. Assumption of the knee-chest or Trendelenberg positions can "float" the bubble of gas away from the diaphragms and afford immediate relief.

#### Neurologic Injury

Neurologic injury can occur postoperatively from injury to the peroneal nerve as a result of pressure on the lateral aspect of the knee and lower leg. This results in foot drop and paresthesias. This condition is generally self-limiting over a period of several days. It can be avoided by proper positioning of the patient, use of well-designed stirrups, and avoidance of pressure on the lateral aspect of the lower limbs. In addition, the legs can be exercised by the operating room staff approximately every 2 hr during the operation.

Sciatic nerve injury can occur from inappropriate placement of the patient on the operating room table. Brachial nerve injury can occur from the use of shoulder braces and can be a very significant complication. This can be avoided by not using these braces but using pads underneath the patient and/or a Trendelenburg position that is not quite as steep. Femoral nerve injury can occur as a result of extreme flexion, abduction, and lateral rotation of the hip joint. This can also be prevented by careful patient positioning (29).

#### Urinary Retention

Postoperative urinary retention can occur in cases lasting longer than 2 hr, especially when large volumes of intravenous fluids have been administered. Prevention of this problem can include the delay of Foley catheter removal until the patient is awake and aware of the catheter, which occurs approximately 1–2 hr after completion of the operation. In selected situations, the patient may receive bethanechol chloride (Urecholine) 25 mg. If the patient has not voided by 4 hr postoperatively, she can be straight-catheterized and treated again with bethanechol chloride 25 mg (24) or observation.

#### Infection

Infection is not a common postoperative complication with operative laparoscopy. Nevertheless cystitis and uri-

nary tract infection can occur and should be diagnosed and treated in a standard fashion. Peritonitis and abscess are extremely uncommon and most often associated with bowel injury. Pelvic infection is similarly very uncommon. Cellulitis and infection in the abdominal wall can result in pain, swelling, and erythema. This should be treated by warm compresses, drainage, and appropriate antibiotics. Pneumonia is rare and should be treated in the usual fashion.

Prevention of infection can be enhanced by the use of appropriate sterile technique, appropriate sterilization of instruments, and prophylactic antibiotics. One regimen utilizes doxycycline 100 mg by mouth the night prior to surgery and 100 mg intravenously at the initiation of surgery. It should be noted that contamination of the peritoneal cavity occurs 90% of the time with hydrotubation (30). Nevertheless, infection is uncommon in the abdominal cavity. Copious lavage at laparoscopy also reduces the risk of infection. It is also important not to perform an unnecessary appendectomy, especially in young patients desiring future fertility, since such procedures occasionally result in pelvic infection and reduction in fertility.

#### Other

Other early postoperative complications include fluid overload and pulmonary edema, as well as urinary retention, incisional hematoma, and vulvar edema. Drug allergies can occur in any patient and should be treated in a standard fashion.

#### LATE POSTOPERATIVE COMPLICATIONS

Late postoperative complications include bowel injury and pelvic abscess. Uterine rupture may occur at the time of subsequent pregnancy if large defects have been left in the uterine wall. Ectopic pregnancy also is a potential complication of reconstructive tubal surgery. Intrauterine or ectopic pregnancy is a complication of tubal ligation. Dissemination of cancer may result from inappropriate management of adnexal masses; guidelines for management of adnexal masses should be followed carefully to prevent this problem. Psychological complications may occur rarely in selected patients who have not been appropriately selected for surgery.

Incisional hernias can occur following operative laparoscopy. Omental herniation is possible (31), and herniated tissue may become incarcerated (32, 33). Hernias usually occur more than 7 days postoperatively, although they have been reported earlier. Prevention includes the use of a Z track with placement of large instruments, the use of smaller trocars whenever possible, shaking of the abdominal wall or passage of a probe at the end of surgery to drop bowel or omentum out of in-

cisions, and the placement of fascial sutures with the aid of skin hooks through skin incisions greater than 7 mm.

#### HIGHLIGHTS

It is clear that operative laparoscopy has brought many benefits to our patients. Nevertheless these operations are associated with complications that may cause significant morbidity or even mortality. It is imperative that we as surgeons become well trained before attempting operative laparoscopy. Most complications occur in a surgeon's first 50 cases. There are fewer complications after 200 cases. Experience can only be gained slowly, and it is incumbent on each surgeon to attempt only procedures for which he or she is technically competent.

The most important decision for surgeons to make to reduce complications is whether or not to operate. The decision to perform surgical procedures should not be influenced by personal, psychological, financial, or other professional needs, or be unduly influenced by the referring physician or patient. In addition, surgeons should not be unduly influenced by literature results or other surgeons' anecdotal experiences. Each surgeon must understand his or her own unique set of skills and weaknesses and develop enough rapport with each patient to understand and respect the uniqueness of the clinical situation.

By doing this, surgeons will be able to exercise good judgment and not violate basic surgical principles, while modifying each surgical decision to optimize the benefit for the patient and to minimize the risk of complication. Avoidance of complications is possibly the most critical factor in creating benefit for our patients once the decision to operate has been made. Awareness of potential complications is necessary to avoid them, diagnose them early when they occur, and manage them appropriately to minimize their sequelae.

#### REFERENCES

1. Hulka JF, Soderstrom RM, Corson SL, et al. Complications Committee of the American Association of Gynecologic Laparoscopists: first annual report. *J Reprod Med* 1975; 10:301-306.
2. Peterson HB, Hulka JF, Phillips JM: American Association of Gynecologic Laparoscopists 1988 membership survey on operative laparoscopy. *J Reprod Med* 1990; 35:587-589.
3. Hulka JF, Peterson HB, Phillips JM, Surrey MW. Operative laparoscopy. American Association of Gynecologic Laparoscopists 1991 membership survey. *J Reprod Med* 1993; 38:569-571.
4. Diamond MP, Daniell JF, Feste J, et al. Initial report of the carbon dioxide laser laparoscopy study group: complications. *J Gynecol Surg* 1989; 5:269-272.
5. Lehmann-Willenbrock E, Riedel H-H, Mecke H, Semm K. Pelviscopy/laparoscopy and its complications in Germany, 1949-1988. *J Reprod Med* 1992; 37:671-677.
6. Method MW, Keith CG. Economic impact of gynecologic endoscopy. In: Sanfilippo JS, Levine RL eds. *Operative gynecologic endoscopy*. New York: Springer-Verlag; 1989.
7. Tokars JI, Bell DM, Culver DH, et al. Percutaneous injuries during surgical procedures. *JAMA* 1992; 267(21):899-904.