

sept 1996

A new approach to performing laparoscopic colposuspension

By Ceana H. Nezhat, MD, Michael Roemisch, MD, Daniel S. Seidman, MD, Farr Nezhat, MD, and Camran Nezhat, MD

According to the National Institutes of Health, one fourth of American women experience temporary or long-term urinary incontinence.¹ Two thirds of these women suffer from genuine stress urinary incontinence, defined as the spontaneous and involuntary passage of urine from the bladder after such physical strain as coughing, laughing, or lifting.² As life expectancy increases, the number of postmenopausal women continues to grow. This shift implies a higher prevalence of stress urinary incontinence, because the disorder primarily affects postmenopausal women.^{3,4} Moreover, with social changes emphasizing activity in older people, stress urinary incontinence becomes increasingly inconvenient.

Although this condition can be treated effectively by surgery, it seems that relatively few women seek treatment. This reluctance may be attributed in part to the fact that stress urinary incontinence is not life-threatening and may be regarded as an inconvenience rather than a "real" disease that justifies the risks associated with surgery. Also, many people are embarrassed

Treating stress urinary incontinence improves a woman's quality of life. Laparoscopic correction, which reduces the drawbacks associated with open surgery, may encourage more women to obtain relief.

to raise the subject of incontinence. Experience shows that while many women do not broach the subject with their gynecologist, they will discuss it if they are questioned. Furthermore, they appreciate instruction and information. For this reason, questionnaires are very helpful because they offer patients

Drs. Ceana, Farr, and Camran Nezhat and Dr. Seidman are at the department of gynecology and obstetrics, Stanford University School of Medicine, Stanford, Calif. The Drs. Nezhat and Dr. Roemisch are also at the Center for Special Pelvic Surgery, Atlanta, Ga. and Palo Alto, Calif.

the opportunity to address the symptoms at their discretion.

Two measures commonly used by patients with stress urinary incontinence are avoiding strenuous activities and wearing sanitary pads. Unlike women with urge incontinence, those with stress incontinence usually can predict and will avoid situations that may cause urine leakage. If this is not possible, they use sanitary pads, the more sophisticated of which acidify and gelatinize urine, to eliminate wetness and odors. This strategy, however, limits activity and interferes considerably with quality of life.

The same problem is true of behavioral techniques, which are increasing in popularity. The concept is to strengthen the pelvic floor by regular exercise. The simplest form are Kegel's exercises—contractions of the pelvic floor muscles performed several times per day. More complex techniques use cones of increasing weight that are retained in the vagina, or electrical devices for biofeedback or neurostimulation. However, the effectiveness of such approaches is usually limited to younger women with uncomplicated histories and mild descensus



TABLE 1

Bladder neck suspension performed by two procedures

Procedure	Laparotomy	Laparoscopy
Anesthesia	General or regional	General or regional
Incision	Large	Small
Exposure (space of Retzius)	3-D, tactile palpation	2-D, excellent exposure due to magnification and superior illumination, better hemostasis
Suturing	Additional experience not necessary	Intracorporeal suturing demands more experience, stapling experimental
Short-term results	90% success	90% success
Long-term results	80%-90% success	Not available

(unpublished data). Initially, most women report they benefit from pelvic floor training, but objective assessments show that this is often a psychologic effect, probably due to a change in the sensory input from the pelvis.⁵⁻⁸ Over time, compliance with pelvic floor exercises, which need to be performed regularly to be effective, gradually diminishes. These comments are not intended to discredit behavioral techniques. Because they have no undesirable side effects, and do not involve irreversible procedures, behavioral techniques should always be considered first in treating stress urinary incontinence. However, the patient should understand the limitations of this approach.

The goal of surgical treatment is restoring the bladder neck to its original position by fixation, and protection or augmentation of the intrinsic sphincter competence (Table 1).⁹ Vaginal repair was one of the first surgical procedures

performed, and remains one of the most common.¹⁰ Although vaginal repair is useful to correct descensus, its effect on the bladder neck, and subsequently on urinary incontinence, is limited.^{11,12} Operative success is also short-lived, and the failure rate correlates directly with postoperative time.¹³ Vaginal repair, therefore, is recommended only for the treatment of mild forms of stress urinary incontinence combined with descent, and in the presence of good urethral closure pressure.¹⁴ The limited role of this procedure can be attributed to the deficient anatomic properties of the endopelvic fascia, which is used for vaginal repair. It is neither located sufficiently above the level of the bladder neck nor is it firm enough to guarantee long-term success.

Other procedures use autologous or heterologous material to elevate the urethra with a sling, commonly inserted in the rectus fascia. This

technique is very effective and is applied primarily to specific conditions, such as low urethral closure pressure, recurrent stress urinary incontinence, or sphincter deficiency. One disadvantage, however, is the relatively high postoperative complication rate caused by the manipulation of the bladder neck. Persistent micturition problems, reduction in the maximum bladder filling capacity, and induction of urgency are among the most frequent side effects of the procedure and restrict its application.¹⁵⁻¹⁷

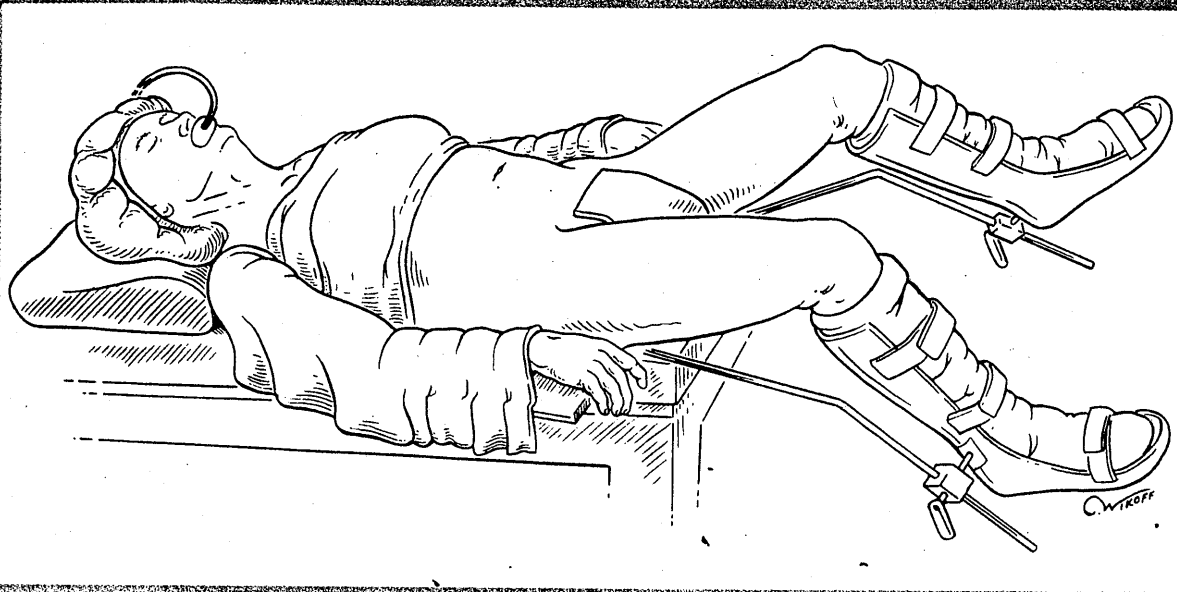
Most of the disadvantages we have mentioned have been overcome by the surgical technique reported in 1949 by Marshall, Marchetti, and Krantz, which is still the gold standard for treatment of stress urinary incontinence.¹⁸ By suturing the bladder neck to the posterior wall of the symphysis pubis, abdominal colposuspension achieves overall cure rates of approximately 80% to 90%.^{19,20} Long-term results are good.^{21,22} Postoperative complications such as urgency or micturition problems occur in fewer than 20% of patients.^{23,24} Numerous modifications and improvements allow application of the procedure for different indications.

The Burch procedure, first reported in 1961, is the modification used most frequently.²⁵ In contrast with the original procedure, the fixation sutures are placed in Cooper's ligaments, instead of the posterior symphyseal wall, and in the paraurethral vaginal wall instead of the bladder neck. Therefore, periostitis, which other-

This

Many phy
American
greater ris
estrogen l
is as well

FIGURE 1



The patient is placed in a modified dorsal lithotomy position in Allen universal stirrups.
Source: Nezhat CR, et al.⁴³

wise occurs in about 5% of all cases, is avoided, coexisting mild vaginal descent can be reduced, and the very sensitive functional bladder neck unit remains intact.^{18,26}

Drawbacks of the original Marshall-Marchetti-Krantz abdominal colposuspension include several days of hospitalization because of the broad abdominal Pfannenstiel incision, and the limited reduction in coexisting vaginal descensus. These problems led to the introduction of vaginal colposuspension in 1959 by Pereyra, using specially designed needles to lead threads, which are fixed in the vagina by paraurethral sutures. The knots are tied retropubically to the abdominal wall, in front of the rectus muscle.²⁷ The Pereyra procedure eliminates the abdominal incision, corrects coexisting vaginal descensus without repositioning the patient, and requires little, if any, hospitalization time.²⁸ The Pereyra procedure was

modified to overcome certain technical shortcomings mainly due to sutures bursting out of fibrous tissue. The most common modifications are the Stamey and Raz procedures.^{29,30} However, long-term follow-up studies suggest that recurrence is considerably more frequent after vaginal needle suspension than after abdominal procedures.³¹⁻³⁴ In an attempt to combine optimum therapeutic safety and lasting long-term results with minimal invasiveness and short hospital stays, the laparoscopic retropubic colposuspension was introduced by Vancaillie in 1991. Access to the retropubic structures involves only one small umbilical incision, and small incisions in the lower abdomen, through which endoscopic instruments are placed preperitoneally in the space of Retzius.³⁵ The need for a broad Pfannenstiel incision is eliminated. Short-term follow-up indicates that postoperative success

rates are equivalent to those of abdominal colposuspension.³⁶⁻³⁸

Authors' experience

Included in our study were 72 women, between 34 and 70 years of age. Genuine stress urinary incontinence was diagnosed using history, symptom diary, clinical stress test in lithotomy and standing position, and Q-tip test.³⁹ Only women with leakage during stress testing were included in the study. Problems of detrusor instability, bladder outlet obstruction, and hypotonic urethra were excluded in a urodynamic suite by preoperative complex multichannel cystometrography, pressure-flow study, and resting urethral pressure profile.^{40,41}

Following the induction of general endotracheal anesthesia, the patient's legs were placed in Allen stirrups, which permitted the assistant to perform a vaginal examination and to elevate the bladder neck (Figure 1). A Foley balloon

study comparing
300 mg/day.
the clinical signific
References: 1. Bric
on antiinflamm
ciprofen, and ac
the results of the
Robert FA. Furey
Laproxen and n
1974; 7: 185.
The advice pati
The success of the
Patrick Robins

LAPAROSCOPIC COLPOSUSPENSION

TABLE 2
Additional procedures

Procedure	Patients (No.)
Laparoscopic hysterectomy	39
Removal of adnexa	20
Removal of endometriosis or adhesions	16
Moschcowitz procedure	16

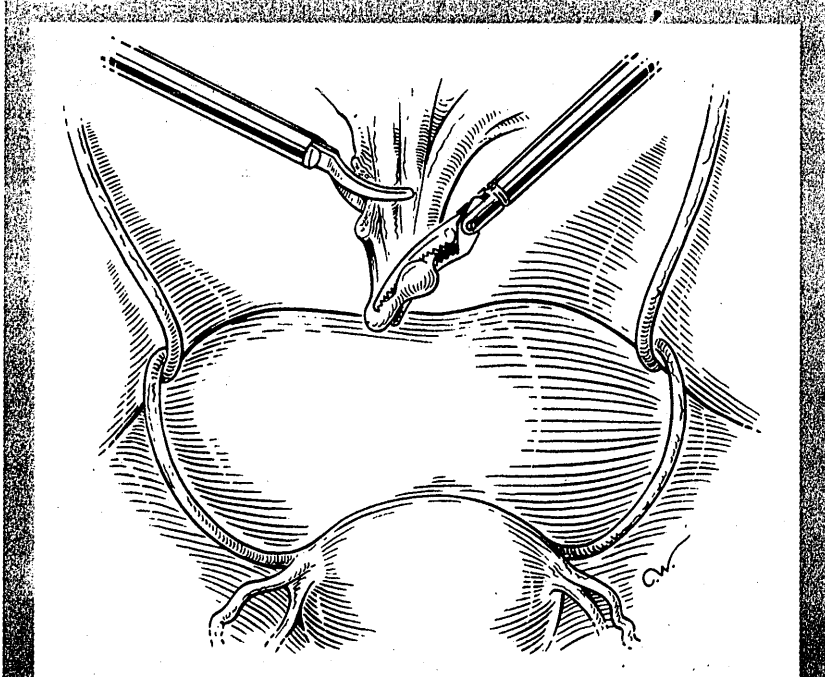
through the operative channel of the 10-mm laparoscope, which was inserted via an infraumbilical trocar. Three 5-mm trocars were positioned in the lower abdomen to introduce ancillary instruments, including the suction irrigator probe, grasping forceps, needle holder, and bipolar forceps.^{42,43} First, we inspected the intraperitoneal cavity and performed any indicated additional procedure (Table 2).

A modified Moschcowitz procedure was performed in all women

was used, beginning at the bottom of the cul-de-sac and exercising care to incorporate the posterior wall of the vagina, only peritoneum laterally at the left and right pararectal area, and only shallow bites of serosa over the anterior rectosigmoid colon. In patients with previous hysterectomy, any remnant of uterosacral ligaments is included in the suture. Closure of the cul-de-sac should leave no defect that could result in bowel entrapment.

The space of Retzius was entered using one of two methods. In the first, a transverse peritoneal incision was made above the bladder (Figure 2).³⁸ With the second method, the mid suprapubic cannula was withdrawn into the preperitoneal area. A 16-gauge laparoscopic needle was inserted through the mid suprapubic cannula. Approximately 30 to 50 mL of dilute vasopressin (10 units in 100 mL of Ringer's lactate solution) were injected subperitoneally in the lower anterior abdominal wall above the bladder to decrease oozing. The needle was replaced with a suction-irrigator probe. Hydrodissection was performed with the suction-irrigator probe by injecting 300 to 500 mL of lactated Ringer's or normal saline, to form a preperitoneal space in the anterior abdominal wall. The videolaparoscope was retracted from the abdominal cavity and directed towards the newly created subperitoneal space. A long hydrodissection probe was inserted through the operating channel of the laparoscope into the subperitoneal space under direct observation. The

FIGURE 2



An incision is made in the peritoneum 3 to 5 cm above the symphysis pubis.

catheter was inserted to mark the bladder contour and the urethrovaginal junction. The carbon dioxide (CO₂) laser was placed

with a deep pelvic well to obliterate the cul-de-sac.⁴³ A laparoscopic pursestring suture of 1-0 polybutyrate-coated polyester (Ethibond)

space was expanded further using hydrodissection. The videolaparoscope was advanced into this space, which was insufflated with CO₂. The lateral suprapubic trocars were retracted to the preperitoneal space.

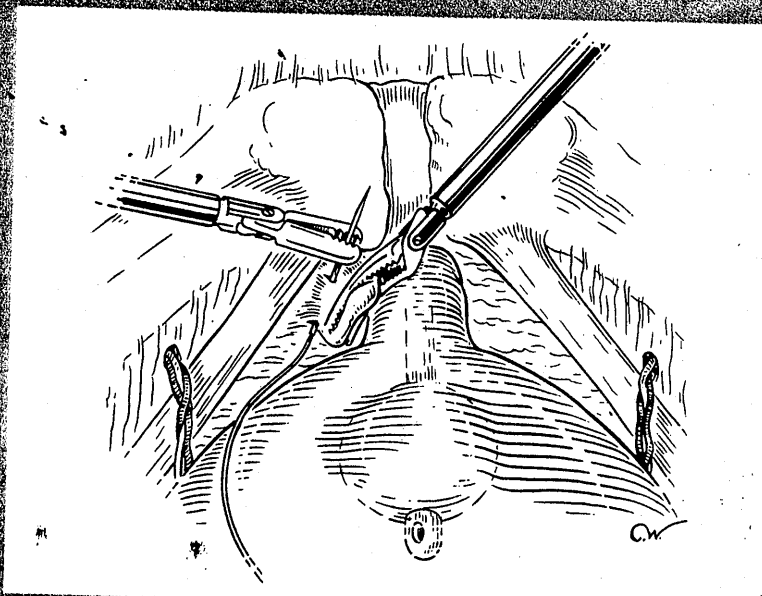
Blunt and occasionally sharp dissection was required to lyse adhesions that remain after hydrodissection. At this point, the symphysis pubis and Cooper's ligaments were exposed. The patient was placed in deep Trendelenburg position and rotated left to facilitate left-handed suture placement. Fibrofatty tissue in the exposed space of Retzius was meticulously excised and removed from the pubic bone, usually by a form of "liposuction" using the suction-irrigator probe and grasping forceps. The paravaginal fascia was identified. Using an atraumatic grasping forceps, a bite of the paravaginal fascia was elevated and a suture of 1-0 polybutylate-covered polyester (Endoknot) was placed at the level of the urethrovesical junction, approximately 1 to 1.5 cm from the urethra (Figure 3). The assistant's finger was used as a guide. This was facilitated by placing the bulb of the Foley catheter under gentle traction. The suture was placed perpendicular to the vaginal axis to include approximately 1 to 2 cm of tissue (the complete vaginal fascia), but not the vaginal mucosa. The suture was fixed to Cooper's ligament.

The sutures were tied intracorporeally or extracorporeally with help from an assistant who performed a vaginal exam and lifted the vagina upward and forward.⁴³ Direct visualization allowed the

surgeon to gauge the tension in the vaginal wall while tying the sutures. The urethra was observed to ensure it was not compressed against the pubic bone. This suturing was repeated on the opposite side to create a platform on which the bladder neck rests, while avoiding cinching (Figure 4). If the sus-

women, there was no peritoneal incision. In 22, the peritoneal defect had enlarged and was closed with several sutures; in 40, it was left open to heal spontaneously. Pneumoperitoneal pressure was decreased and the retroperitoneal space thoroughly evaluated. Bleeding was controlled with bipolar electrodes-

FIGURE 3



A 1-0 polybutylate-covered polyester suture is placed 1 to 1.5 cm from the urethra. The assistant's finger is used to elevate the paravaginal fascia and guide the surgeon.

pension was judged inadequate by visual inspection, manual elevation, or cystoscopy, a second set of sutures was placed cephalad along the base of the bladder.

Cystoscopy was performed to ensure that no suture material was in the bladder, and to assess the urethrovesical junction angle and urethral patency. In ten

icitation. The laparoscope was withdrawn from the abdomen and the procedure completed.

Except in cases of cystostomy, the Foley catheter was discontinued the following day. Postvoid residual volume was evaluated, and if it exceeded 100 mL, the patient was instructed in self-catheterization, which was performed until the vol-

ume was less than 100 mL. Preoperatively, all women received prophylactic, intravenous second-generation cephalosporin. Women who required self-catheterization

der perforation during dissection of the space of Retzius. It was repaired laparoscopically. Postoperatively, one patient developed an incisional hernia at a 10-mm midline trocar

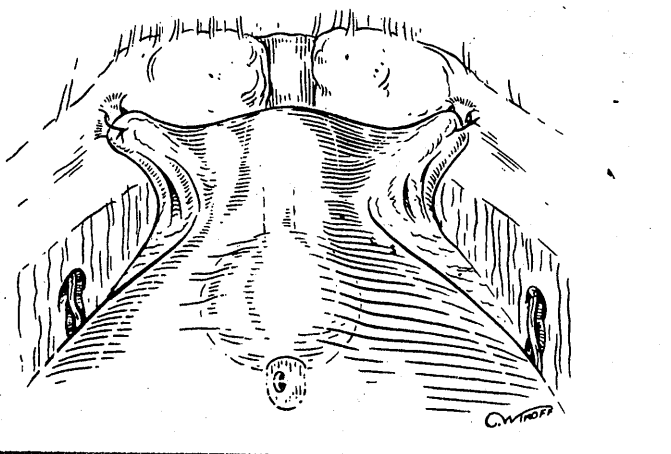
and bladder retraining. One patient, whose incontinence did not improve postoperatively and who had a normal evaluation, experienced total resolution of her symptoms by taking flavoxate (Urispas). At evaluation 11 months later, she remained continent.

The estimation of postoperative success was based on a follow-up time between 3 and 30 months implementing subjective and objective criteria of improvement. Subjective success was determined by questionnaire about urinary leakage and the absence of need to wear pads. Objective success was assessed by comparing preoperative and postoperative symptom diaries, urinalysis, postvoid residual volume, Q-tip test, and stress test. Of the group, 67 (93.1%) reported satisfactory relief of their incontinence. Five were initially leaking and used sanitary pads but responded eventually to conservative treatment.

Criteria for success

Laparoscopic colposuspension is more than just one of many surgical corrections of urinary incontinence. The principles of the original abdominal Burch procedure, the most successful surgical treatment of stress urinary incontinence, were always followed.^{22,27} The drawbacks of a broad abdominal incision, however, such as postoperative pain and longer hospitalization and recuperation times, were avoided. We believe that an experienced laparoscopic surgeon may achieve precision superior to that of open surgery, because the magnifying

FIGURE 4



The suture is tied extracorporeally or intracorporeally, and elevates the ureterovesical angle.
Source: Nezhat CB, et al.⁴³

took oral antibiotics until catheterization was discontinued. Postoperatively, women were instructed to avoid heavy lifting or strenuous exercise for at least 2 months. Follow-up visits were scheduled at 2 and 6 weeks postoperatively.

There were no conversions to laparotomy. The operative time of the colposuspension alone ranged from 30 to 70 minutes, and estimated blood loss was between 10 and 300 mL. Most patients left on postoperative day 2. The postoperative hospital stay ranged from 19 to 93 hours, and was affected by additional surgery.

The 93-hour postoperative stay was for a woman who had a blad-

der perforation during dissection of the space of Retzius. It was repaired laparoscopically. Postoperatively, one patient developed an incisional hernia at a 10-mm midline trocar

incision used to insert an Endobag for adnexa removal. The fascia had been repaired by an absorbable suture. The hernia was repaired on an outpatient basis and 8 weeks later the patient was asymptomatic. Four women required intermittent self-catheterization following removal of the Foley catheter; in one case, it was necessary for 10 days. Temporary symptoms of urgency and dysuria occurred in 27 patients and responded to spasmolytic and analgesic medication. No febrile morbidity was noted. Four women developed postoperative de novo detrusor instability, which was confirmed by repeat urodynamic testing and responded to oxybutynin

Two multicenter studies compared Macro-
Macrodantin® (nifedipine
macrocystals) 50 mg
post-treatment, clinical improvement
90-93% across treatment groups
rates of bacteriologic
counts <10⁴ CFU
uropathogen were
evaluated 7-10 d
bacteriologic rates

Please see prescription
on next page.

quality of the laparoscope enhances observation of the space of Retzius.

Our short-term success rate of better than 90% confirms this assumption. The complication rate was well within the range expected for the Burch procedure, or lower. To avoid postoperative enterocele, a recognized sequela of the Burch procedure reported in up to 26.7% of all patients, the criteria for a Moschcowitz procedure should not be applied too strictly.⁴⁴ De novo detrusor instability occurred in 8% of our study population. This is lower than the rate of 18% described for laparotomy.²³ The difference may be attributed to the more meticulous dissection and hemostasis in the sensitive area surrounding the bladder neck. However, our series is too small to make a definitive statement.

Bladder neck suspension consists of two major steps: exposure of the space of Retzius and suturing the paraurethral vaginal wall to the Cooper's ligaments. Regarding the first part of the procedure, we believe the laparoscopic dissection and hemostasis, combined with the magnification and illumination provided by the laparoscope, result in a superior exposure of the Retzius space. We perform the second part of the procedure by placing the suture in a manner similar to the way the Burch procedure is performed at laparotomy. We expect the long-term results to be at least comparable with those achieved at laparotomy. Currently, such techniques as stapling are being investigated to replace suturing. Although these techniques require less surgical ex-

perience than intracorporeal knot tying, their long-term results have not been determined.

The successful treatment of stress urinary incontinence can considerably improve the quality

**An experienced
laparoscopic
surgeon may achieve
precision superior to
that of open surgery,
because the
magnifying quality
of the laparoscope
enhances
observation of the
space of Retzius.**

of life of affected patients.⁴⁵ Reducing the drawbacks associated with colposuspension by laparotomy may encourage women to obtain relief from urinary incontinence through laparoscopic correction. Investigations are underway to further evaluate this promising laparoscopic approach. □

REFERENCES

1. National Institutes of Health: Urinary incontinence in adults, National Institutes of Health Consensus Development, 1988;7(5):1
2. Abrams P, Blaivas JG, Stanton SL, et al: Standardization of lower urinary tract function recommended by the International Continence Society. *Int Urogynecol J* 1990;4:5
3. Osborne JL: Postmenopausal changes in micturition habits and in urine flow and urethral pressure studies. In Campbell S, *The Management Of The Menopause and*

Postmenopausal Years. Lancaster, UK, MTP Press, 1976

4. Thomas TM, Plymat KR, Blannin J, et al: Prevalence of urinary incontinence. *Br Med J* 1980;281:1243
5. Hesse U, von Obernitz N, Romisch M, et al: Erfolgreiches Beckenbodentraining bei Stressinkontinenten—Q Tip Test Ein Prognosefaktor? *Arch Obstet Gynaekol* 1993;254:506
6. Schussler B, von Obernitz N, Frimberger J, et al: Analysis of successful treatment of stress urinary incontinence by pelvic floor reeducation. A Urodynamic and radiological study. *Neurorol Urodyn* 1990;9:433
7. Hahn I, Sommar S, Fall M: A comparative study of pelvic floor training and electrical stimulation for the treatment of genuine female stress urinary incontinence. *Neurorol Urodyn* 1991;10:545
8. Hahn I, Naucier J, Sommar S, et al: Urodynamic assessment of pelvic floor training. *World J Urol* 1991;9:162
9. Little NA, Juma S, Raz S: Surgical treatment of stress incontinence. *Semin Urol* 1989;7:86
10. Kelly HA, Summ WM: Urinary incontinence in women without manifest injury to the bladder: A report of cases. *Surg Gynecol Obstet* 1914;18:444
11. Stanton SL, Hilton P, Norton C, et al: Clinical and urodynamic effects of anterior colporrhaphy and vaginal hysterectomy for prolapse with and without incontinence. *Br J Obstet Gynaecol* 1982;89(6):459
12. Stanton SL, Cardozo LD: A comparison of vaginal and suprapubic surgery in the correction of incontinence due to urethral sphincter incompetence. *Br J Urol* 1979;51(6):4975
13. Park GS, Miller EJ Jr: Surgical treatment of stress urinary incontinence: A comparison of the Kelly plication, Marshall-Marchetti-Krantz, and Pereyra procedures. *Obstet Gynecol* 1988;71:575
14. Schussler B: Operatives Vorgehen bei der Kombination aus Descensus vaginalis und Stressinkontinenz. *Gynaekol Rundsch* 1989;29(Suppl 2):19
15. Blaivas JG, Jacobs BZ: Pubovaginal fascial sling for the treatment of complicated stress urinary incontinence. *J Urol* 1991;145(6):1214
16. Hilton P: A clinical and urodynamic study comparing the Stamey bladder neck suspension and suburethral sling procedures in the treatment of genuine stress incontinence. *Br J Obstet Gynaecol* 1989;96(2):213
17. Summitt RL, Bent AE, Ostergard DR, et al: Suburethral sling procedure for genuine stress incontinence and low urethral closure pressure. A continued experience. *Int Urogynecol J* 1992;3:18
18. Marshall VF, Marchetti AA, Krantz KE: The correction of stress incontinence by simple vesicourethral suspension. *Surg Gynecol Obstet* 1949;88:509
19. Marshall AA, Marshall VF, O'Leary JF: Suprapubic vesicourethral suspension and urinary stress incontinence. *Clin Obstet Gynecol* 1963;6:195
20. Stanton SL, Cardozo LD: Results of the colposuspension operation for incontinence and prolapse. *Br J Obstet Gynaecol* 1979;86(9):693
21. Gillon G, Stanton SL: Long-term follow up of surgery for urinary incontinence in elderly women. *Br J Urol* 1984;56(5):478
22. Stanton SL, Hertogs K, Cox C, et al: Colposuspension operation for genuine stress: A five year study. Proceedings of the 12th Annual Meeting of the ICS, Leiden, Netherlands 1982:94
23. Cardozo LD, Stanton SL, William JE: Detrusor instability following surgery for genuine stress incontinence. *Br J Urol* 1979;51(3):204

continued on page 84

IF SKIN CANCER

HAD A POSTER CHILD,

SHE WOULD BE IT.



One in five Americans will develop skin cancer in their lifetime.

Don't let your teenager be the one.

Teach them to cover up and wear sunscreen when they go outside.



PREVENT SKIN CANCER

Funded under cooperative agreement U50/CCU511483-02, Centers for Disease Control and Prevention (CDC), U.S. Public Health Service

LAPAROSCOPIC COLPOSUSPENSION

24. Lose G, Jorgensen L, Mortensen SO, et al: Voiding difficulties after colposuspension. *Obstet Gynecol* 1987;69(1):33
25. Burch JC: Urethrovaginal fixation to Cooper's ligament for correction of stress incontinence, cystocele, and prolapse. *Am J Obstet Gynecol* 1961;81:281
26. Tanagho EA: Colpocystourethropey: The way we do it. *J Urol* 1976;116:751
27. Pereyra AJ: A simplified surgical procedure for the correction of stress incontinence in women. *West J Surg Obstet Gynecol* 1959;67:223
28. Pereyra AJ, Leberz TB: Combined urethrovesical suspension and vaginourethroplasty for correction of urinary stress incontinence. *Obstet Gynecol* 1967;30:357
29. Stamey TA: Endoscopic suspension of the vesical neck for urinary incontinence. *Surg Gynecol Obstet* 1973;136(4):547
30. Raz S: Modified bladder neck suspension for female stress incontinence. *Urology* 1981;17:82
31. von Obernitz N, Schussler B, Anthuber C, et al: Die vaginale Kolposuspension nach Raz—Indikation, Operationstechnik, Ergebnisse. *Arch Obstet Gynaekol* 1991;250:341
32. Hilton P, Mayne CJ: The Stamey endoscopic bladder neck suspension: A clinical and urodynamic investigation, including actuarial follow-up over four years. *Br J Obstet Gynaecol* 1991;98(11):1141
33. Mundy AR: A trial comparing the Stamey bladder neck suspension procedures with colposuspension for the treatment of stress urinary incontinence. *Br J Urol* 1983;33:687
34. Spencer JR, O'Connor VJ Jr, Schaeffer AJ: A comparison of endoscopic suspension of the vesical neck with suprapubic vesicourethropey for treatment of stress urinary incontinence. *J Urol* 1987;137(3):411
35. Vancaille TG, Schuessler W: Laparoscopic bladder-neck suspension. *J Laparoendosc Surg* 1991;(3):169
36. Alcala DM, Schuessler WW, Vancaille TG: Laparoscopic bladder suspension for the treatment of stress incontinence. *Semin Urol* 1992;10(4):222
37. Liu CY: Laparoscopic retropubic colposuspension (Burch procedure). *J Reprod Med* 1993;38:526
38. Nezhat CH, Nezhat F, Nezhat CR, et al: Laparoscopic retropubic cystourethropey. *J Am Assoc Gynecol Laparosc* 1994(4):339
39. Walters M, Shields L: The diagnostic value of history, physical examination and the Q-Tip cotton swab test in women with urinary incontinence. *Am J Obstet Gynecol* 1988;159:145
40. Bhatia NN, Bergman A: Use of preoperative uroflowmetry and simultaneous urethrocystometry for predicting risk of prolonged postoperative bladder drainage. *Urology* 1986;28:440
41. Hilton P, Stanton SL: A clinical and urodynamic assessment of the Burch colposuspension for genuine stress incontinence. *Br J Obstet Gynaecol* 1983;90:934
42. Nezhat CR, Nezhat F, Nezhat CH: Operative laparoscopy (Minimally invasive surgery): State of the art. *J Gynecol Surg* 1992;8:111
43. Nezhat CR, Nezhat FR, Luciano AA, et al (eds): *Operative Gynecologic Laparoscopy: Principles and Techniques*. New York, McGraw Hill, 1995 pp 255-262
44. Wiskind Ak, Creighton SM, Stanton SL: The incidence of genital prolapse after the Burch colposuspension. *Am J Obstet Gynecol* 1992;176:399
45. Rosenzweig BA, Hischke MD, Thomas S, et al: Stress incontinence in women: Psychological status before and after treatment. *J Reprod Med* 1991;36:835

Coming next month...

Assisted reproduction

For women over 40 plagued with infertility, consider oocyte donation as part of treatment.

Morcellation techniques

Vaginal hysterectomy means shorter hospital stay and recovery time. Morcellation often permits this approach for the enlarged uterus—especially when fibroids are involved.

Systemic lupus

Prognosis for a pregnancy affected with SLE depends in part on whether the disease is in remission or exacerbation at conception and during gestation.

Assessing fertility

The clomiphene citrate challenge and the gonadotropin agonist stimulation tests are new ways of screening for diminished ovarian reserve.

Pathology quiz

Try to diagnose cause of postmenopausal bleeding.

Look for these and other important articles in the October

**Contemporary
OB/GYN**