

A fresh look at ovarian endometriomas

By Farr Nezhat, MD, Ceana Nezhat, MD, Camran Nezhat, MD, and Dahlia Admon, MD

Endometriosis of the ovaries has unique manifestations. A new classification of endometriomas offers practical implications for diagnosis and treatment.

Endometriosis, a progressive, often debilitating disease that affects 10% to 15% of women during their reproductive years, accounts for 25% of all laparotomies performed by gynecologists.^{1,2} In frequency among gynecologic disorders it is surpassed only by leiomyomas.³

Endometriosis is also a major cause of infertility. Symptoms, including pain, nausea, vomiting, diarrhea, fatigue, and low-grade fever, can be severe.⁴

Adolescents not exempt

Once believed to be a disease of white, nulliparous, high-income women in their 40s, endometriosis is not limited by ethnic origin or economic means.⁵ It also affects teenagers, although previously

the disorder was discredited as a cause of pelvic pain in this group.⁶

First described by Russell in 1899, endometriosis was later studied extensively by Sampson.^{7,8} His definition, almost unchanged since 1921, characterizes it as ectopic tissue possessing the histologic structure and function of uterine mucosa and manifesting abnormal conditions that may result not only from its invasion of organs and other structures, but also from its relation to menstruation.

Recent more frequent documentation of endometriosis may be attributed to heightened awareness, better education in gynecologic pathology, and availability of laparoscopy, as well as apparent increased incidence. The number and rate of hysterectomies for endometriosis have increased steadily from the 1960s to the 1980s, more so than for other diagnoses. From 1965 to 1967 to 1982 to 1984 this rate more than doubled.⁹

Current explanations questioned

Many theories attempt to explain endometriosis, a hemorrhagic

fibrotic process that leads to formation of adhesions and small cysts (Table 1). Three are most accepted.⁶

■ **Direct implantation:** Endometrial cells are implanted directly by means of transtubal regur-

TABLE 1
Endometriosis histogenesis theories

- Activation of embryonic cell rests
- Activation of wolffian rests
- Direct implantation of endometrial cells
- Hematogenous spread
- Hereditary
- Immunologic
- Lymphatic dissemination
- Metaplasia of celomic epithelium
- Metaplasia of urothelium
- Transtubal regurgitation or retrograde menstruation

Dr. Farr Nezhat is clinical professor, Dr. Ceana Nezhat is assistant clinical professor, and Dr. Camran Nezhat is clinical professor of ob-gyn, Stanford University School of Medicine, Palo Alto, Calif., and Mercer University School of Medicine, Macon, Ga.

Dr. Admon is a staff member, department of ob-gyn, Sheba Medical Center, Tel Hashomer, Israel.

ST

menorrhoea
550 mg
400 mg
tea

ffects (ie,
etaminophen

gitation of menstrual blood and endometrial particles during menstruation, with subsequent growth in the pelvis.

■ **Celomic metaplasia:** Multipotential cells are stimulated to differentiate into endometriosis in any tissue with a celomic epithelium.

■ **Vascular and lymphatic dissemination:** Endometrial cells enter the uterine vasculature or lymphatic vessels at menstruation and are carried to distant sites.

Although the precise mechanism remains controversial, direct implantation appears to explain most cases.¹⁰ However, an exception appears to be ovarian endometriosis, distinguished by formation of cystic structures termed endometriomas or chocolate cysts.

Except when it affects the ovary, pelvic endometriosis is a self-limiting destructive disease forming nodules and fibrosis apparently secondary to a reaction to hemosiderin deposits. In severe cases, the cul-de-sac is often involved. At this site, the process appears self-contained, and lesions are usually small, with fibrotic reaction to hemosiderin causing nodularity and adhesions. Causes of the lesions are periodic tissue proliferation, local invasiveness, recurrent bleeding, and a tendency towards fibrosis, cicatrization, and constriction.

In contrast, ovarian endometriosis causes adhesion formation between the ovarian surface and

broad ligament, and the ovary enlarges as large cystic structures filled with chocolate fluid are formed. These large cysts—endometriomas—are not found at other sites in the pelvis.

Physiology may help account for the distinctive presentation. First, the ovary contains high concentrations of ovarian steroids and growth factors, which may influence initiation, maintenance, and growth of endometrial implants. Second, the ovarian surface is regularly interrupted by follicular rupture at ovulation. Third, functional ovarian cysts may form, which tend to be self-limiting but may temporarily alter the ovary's functional and structural integrity.

Accepted theories for formation of endometriosis fail to explain why large cystic structures are formed primarily in the ovary. Moreover, ovarian findings considered typical of endometriosis often have no histologic characteristics suggesting endometrial origin. Although this absence could result from destruction of the cysts' endometrial lining, it does not explain restriction of these findings to the ovary.

Past investigations

The exact process of endometrioma development has not been determined. However, several attempts have been made to account for endometriomas. In 1921, Sampson first noted that histologic findings in chocolate cysts vary in different portions of

the same cyst, observing that both luteal membrane and ovarian epithelial tissues are frequently present.⁸ He believed that in addition to local spread of endometriosis by salpingeal reflux, some foci may develop from implantation of endometrioma contents after rupture. He further suggested that endometriomas may result from invasion of functional cysts by surface implants.

In 1979, Chernobilsky and Morris reported various epithelial characteristics in ovarian endometriosis.¹¹ Since these features frequently included endometrial and oviductlike epithelium, they concluded that ovarian tissue may be a common histologic precursor.

Nissolle-Pochet and co-workers studied microscopic characteristics of 113 cases of ovarian endometriosis before and after hormonal therapy and identified typical endometrial glandular epithelium and stroma.¹² In 18% of the women, the epithelium consisted of cyst lining only, and the remainder had both flattened endometrial epithelium and typical glandular and stromal structures. Also, areas with ciliated cells representing oviductlike epithelium were noted in 47%.

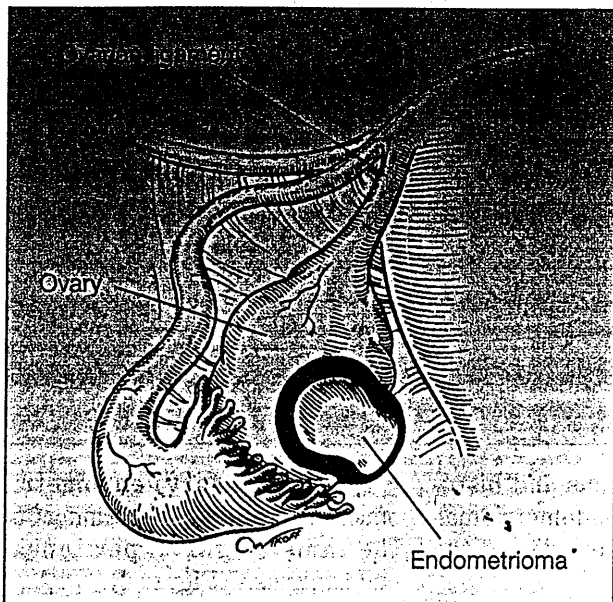
Martin and Berry examined 41 chocolate cysts and found that 61% were microscopically confirmed endometriomas, 27% corpora lutea, and 12% without lining.¹³ Vercellini and co-workers evaluated the accuracy of visual diagnosis of endometriomas and

...
he
afe
nit

such
OUR
NER
lette

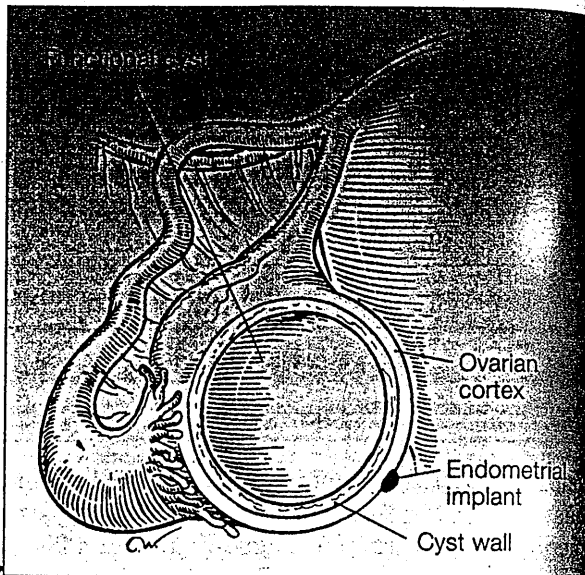
as wel
ed follo
e adacen
is a regis

FIGURE 1
Type I endometrioma



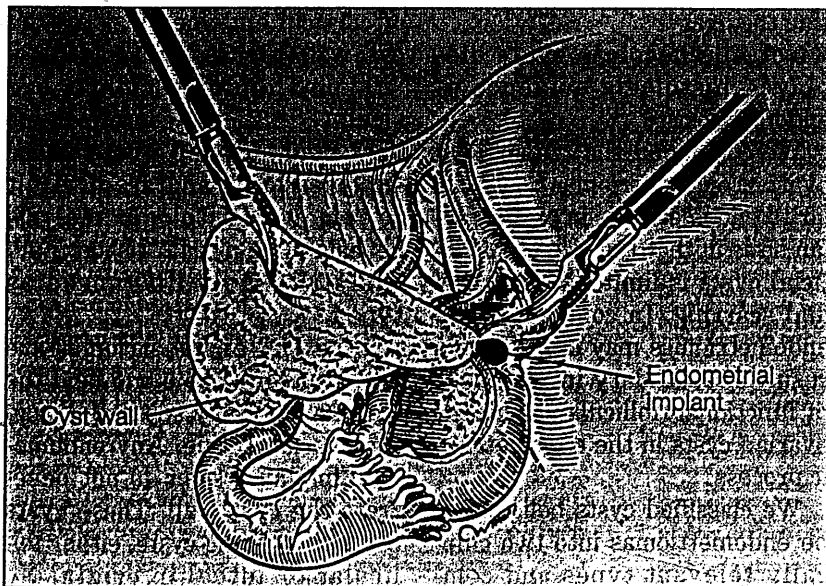
This endometrioma is small (1 to 2 cm), contains thick, dark fluid, and develops from surface endometriosis.

FIGURE 2
Type IIA endometrioma



This endometrial implant on the ovarian cortex has no attachment on the cyst wall. It is usually large, and the wall is easily separated from the ovarian tissue.

FIGURE 3
Type IIB endometrioma



The cortical endometrial implant has reached the cyst wall and is firmly attached.

metriomas with features of functional cysts involved deeply with surface endometriosis, as supported by histologic findings of endometriosis implants in the cyst wall. Both types contain thick, dark brown fluid.

In type IIB, the lining separates easily from the ovarian capsule and stroma, except adjacent to areas of endometriosis, where the ovarian capsule adheres to the cyst wall. In type IIC, surface endometrial implants are present, penetrating deep into the cyst wall and spreading to at least one area of the wall.

Thus, progression of cyst wall "invasion" differentiates IIB and IIC endometriomas and is characterized by progressive difficulty in removing the cyst wall. These findings can explain

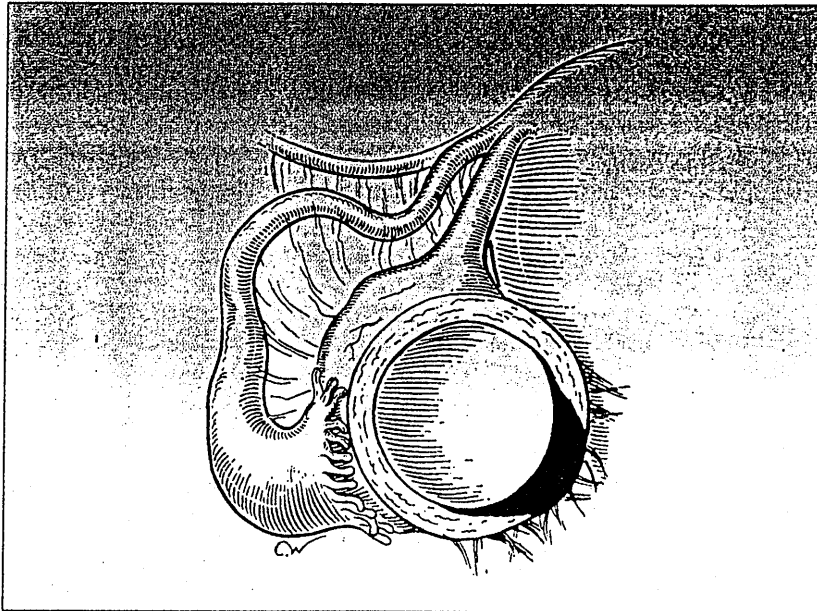
Why I helped a man become a woman
Medicare payments: new for 1995

medicare



How cooks with health

FIGURE 4
Type IIC endometrioma



The surface endometrial implant has penetrated deep into the cyst wall and is spreading. The cyst is attached to the pelvic sidewall with dense adhesions.

the discrepancy found in other studies.

Management implications

Medical management of endometriomas has proved ineffective, and surgical therapy is the accepted approach. Ovarian suppression may have therapeutic value when used preoperatively. As suggested by Buttram in evaluating danazol (Danocrine; 3 months at 800 mg daily), it may reduce vascularity and decrease intraoperative hemorrhage.²⁰ Moreover, it may shrink or resolve many follicular cysts and corpora lutea, decreasing manipulation and minimizing damage to normal ovarian tissue.

Different degrees of surgical intervention have been described.^{14,16,21} The simplest, least

invasive approach involves fenestration and removal of chocolate-colored fluid without further cystectomy or cyst wall ablation. In 1988, we compared simple aspiration of endometriomas with copious irrigation of the cyst cavity and complete cyst wall removal.²¹ Fenestration and irrigation were associated with a 50% endometrioma recurrence rate, compared with 8% for capsule removal.

Fayez and co-workers created a wide opening in the cyst wall to completely drain its contents.¹⁶ This technique created fewer periadnexal adhesions (27%) than either complete resection of endometrioma (100%), stripping the lining (37%), or lining vaporization by continuous CO₂ laser (30%). Persistence of endometriomas was much higher when the

cyst wall was not removed. All recurrent endometriomas were larger than 4 cm.

Vercellini and co-workers found that simple aspiration of endometriomas and washing of the capsule are not therapeutic.¹⁴ In 33 women, most endometriomas recurred, although many patients took gonadotropin-releasing hormone (GnRH) analogs postoperatively. Additionally, Hasson found no therapeutic value for simple aspiration and noted recurrence in eight of nine endometriomas treated by fenestration alone.²²

Our experience was similar. Therefore, we believe aspiration alone is unacceptable for any endometrioma and recommend surgery based on clinically diagnosed type. Although small type I endometriomas are difficult to remove intact because of associated fibrosis and adhesions, they can be biopsied, drained, and vaporized using laser or electro-surgery or removed in pieces. Larger type I lesions (2 to 3 cm) must be completely removed.

Type IIA lesions (follicular and luteal cysts) should resolve with or without preoperative ovarian suppression or expectant management. Patients with persistent cysts may undergo laparoscopy for lysis of periovarian adhesions and evaluation of the ovarian cortex. Then the surgeon aspirates and deflates the cyst, vaporizes or excises any superficial ovarian cortex endometriosis, and opens the cyst and evaluates its interior for signs of malignancy.

The surgeon can usually diag-

TABLE 2
Characteristics of presumed endometriosis

Type	No.	Size (mean)	Luteal lining	Endometrial lining	No diagnostic lining	Adhesions dense/filmy	Hemosiderin and/or fibrosis
I	15	1-2 cm (1.67)	0	15	0	5/3	15
II	57	2-6 cm (3.9)	46	0	9	5/11	6
III	46	3-12 cm (5.4)	14	23	9	22/13	35
IV	98	3-20 cm (7.0)	10	84	4	88/2	88

confirmed 97.7%.¹⁴ They used at least two of the following four microscopic patterns for diagnosis: endometrial epithelium, endometrial glands or gland-like structures, endometrial stroma, and hemosiderin-laden macrophages. These criteria were somewhat liberal, as accepted histologic criteria include only endometrial glands and stroma.¹⁵

Fayez and Vogel, however, noted that none of 66 endometriomas in 50 patients had an endometrial lining.¹⁶ Such observations could be explained by inadequate sampling of the cyst walls for histologic diagnosis. An alternative theory for development of endometriomas is that deep ovarian endometrial lesions could originate from metaplasia of celomic epithelium lining the cystic epithelial inclusions frequently found in the ovaries.^{17,18}

Authors' results

Believing that no theory completely explains the origin of endometriomas, we further studied endometrioma formation.

Clinical observations and histologic analysis of endometriomas in over 1,000 women yielded the following findings:

- The ovary was involved in approximately half of all women with endometriosis.
- The ovary may have superficial implants.
- Development of large endometriomas was most unusual outside the ovary.
- Not all chocolate cysts displayed histologic evidence of endometriosis.

We concluded that superficial ovarian endometriomas are similar to endometriosis in extraovarian sites in that the size of superficial cysts is limited by fibrosis and scarring. In contrast, large endometriomas may develop as a result of secondary involvement of functional (follicular or luteal) ovarian cysts in the endometriotic process.

We classified cysts believed to be endometriomas into two clinically relevant types and compared them with histologic findings (Table 2).¹⁹ The following simplified version evolved:

■ Type I (primary) endometriomas are true endometriomas of the same origin as peritoneal endometriosis (Figure 1).

■ Type II (secondary) endometriomas are follicular or luteal cysts involved with, or invaded by, cortical endometriosis implants, or primary endometrioma. Three subclasses, IIA, IIB, and IIC, are distinguished by the relationship of cortical endometriosis to the cyst wall (Figures 2 through 4).

Type I endometriomas are small (1 to 2 cm), contain thick, dark fluid, develop from surface endometriosis, and are difficult to remove. Histologic analysis reveals endometrial tissue in all cysts clinically diagnosed as type I.

Type IIA endometriomas are usually large (2 to 6 cm), and the cyst wall is easily separated from the ovarian tissue. Any endometrial implants seen do not penetrate the cyst wall. These cysts are hemorrhagic cysts, either follicular or luteal in origin. No walls have evidence of endometrial tissue.

Types IIB and IIC are endo-

pose the functional nature of the cyst by its yellowish appearance and ease of removal. A frozen-section biopsy sample is taken to confirm a functional cyst and rule out malignancy. However, any question regarding clinical diagnosis should lead to complete removal of the cyst with the least amount of trauma to the ovary. Postoperatively, hormonal suppressive therapy (800 mg of danazol daily or GnRH analog) is used for 6 to 8 weeks to promote ovarian healing.

Types IIB and IIC are usually larger and associated with more periovarian adhesions. They may be firmly attached to the pelvic sidewall and back of the uterus and will rupture during separation. After dissecting the ovary from the pelvic sidewall, the operator removes cyst contents with a suction-irrigator probe and copiously irrigates the cyst cavity. Any spillage is immediately suctioned and irrigated.

For a type IIB endometrioma an opening is made, contents thoroughly aspirated with a suction-irrigator probe, and the inside evaluated for vegetation or excrescences signaling malignancy. That portion of ovarian cortex involved with endometriosis is removed. Then, using grasping forceps and the suction-irrigator probe, the surgeon grasps the cyst wall and separates it from the ovarian stroma by traction and countertraction.¹⁹ Hydrodissection aids complete removal.^{23,24} Small blood vessels from the ovarian bed and major

bleeding from the ovarian hilum are controlled by bipolar electrodesiccation.

In type IIC, the ovarian cortex is strongly attached to the cyst wall, making it difficult to develop a plane between the wall and ovarian capsule. The surgeon removes the attached portion of the ovary until an area is found to develop a plane and thereafter proceeds as with type IIB.

The redundant ovarian capsule is approximated by laser or electrocautery to avoid excessive adhesion formation by suturing. If necessary, 4-0 polydioxanone (PDS, Ethicon) sutures are placed inside the capsule. Fewer sutures will probably result in fewer adhesions.²⁵

Low-power continuous CO₂ laser or bipolar coagulation can be applied to the inside wall of the redundant ovarian capsule, causing the capsule to invert. Care is needed to avoid excessive coagulation of adjacent ovarian stroma.

Theory backed

Several observations support our view that ovarian endometriosis is (1) similar to that in extraovarian sites, with the size of superficial cysts limited by fibrosis and scarring, or (2) due to involvement of functional ovarian cysts by the endometriotic process. First, large endometriomas (more than 2 to 3 cm) are rarely found in the pelvic cavity except in the ovaries or in women receiving hormonal suppressive therapy preventing ovulation. The cysts

frequently form in women taking ovarian stimulation medication, such as clomiphene citrate (Clomid) and gonadotrophins (Pergonal). Second, luteal and endometrial lining are found in different areas of large chocolate cysts. In our series, we were able to demonstrate the following: photomicrographs showing endometriotic tissue apparently encroaching on luteal cells, as well as a follicular cyst extending into an endometrial cyst.¹⁹

Martin and Berry observed that 27% of clinically apparent endometriomas proved on histologic examination to be hemorrhagic luteal cysts.¹³ Similarly, we found that 32% of presumed endometriomas were later histologically confirmed to be corpora lutea. However, Martin and Berry did not report any mixed-cellular types, possibly because serial sections were not done. Finally, our conclusions are supported by Sampson, who 70 years ago noted that deeper portions of chocolate cysts were usually lined by luteal membrane that appeared to have retrogressed in response to an invasion of epithelium.⁸

Potential benefit

Our proposed classification allows the surgeon to classify the cyst before histologic diagnosis, differentiating it according to size, contents, ease of capsule removal, adhesions to other structures, and location of superficial endometriosis implants relative to the cyst wall. Diagnosing and treating endometrioma at earlier stages in

Recommend REALITY® FEMALE CONDOM

LISTED BY THE CDC* AS AN OPTION TO HELP
PREVENT STDs, INCLUDING AIDS, AND PREGNANCY

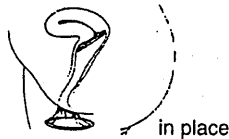
Leading Public Health Advocate's comments on REALITY

"Women who ask their partners to use a male condom sometimes risk...the threat of their partners leaving. Worse, women have been literally dying for lack of access to the type of protection provided by the female condom as a viable alternative when their partners refuse to wear a male condom."

Erica Gollub, Dr. P.H., Epidemiologist and Researcher in Women's Health

Reality female condom

- Made of polyurethane
- Rarely rips or tears
- Transfers heat; thin and comfortable
- She can insert it ahead of time



Candidates for Reality

Sexually active women at risk of STDs and pregnancy, whose partners don't wear male latex condoms

- with multiple partners
- in serial monogamous relationships
- who want a barrier method of contraception
- who are allergic to latex

Laboratory testing showed that Reality was an effective barrier to HIV and also to a virus particle (φX174) which is smaller than the Hepatitis B virus[†], the smallest virus known to cause an STD.

CLINICAL EXPERIENCE

Contraception:

	TYPICAL USE FAILURE RATES	
	6 months (%)	1 YEAR (%) ¹
REALITY Female Condom ⁴	12	25
Male Latex Condom ⁵	8	15
Cervical Cap ⁴	10	18
Diaphragm ⁴	8	15
Sponge ⁴	12	17
Unprotected Sex ⁶	61	85

PERFECT USE FAILURE RATES

REALITY Female Condom ^{2,4,6}	2.6%	5%
--	------	----

STD Prevention:

TRICHOMONAS REINFECTION RATES IN A 45-DAY STUDY^{1,6,8}

	REALITY Users		Controls (n=50)
	Compliant (n=20)	Noncompliant (n=34)	
Percent reinfected	0	14.7	14

Acceptability:

Most men and women, participating in clinical trials, found using REALITY to be an acceptable method of protection against STDs and pregnancy.^{2,3}

Users comment on Reality

"The first time my partner and I used the female condom, we laughed. But after I used it a couple of times, it was 1-2-3...no problem."

Estelle N., Graduate Student/Artist

"Once I got over the way it looks, I was comfortable. It's the contraceptive for me."

Donna H., Nurse's Assistant

Important information

- Latex condoms for men are highly effective at preventing sexually transmitted diseases, including AIDS (HIV infection), if used properly
- If the partner is not going to use a male condom, REALITY can be used by the female partner to protect both partners
- REALITY only works when it is used with each act of intercourse
- Before using REALITY, patients should be instructed to read the directions and learn how to use it properly

* Centers for Disease Control

¹ Yearly typical use failure rates for REALITY were estimated by doubling the 6-month pregnancy rate. Pregnancy rates for REALITY, Cervical Cap, Diaphragm and Sponge are from clinical trials. Actual use failure rates may be higher or lower.

⁴ 45-day clinical trial of 104 sexually active women with vaginal trichomoniasis, who were successfully treated with metronidazole.

⁶ The difference was not statistically significant (α=0.05).

For references and additional information about REALITY,
call 1-800-635-0844.

REALITY®
FEMALE CONDOM
Make It Her Reality

The Female Health Company, division of Wisconsin Pharmacal
875 North Michigan Avenue, Suite 3660 Chicago, IL 60611

ENDOMETRIOMAS

younger women may help reduce
adverse impact on health, quality
of life, and fertility. □

REFERENCES

- Hasson HM: Incidence of endometriosis in diagnostic laparoscopy. *J Reprod Med* 1976;16:135
- Schmidt LC: Endometriosis: A reappraisal pathogenesis and treatment. *Fertil Steril* 1985;44:15
- Williams TJ, Pratt JHL: Endometriosis: celiotomies: incidence and management. *Am J Obstet Gynecol* 1977;129:245
- Nezhat C, Nezhat F, Nezhat C: Operative laparoscopy (minimally invasive surgery): State of the art. *J Gynecol Surg* 1992;8:111
- Speroff L, Glass RH, Kase NG: Endometriosis and infertility, in: *Clinical Gynecologic Endocrinology and Infertility*, 3rd ed, Baltimore, Williams & Wilkins, 1988, p 494
- Wentz AC: Endometriosis, in Novak E, Jones HW, Wentz AC, et al (eds): *Novak's Textbook of Gynecology*, 11th ed. Baltimore, Williams & Wilkins, 1988, pp 303-32
- Russel WW: Aberrant portion of Mullerian duct found in ovary. *Johns Hopkins Hosp Bull* 1959;10:8
- Sampson JA: Perforating hemorrhagic (chocolate) cysts of the ovary. *Arch Surg* 1921;3:245
- Pokras R, Hufnagel VG: Hysterectomy in the United States, 1965-84. *Am J Public Health* 1988;78:852
- Metzger DA, Haney AF: Etiology of endometriosis. *Obstet Gynecol Clin North Am* 1989;16:1
- Chernobilsky B, Morris WJ: A historic study of ovarian endometriosis with emphasis on hyperplastic and atypical changes. *Obstet Gynecol* 1979;53:318
- Nissolle-Pochet M, Casanas-Roux F, Donnez J: Histologic study of ovarian endometriosis after hormonal therapy. *Fertil Steril* 1988;49:423
- Martin DC, Berry JD: Histology of chocolate cyst. *J Gynecol Surg* 1990;6:43
- Vercellini P, Vendola N, Bocciarelli L, et al: Reliability of the visual diagnosis of ovarian endometriosis. *Fertil Steril* 1991;56:1198
- Sternberg SS: *Histology for Pathologists*. New York, Raven Press, 1992
- Fayez JA, Vogel MF: Comparison of different treatment methods of endometriomas by laparoscopy. *Obstet Gynecol* 1991;78:660
- Blaustein A, Kantius M, Kaganowicz A, et al: Inclusions in ovaries of females aged 1-30 years. *Int J Gynecol Pathol* 1982;1:145
- Kerner H, Gatton E, Chernobilsky B: Unusual ovarian, tubal and pelvic mesothelial inclusions in patients with endometriosis. *Histopathology* 1981;5:277
- Nezhat F, Nezhat C, Allan CJ, et al: A clinical and histologic classification of endometriomas: Implications for a mechanism of pathogenesis. *J Reprod Med* 1992;37:771
- Buttram VC: Use of danazol in conservatively treated endometriomas. *J Reprod Med* 1990;35:82
- Nezhat C, Nezhat F: Comparison of different treatment methods of endometriomas by laparoscopy. *Obstet Gynecol* 1992;79:315
- Hasson HM: Laparoscopic management of ovarian cysts. *J Reprod Med* 1990;25:863
- Nezhat C, Silfen SL, Nezhat F, et al: Surgery for endometriosis. *Curr Opin Obstet Gynecol* 1991;3:30
- Nezhat C, Nezhat F: Safe laser excision or vaporization of peritoneal endometriosis. *Fertil Steril* 1989;52:149
- Nezhat C, Nezhat F: Postoperative adhesion formation after ovarian cystectomy with and without ovarian reconstruction. Presented at the 75th Annual Meeting of the American Fertility Society, Orlando, Fla, Oct 19-24, 1991

...THE FIRST
TRULY
INTEGRATED
MATERNAL
AND FETAL
MONITORING
SYSTEM IS
HERE!

The new Model 118
features external and
internal fetal heart rate
and uterine activity -
and now adds
maternal vital signs:
noninvasive blood
pressure and SpO₂!
This next generation of
obstetrical care
instrumentation reduces
the complexity, size,
weight and cost of the
multiple products
previously needed.
The new Model 118 -
another innovation
from Corometrics,
providing information
and documentation
needed for complete
maternal/fetal care.

FOR MORE INFORMATION

800-243-

Ext. 465

or more information

COROMETRICS ME